MOLECULAR AND BIOLOGICAL STUDIES IN GALLBLADDER CANCER

胆嚢がんに関する分子生物学的研究

2004

筑波大学大学院人間総合科学研究科

Mila GHOSH

筑波大学

博士　（医学）学位論文

胆嚢がんに関する分子生物学的研究

背景と目的：

胆嚢がんには特有の早期症状が無く、診断技術の進歩した今日でも早期発見は困難で、多くの患者は進行期になって初めて診断されている。この為、胆嚢がんの予後は極めて不良であり、早期診断法の開発や有効な治療法の確立が希求されている。日常の診療においては、約 80%以上の胆嚢癌患者は既に III~IV 期の進行期にあり、根治切除が行われる症例少ない。また、根治切除が可能であった症例でも、術後早期に再発・転移を生じ易く、予後は極めて不良である。さらに、胆嚢癌は抗癌剤や放射線に抵抗性で、今日でも有効な補助療法は開発されていない。

一方、胆嚢癌は胃癌や大腸癌などと比較して、発生率で約 7〜8 分の 1 と少ない上に、切除症例が少なく、利用可能な培養細胞樹立株は少数である。この様な背景から、胆のう癌の発生や進展に関する分子生物学的理解が未だ不十分であり、胆のう癌に対する分子標的化学療法の開発や有効な化学療法レジメの開発なども他の領域の癌に比べて立ち遅れている。

今回、大腸癌や胃癌などのの発生や進展に関与している事が報告されている COX 2 (Cyclooxygenase ; a rate-limiting enzyme that catalyzes the formation of prostaglandins from arachidonic acid) と MUC1 () 分子に注目し、それらの胆のう組織における発現を正常、慢性炎症、癌のそれぞれで比較検討し、癌の進行度との関連性を検討した。

また、胆のう癌に関する生物学的特徴の理解を進め、胆のう癌に特異的な遺伝子変化を探り、有効な化学療法の開発にも繋がる研究を行う事を目的として、新鮮切除標本から胆のう癌細胞の継代培養株を樹立した。

最近発見された新しい細胞増殖制御タンパクである Mortalin (熱ショックタンパク 70 (hsp70)ファミリーの一員) の胆のう癌樹立細胞株における発現を検討した。

Dedicated
To
my father
MKDatta

ABSTRACT

MOLECULAR AND BIOLOGICAL STUDIES IN GALLBLADDER CANCER

BACKGROUND AND AIM

Gallbladder cancer has a dismal prognosis. Understanding of the disease at the biological, genetic, molecular level and also establishment of tools for further research are essential for effective diagnostics and therapeutics. Molecules related with carcinogenesis and tumours spreading investigated in other cancers are important to check in gallbladder cancer. At the same time establishment of gallbladder cancer cell lines for further study and use for research tool is important. Identifying the amplified and deleted genetic region is also important for targeting the oncogenes and cancer suppressor genes.

The aim of this work is to study gallbladder cancer from molecular level:

- To investigate COX whether it has any role in gallbladder carcinogenesis and cancer progression. Cyclooxygenase (COX) is a rate-limiting enzyme that catalyzes the formation of prostaglandins from arachidonic acid. Two isoforms of COX have been identified. COX1 is constitutively expressed in most tissues and appears to play a role in normal physiology (e.g.; cytoprotection of the stomach, platelet aggregation, and renal blood flow. COX2 is an inducible gene and has other functions in addition to inflammatory reactions. Numerous studies suggest that the regular use of non-steroid anti-inflammatory drugs (NSAIDs) reduce the risk of colorectal adenoma and cancer. As cyclooxygenase (COX) is the major target for NSAIDs action and in colorectal and other gastrointestinal cancer it is seen that COX may be involved in the initiation, cell proliferation, carcinogenesis and progression of tumors.
- To investigate MUC1, whether it has any role in gallbladder carcinogenesis and cancer progression. MUC1 (DF3) gene encodes a high molecular mass glycoprotein that is aberrantly expressed by malignant mammary epithelium. This antigen is expressed on the apical borders of secretory mammary epithelial cells and at high levels in the cytosol of less differentiated malignant cells. Different studies demonstrated that this family of glycoprotein regulates immune recognition and cellular adhesion. Several reports demonstrated that MUC1 expression is strongly related to tumor progression within gastrointestinal cancers.

- Establishment of gallbladder cancer cell lines
    a. Characterize them to understand the tumour biology
    b. Genetic analysis to target any oncogene and tumour suppressor gene.
    c. Tools for further study and research with the ultimate goal of developing of an effective chemotherapy.
- To investigate Mortalin (a new protein) expression in gallbladder cancer cell lines. Mortalin is a member of heat shock protein 70 (hsp70) family of proteins. It is differentially distributed in normal and cancerous cells. Mortalin is reported to be involved in control of cell proliferation, differentiation and tumorigenesis. Mortalin is also shown to cause inactivation of tumor suppressor protein p53.

MATERIALS AND METHODS

1) In the tissue level: Specimens consisting of gallbladder cancer, chronic cholecystitis, Xanthogranulomatous cholecystitis and the normal gallbladder were collected by surgical resections from India and Japan. Immunohistochemical staining was performed:

a) For COX expression: polyclonal antibodies, goat antihuman COX1 IgG (Santa Cruz Biotechnology, California) and rabbit antihuman COX2 IgG (IBL, Gunma, Japan)

b) For MUC-1 expression: Primary antibodies against MUC1 (monoclonal antibody, mouse anti-human CA 15-3, clone DF3 (IgG1, DAKO corporation).

2) In the cell level

a) Establishment and characterizations of gallbladder cancer cell lines: We established 5 cell lines of gallbladder cancer from surgically resected specimens. We examined growth characteristics and the colony-forming ability of established cell lines in terms of their cell cycle parameters, expression of tumor markers (carcinoembryonic antigen; CEA, carbohydrated antigen 19-9; CA19-9, MUC-1 and c-kit) and oncogenes c-erbB2 by flow cytometer. Comparative genomic hybridization (CGH) analysis with specific gene probes was performed to detect changes in the gene copy numbers in both gallbladder cancer cell lines.

b) Mortalin expression in the cell lines: We checked the mortalin expression in our 5 cell lines and other 2 cell lines of gallbladder cancer by immunocytochemistry with anti mortalin antibody. We have checked the mortalin expression in TGBC1, TGBC2. TGBC24, TGBC44, and

Mz-Cha1 cell lines by western blot. We checked the Mortalin expression in relation with cell cycle by double immunostaining of cells with Mortalin and PI in 6 gallbladder cell lines and analysed the result in laser scanning cytometry (Olympus LSC 2) camera. We again check the Mortalin expression in different phases of the cell cycle of TGBC2 cell line by western blot.

RESULTS

COX study: COX1 was homogeniously expressed in all cells. In the normal gallbladder, the COX2 expression rate was significantly higher in the epithelium than in the stroma. It was significantly lower in the non-cancerous epithelium adjacent to cancerous lesion than of cancer, chronic cholecystitis, XGC and normal gallbladder. Regarding to the expression in the stroma, the COX2 expression rates were significantly higher in cancer, chronic cholecystitis, XGC and than that of the normal gallbladder. Furthermore, the rate in non-cancerous adjacent stroma to cancer is significantly lower than that of cancer and XGC but difference with normal and of chronic cholecystitis was not significant. The COX2 expression rates were significantly higher in both the epithelium and the stroma in well and moderately differentiated cancer group than in poorly and undifferentiated cancer group.

MUC1 study: MUC1 core protein expression is significantly high ($p<0.0001$) in gallbladder cancer (69/88, 78.4%), while, very trace in normal and inflammatory tissues. The expression rate is significantly lower ($p<0.0001$) when cancer did not penetrate the muscle layer than when cancers did penetrate the layer. The MUC1 core protein expression rate was 29% (4/14) in T1 tumors, while it was ranged from 79% to 93 % in the advanced T categories: 79% (11/14) in T4, 89% (40/45) in T3, and 93% (14/15) in T2, respectively. The polarized and depolarized staining patterns of MUC1 expression were recognized. Every cell of normal, inflammatory epithelia, including 8 xanthogranulomatous cholecystitis and T1 cancers had the polarized pattern. The depolarized pattern was dominant in cancer cells from the advanced categories T2, T3 and T4. That is, 60% (45/74) of cancer cells from the epithelial layer and 78 % (58/74) of penetrating cancer cells from deeper layers had the depolarized pattern. There was no significant correlation of MUC1 expression rate and staining pattern with cancer differentiation and microscopic venous invasion. On the other hand, lymphatic vessel invasion was significantly correlated with MUC1 staining pattern but not with expression rate.

Cell lines establishment: Human origin of cell lines was confirmed by chromosomal analysis. The doubling time of different cell lines varied from 30 to 96 hours. All 5-cell lines formed colonies in the colony forming assays and expressed CEA, CA19-9, MUC-1 and oncogene c-erbB2 and showed chromosomal aneuploidy. CGH analysis of gallbladder cell lines demonstrated gain of chromosomal region bearing SRC, RAB1, and PAP in 5 cell lines and hTERT in 4 cell lines of gallbladder cancer.

Mortalin expression: Our gallbladder cancer cell lines TGBC1, TGBC2, TGBC14, TGBC24, TGBC44, and also Mz-cha1, Mz-Cha2 expressed mortalin in their perinuclear fashion. Mortalin expression in comparison with TIG1 normal fibroblast cell line is high in TGBC1, TGBC24, and TGBC44, moderately high in TGBC2 and Mz-Cha1. In laser scanning cytometry mortalin was present in each phase of the cell cycle in TGBC1, TGBC2, TGBC24, TGBC44, Mz-Cha1 and Mz-Cha2, cell lines. By western blot experiment in TGBC2 cell line Mortalin was present in each phase of the cell cycle.

DISCUSSIONS

COX Study: The exact reason for the difference in normal, inflammatory and cancer gallbladder is not known at present, however, high expression of COX2 in the epithelium of normal gallbladder as well as inflammatory tissues can be explained by the presence of bile because bile acids activate the transcription of COX2. In the stroma of normal gallbladder COX2 expression might be repressed by the intact basement membrane. Since the basement membrane in cancerous and inflammatory tissues is lacking in part or damaged, bile may reach the stroma through the barrier to induce COX2 and responsible for high COX2 expression in stroma of inflammatory and cancer tissues. Abundant inflammatory cells infiltrating in cancerous and inflammatory tissues produce various kinds of cytokines to induce COX2.

Poorly differentiated carcinoma is more invasive with a very high metastatic potential and COX2 expression is positively correlated to metastatic potential. Contrarily, we found that the incidence of COX2 expression in well and moderately differentiated carcinoma were significantly higher than those in poorly differentiated carcinoma of the gallbladder. It cannot be claimed that COX2 expression might involve in the initiation of carcinogenesis because of our

findings of high incidence of COX2 expression in normal and inflammatory gallbladder conditions do not support the above hypothesis at least in gallbladder carcinogenesis.

MUC1 Study: MUC1 core protein expression rate is significantly higher in cancer cells than in non-cancerous cells. Mechanism has been studied in colon cancer, may be similar mechanism of high expression of MUC1 may occur in gallbladder cancer. It has been observed that the activity of GalNAc transferases is increased in cancer, specifically within the rough endoplasmic reticulum (RER). O-glycosyltion usually occurs in golgibodies of normal cell, but in cancer cells it occurred in the swollen RER in spite of golgibodies. Swelling of the RER may be responsible for cellular stress and neoplastic transformation. In colon cancer that in typical cancers golgi stacks are not observed, probably due to the lack of polarization of the cells and the fact that mucus droplets are also distributed in a non-polarized fashion. This lack of polarization of the cells may be responsible for the depolarised expression of MUC1 noted in gallbladder cancer. In our study MUC1 expression is significantly lower in T1 than in advanced tumors (T2, T3, and T4). Depolarized staining pattern was significantly related with lymphatic vessel invasion however; microscopic venous invasion had no significant relation to MUC1 expression rate and expression pattern in gallbladder cancer. Based on these results we advocate hypothesis that MUC1 is related with lymphatic vessel invasion, but not with venous invasion in advanced gallbladder cancer. More over from this study and also our COX2 study we concluded that Xanthogranulomatous cholecystitis is not a pre cancerous condition.

Cell line Establishment: Different profiles of chromosomal copy-number abnormalities have been revealed in our gallbladder cancer cell lines. Especially, there are the possibilities of the existence of oncogenes related with the development of gallbladder cancer in those regions of chromosomal amplifications.5P (hTERT region) amplified in 2 and gained in 2 gallbladder cancer cell line. 17q (c-erbb2 region) amplified in 2 and gained in one gallbladder cancer cell line. In gallbladder cancer cell lines 6P (VEGF, TNFa region) gained in 2 and amplified in one, 7P(EGFR region) gained in 4, 7q (Met region) gained in 4, 8q(cMYC) amplified in 2 and gained in one and 4 cell lines gained in 20p(PCNA). These results indicate biological behavior of the gallbladder cancer is influenced by these growth factors and oncogene. Reports are there that EGFR is activated by bile acids and functions to induce COX2 expression by an MAPK (mitogen

activated protein kinase pathway) cascade. Growth factors like HGF, Met, VEGF, and TNFA are known to have proliferative effects on biliary epithelial cells. Met is in actual fact frequently over- expressed in proliferative biliary epithelial cells, suggesting that HGF/met may play an important role in biliary hyperplasia. K-ras region gained in 4 out of 5 gallbladder cancer cell lines. 17p region bearing p53 regions gained in 3 gallbladder cancer cell lines. 18q (region of DPC4) is lost in TGBC14 but gained in TGBC2. 20q gained in all 5 gallbladder cancer cell lines. Moreover, our well-characterised cell lines will be an ideal tool for studying the tumor biology and further research of gallbladder cancer.

Mortalin Expression: Mortalin is expressed in our cell line like other cancer cells in perinuclear fashion. In western blot experiment Mortalin expression is higher in gallbladder the cell lines than normal fibroblast. But Mortalin expression is not changed in cell cycle. May be Mortalin expression is regulated by some other mechanisms.

CONCLUSIONS

Our studies are:

- The first reports regarding COX2 and MUC1 expression in gallbladder cancer in comparison with normal and inflammations.
- Our study revealed that COX2 expression in the gallbladder may be regulated by various factors and not directly related to carcinogenesis.
- MUC1 expression was significantly higher in gallbladder cancer cells than in normal and inflammatory gallbladder cells. In cancer cells, the depolarized staining pattern was dominant, while in non-cancerous tissues the polarized pattern was dominant. Lymphatic vessel invasion is significantly related with depolarised expression.
- Our newly established cell lines might serve as a useful model for studying the molecular pathogenesis and testing of new therapeutics against gallbladder cancer. These chromosomal aberrations and imbalances provide a starting point for molecular analyses of genomic regions and genes in gallbladder carcinogenesis.
- Our cell lines expressed Mortalin in a perinuclear fashion. Expression is not related with the origin of the cells. Mortalin expression is high in the gallbladder cancer cell lines. And it is not regulated by the cell cycle but may be by some other mechanisms.

ACKNOWLEDGEMENTS

I wish to convey my deep sense of gratitude to Associate Professor, Dr. Takeshi Todoroki, Department of Gastroenterological and Hepatobiliary Surgery, Institute of Clinical Medicine, University of Tsukuba, for his inspiring guidance and supportive attitude during my research work. His constructive judgments and critical comments to go deep into the cancer research have been very much effective to develop my understandings. It has been a matter of great opportunity to be associated with Dr. Todoroki for all these years and I look forward to instill the same in furthering my career goal.

I wish to express my gratitude to Dr. Nobuhiro Ohkohchi, Professor and Head, Department of Organ Transplantation, for extending all facilities to conduct my research work.

I convey my gratitude to Dr. Tadao Ohno, Ex. Director of Cell Bank, RIKEN, Tsukuba, Dr. Takeshi Hirano, Deputy Director, Institute of Molecular and Cell Biology, AIST, Tsukuba, and Prof. Dr Kohsuke Sasaki, Department of Pathology, Yamaguchi University, School of Medicine for allowing me to conduct advance research in cancer.

I am also thankful to Professor Masanao Miwa, Department of Molecular and Biological Oncology, Dr. Naoto Koike and Dr. Toru Kawamoto, Department of Surgery, Dr. Hiroshi. Kamma, Department of Pathology; University of Tsukuba, for their invaluable helps in all academic matters.

I acknowledge expert technical helps received from Ms. Kaoro Saijo, Ms. Emi Iimura and Mr. Satoru Watanabe of RIKEN while doing cell culture and FACScan.

I am obliged to Dr. Kikuo Nagaoka, president of Nagaoka Hospital, Chiba, International Friendship Association, Tokyo for their financial support and also to Yoneyama Rotary Scholarship Foundation for providing me scholarship.

I received constant encouragements from my parents, sister and other family members. The last but not the least I received extreme support and co-operation from my daughter and son, else it would have been nearly impossible to reach this stage.

Mila Ghosh

CONTENTS

INDEX OF CHAPTERS

CHAPTER – 4: ESTABLISHMENT AND CHARACTERIZATION OF GALLBLADDER CANCER CELL LINES **41-65**

LIST OF FIGURES

LIST OF TABLES

NOTATIONS

ADS:	Adenosquamous
ANA:	Anaplastic
CA19-9:	Carbohydrated antigen 19-9
CEA:	Carcinoembryonic antigen
COX:	Cyclooxygenase
CV:	Coefficient of variation
HGF:	Hepatocyte growth factor
HTERT:	human telomerase reversetranscriptase
HTR:	RNA component of Human telomerase
LN:	Lymph node
MDR:	Multi drug resistance
MET:	Met proto oncogene
MYC:	Transformation gene
NSAID:	Non-steroid anti-inflammatory drug
P:	Poorly differentiated
PCNA:	Proliferating cell nuclear antigen
PDT:	Population doubling time (hours)
PT:	Primary tumor
VEGF:	Vascular endothelial growth factor
RER:	Rough Endoplasmic reticulum
TNFA:	Tumor necrotic factor alpha
TGF □:	Transforming growth factor □
TP53:	Tumor protein 53
W:	Well differentiated
XGC:	Xanthogranulomatous cholecystitis

CHAPTER - 1

INTRODUCTION

Cancer of the gallbladder is relatively rare but highly lethal that is difficult to diagnose and treat. Diagnosis usually occurs at late stages of the disease and in general, the prognosis for patients with advanced gallbladder is often leaded to miserable situation. Surgical resection is difficult due to local invasion, distant metastasis, vascular encasement and invasion. Neither radiation nor conventional chemotherapy significantly improves survival or quality of life.

Gallbladder cancer represents 80-90 % of cancers of the biliary tree. High-standardized mortality ratios of gallbladder cancer are found in cancer registries for South American Countries such as Chile, Peru and Colombia and for Asian countries such as Japan and Thailand (1). Japan has one of the world's highest age-adjusted cancer death rates related to BTC, and it appears to be steadily increasing (5.7 and 11.5 in 1980 and 1998 respectively(2). Carcinoma of the gallbladder is the third most common malignancy of the gastrointestinal tract in the Eastern Uttar Pradesh and (3) western Bihar regions of India. The rates of gallbladder cancer are higher among women than men in all populations. The main associated risk factors identified so far include cholelithiasis (especially untreated chronic symptomatic gallstones), obesity, reproductive factors, chronic infections of the gallbladder and environmental exposure to specific chemicals. Oxidative DNA damage is common in chronic cholecystitis, suggesting a possible link between chronic inflammation and gallbladder carcinogenesis (4).

So far there is no established chemotherapeutic regimen for gallbladder At present only surgical excision of all apparent malignancy is associated with improved 5- year survival (5-7). Therefore, urgent efforts are needed for identification of reliable tumour markers that will facilitate the early detection of gallbladder cancer among susceptible populations, as well as the identification of cancer specific cellular targets that might form the basis for novel therapeutic approaches. For establishing an effective chemotherapy different molecules are analysed in different cancers. Here we have analysed COX2 and MUC1inrelation with gallbladder cancer.

Cyclooxygenase (COX) is a rate-limiting enzyme that catalyzes the formation of prostaglandins from arachidonic acid. Two isoforms of COX have been identified. COX1 is constitutively expressed in most tissues and appears to play a role in normal physiology (examples include cytoprotection of the stomach, platelet aggregation, and renal blood flow) (8). COX2 is an inducible gene and has other functions in addition to inflammatory reactions (9).

Numerous studies suggest that the regular use of aspirin, sulindac and other non-steroid anti-inflammatory drugs (NSAIDs) reduce the risk of colorectal adenoma and cancer (10-14). As cyclooxygenase (COX) is the major target for NSAIDs action and in colorectal and other gastrointestinal cancer it is seen that COX may be involved in the initiation (15), cell proliferation (16), carcinogenesis (17) and progression of tumours (18). It is important to study the role of Cyclooxygenase in gallbladder cancer.

Recently several reports pointed out that the expression of MUC1 may closely related to prognosis of patients with gastrointestinal cancers (19-22) and the more increase expression the more lose their apical polarity (23, 24). It was reported that the depolarised expression of MUC-1 in gallbladder cancer would be a potential prognostic predictor (25) and Yamashita et, al. demonstrated that MUC-1 expression was significantly related to prognosis of patients

with cholangiocarcinoma (26). MUC1 and its family of glycoprotein have been reported to regulate immune recognition (27), cellular adhesion of cancers (28) and differentiation in breast cancer (29). However, status of MUC1 expression in gallbladder cancer in comparison to the normal and inflammatory lesions has not been studied so far. Therefore, it is important to clarify the significance of MUC1 expression in cancerous and non-cancerous lesions of the gallbladder.

Well-characterized cell lines are important tools for understanding the tumour biology and are inevitable for testing new chemotherapeutic and radiological regimen also. They can provide

- Unlimited numbers of cells for experiment
- Multiple and repeated experiments over long time interval is possible,
- Studies of metabolic events in viable cells can be possible
- Manipulation and control cells in vitro in ways not possible in vivo and also
- Exchange of cell lines among several laboratories, there by allowing studies in identical material.

Gallbladder cancer cell lines are not very much reported in world literature and not adequately characterized from genetic analysis viewpoint. Genetic changes are not cleared in gallbladder cancer. Growth factors like HGF, Met, VEGF, TNFA are known to have proliferative effects on biliary epithelial cells (30-33) and cancer of the biliary tract has been associated with point mutations of K-ras and beta-catenin proto-oncogenes; alterations of p53, p16, APC, and DPC4 tumor suppressor genes by a combination of chromosomal deletion, mutation, or methylation; and infrequently microsatellite instability (34). It is inevitable to understand the different genetic changes through CGH to understand oncogenes and tumour suppressing genes in relation to gallbladder tract cancer.

We have checked another new molecule Mortalin in gallbladder cancer cell lines. Mortalin, also known as mthsp70/PBP74/GRP75, resides in multiple subcellular sites including mitochondria, ER, plasma membrane, cytoplasmic vesicles and cytosol. It is differentially distributed in normal and cancerous cells (35). It has been shown to bind to p53 and cause its inactivation (36, 37). Its overexpression imparts growth advantage to HL60 leukemia cells, blocks their differentiation (38), and results in malignant transformation of NIH 3T3 cells (39) and lifespan extension of normal human fibroblasts (37). Considering its multiple functions relevant to cell survival, control of proliferation and malignant transformation we checked Mortalin expression in gallbladder cell lines by immunocytochemically and by western blot and checked Mortalin expression in relation with cell cycle.

REFERENCES

1. Hensen, D., Albores-Savedra, J., and Corle, D. Carcinoma of the gallbladder . Histologic types,stage of disease, grade, and survival rates. Cancer(phila), *70:* 1493-1497, 1992.
2. Vital statistics of Japan. Tokyo,Japan: Japaneese Ministry of Health and welfare statistics association, 1998.
3. Shukla, V. K., Rastogi, A. N., Adukia, T. K., Raizada, R. B., Reddy, D. C., and Sing, S. T. Organochlorine pesticides in carcinoma of the gallbladder;a case-control study. Eur J Cancer Prev, *10:* 153-156, 2001.
4. Kohya, N., Miyazaki, K., Matsukura, S., Yakushiji, H., Kitajima, Y., Kitahara, K., Fukuhara, M., Nakabeppu, Y., and Sekiguchi, M. Deficient expression of O(6)-methylguanine-DNA methyltransferase combined with mismatch-repair proteins hMLH1 and hMSH2 is related to poor prognosis in human biliary tract carcinoma. Ann Surg Oncol., *9:* 371-379, 2002.
5. de Aretxabala, X., Roa, I., and Burgos, L. Gallbladder cancer, management of early tumors. Hepatogastroenterology, *46:* 1547-1551, 1999.
6. de Aretxabala, X., Roa, I., Burgos, L., Araya, J., Fonseca, L., Wistuba, I., and Flores, P. Gallbladder cancer in Chile. A report on 54 potentially resectable tumors. Cancer, *69:* 60-65, 1992.
7. Taner, C. B., Nagomay, D. M., and Donohue, J. H. Surgical treatment of gallbladder cancer. J.Gastrointest. Surg, *8:* 83-89, 2004.

8. Vane, J. Towards a better aspirin. Nature(London), *367:* 215-216, 1994.
9. Williams, C. S. and Dubois, R. N. Prostaglandin endoperoxide synthase: why two isoforms? Am J Physiol, *270:* G393-G400, 1996.
10. Greenberg, E. R., Baron, J. A., Freeman, D. H. J., Mandel, J. S., and Haile, R. Reduced risk of large-bowel adenomas among aspirin users. J Natl Cancer Inst, *85:* 912-916, 1993.
11. Kune, G. A., Kune, S., and Watson, L. F. Colorectal cancer risk, chronic illnesses, operation, and medications:case control results from the Melbourne Colorectal cancer study. Cancer Res, *48:* 4399-4404, 1988.
12. Rosenberg, L., Palmer, J., Zauner, A., Warshauer, M., Stolley, P., and Shapiro, S. A hypothesis: nonsteroidal anti-inflammatory drugs reduce the incidence of the large bowel cancer. J Natl cancer Inst, *83:* 355-358, 1991.
13. Suh, O., Mettlin, C., and Petrelli, N. J. Aspirin use,cancer, and polyps of the large bowel. Cancer(Phila.), *72:* 1171-1177, 1993.
14. Thun, M. J., Namboodiri, M. M., Calle, E. E., Flanders, W. D., and Health, C. W. J. Aspirin use and risk of fatal colon cancer. Cancer Res, *53:* 1322-1327, 1991.
15. Smith, B. J., Curtis, J. F., and Eling, T. E. Bioactivation of xenobiotics by prostaglandin H synthetase. Chem Biol Interact, *79:* 245-264, 1991.
16. Craven, P. A., Satio, R., and DeRuberties, F. R. Role of local prostaglandin synthesis inthe modulation of proliferative activity of rat colonic epithelium. J Clin Invest, *72:* 1365-1375, 1983.
17. Bennett, A. and del Tacca, M. Prostaglandins in human colonic carcinoma. Gut, *16:* 409, 1975.
18. Jaffe, B. M. Prostaglandins and cancer: an update. Prostaglandins, *6:* 453-461, 1974.
19. Utsunomia, T., Yonezawa, S., Sakamoto, H., Kitamaru, H., Hokita, S., Aiko, T., Tanaka, S., Irimura, T., Kim, S., and Sato, E. Expression of MUC1 and MUC2 mucins in gastric carcinomas: Its relationship with the prognosis of the patients. Clin Can Res, *4:* 2605-2614, 1998.
20. Baldus, S., Zirbes, T., Engel, S., Hanish, F., Monig, S., Lorenzen, J., Glossman, J., Fromm, S., Thiele, J., Pichlamaier, H., and Dienes, H. Correlation of the immunohistochemical reactivity of mucin peptide cores MUC1 and MUC2 with the histopathological subtype and prognosis of gastric carcinomas. Int J Cancer, *79:* 133-138, 1998.
21. Symonds, D. A. and Vickery, A. L., Jr Mucinous carcinoma of the colon and rectum. Cancer (Philla), *37:* 1891-1900, 1976.
22. DeMascarel, A., Coindre, J. M., DeMascarel, I., Torjani, M., Maree, D., and Hoerni, B. The prognostic significance of specific histologic features of carcinoma of the colon and rectum. Surg. Gynecol. Obstet, *153:* 511-514, 1981.
23. Hilkens, J., Buijs, F., Hilgers, J., Hageman, P., Calafat, J., Sonnenberg, A., and Valk, M. V. Monoclonal antibodies against human milk-fat globule membranes detecting differentiation antigens of the mammary gland and its tumours. Int. J. Cancer, *34:* 197-206, 1984.
24. Zaretsky, J. Z., Weiss, M., Tsarfaty, I., Hareuveni, M., Wreschner, D. H., and Keydar, I. Expression of genes coding for pS2,c-erbB2, estrogen recepter and the H23 breast tumor-associated antigen. A comparative analysis in breast cancer. FEBS Lett, *265:* 46-50, 1990.
25. Kawamoto, T., Shoda, J., Irimura, T., Miyahara, N., Furukawa, M., Ueda, T., Asano, T., Kano, M., Koike, N., Fukao, K., Tanaka, N., and Todoroki, T. Expression of MUC1 mucins in the subserosal layer correlates with postsurgical prognosis of

pathological ttumour stage2 carcinoma of the gallbladder. Clin. cancer Res, *7:* 1333-1342, 2001.

26. Yamashita, K., Yonezawa, S., Tanaka, S., Shirahama, H., Sakoda, K., Imai, K., Xing, P., Mckenzie, I. F. C., Hilkens, J., Kim, S., and Sato, E. Immunohistochemical study of mucin carbohydrates and core proteins in hepatolithiasis and cholangiocarcinoma. Int. J. Cancer, *55:* 82-91, 1993.
27. Hayes, D. F., Silberstein, D. S., Rodrique, S. W., and Kufe, D. W. DF3 antigen,a human epithelial cell mucin, inhibits adhesion of eosinophils to antibody coated targets. J Immunol, *145:* 962-970, 1990.
28. Lightenberg, M. J. L., Buijs, F., Vos, H. L., and Hilkens, J. Suppression of cellular aggregation by high levels of episialin. Cancer Res, *52:* 2318-2324, 1992.
29. Lundy, J., Thor, A., Maenza, R., Schlom, J., Forouhar, M., Testa, M., and Kufe, D. Monoclonal antibody DF3 correlates with tumour differentiation and hormone receptor status in breast cancer patients. Breast Cancer Res Treat, *5:* 269-276, 1985.
30. Benckert, C., Jonas, S., Cramer, T., Von Marschall, Z., Schafer, G., Peters, M., Wagner, K., Radke, C., Wiedenmann, B., Neuhaus, P., Hocker, M., and Rosewicz, S. Transforming growth factor beta 1 stimulates vascular endothelial growth factor gene transcription in human cholangiocellular carcinoma cells. Cancer Res, *63:* 1083-1092, 2003.
31. Harada, K., Terada, T., and Nakanuma, Y. Detection of transforming growth factor a protein and messanger RNA in hepatobilliary diseases by immunohistochemical and in situ hybridyzation techniques. Hum. Pathol, *27:* 787-792, 1996.
32. Radaeva, S., Ferreira-Gonzalez, A., and Sirica, A. Overexpression of c-NEU and c-MET during rat liver cholangio carcinogenesis: a link between biliary intestinal metaplasia and mucin -producing cholangiocarcinoma. Hepatology, *29:* 1453-1462, 1999.
33. Alpini, G., Glaser, S. S., Ueno, Y., Pham, L., Podila, P. V., Caligiuri, A., Lesage, G., and Larusso, N. F. Heterogeneity of the proliferative capacity of rat cholangiocytes after bile duct ligation. Am.Physiol, *274:* G767-G775, 1998.
34. Rashid, A. Cellular and molecular biology of biliary tract cancers. Surg Oncol Clin N Am, *11:* 995-1009, 2002.
35. Wadhwa, R., Kaul, S., Ikawa, Y., and Sugimoto, Y. Identification of a novel member of mouse hsp70 family. Its association with cellular mortal phenotype. J Biol Chem, *268:* 6615-6621, 1993.
36. Wadhwa, R., Takano, S., Robert, M., Yoshida, A., Nomura, H., Reddel, R., Mitsui, Y., and Kaul, S. Inactivation of tumor suppressor p53 by mot-2, a hsp70 family member. J Biol Chem, *273:* 29586-29591, 1998.
37. Kaul, S., Reddel, R., Sugihara, T., Mitsui, Y., and Wadhwa, R. Inactivation of p53 and life span extension of human diploid fibroblasts by mot-2. FEBS Lett., *474:* 159-164, 2000.
38. Xu, J., Xiao, H., and Sartorelli, A. Attenuation of the induced differentiation of HL-60 leukemia cells by mitochondrial chaperone HSP70. Oncol Res, *11*, 1999.
39. Kaul, S., Duncan, E., Englezou, A., Takano, S., Reddel, R., Mitsui, Y., and Wadhwa, R. Malignant transformation of NIH3T3 cells by overexpression of mot-2 protein. Oncogene, *17:* 907-911, 1998.

CHAPTER - 2

CYCLOOXYGENASE EXPRESSIONS IN GALLBLADDER CANCER

2.1. ABSTRACT

The upregulated expression of cyclooxygenase (COX2) in various cancerous tissues has been reported recently, however, the evidence in lesions of the gallbladder remains unclear. Therefore, we estimated COX expressions in tissues of the gallbladder with different lesions. The COX expressions were evaluated separately in the epithelium and in the stroma of the gallbladder. Specimens consisted of gallbladder cancer (n=64), chronic cholecystitis (n=9), xanthogranulomatous cholecystitis (XGC; n=8) and the normal gallbladder (n=11). Those specimens were collected by surgical resection from India and Japan. In the normal gallbladder, the COX-2 expression rate was significantly higher (81.8%) in the epithelium than in the stroma (0 %). The COX-2 expression rates in the epithelium in different lesions were 89% in cancer, 100% in chronic cholecystitis and 87.5% in XGC. Contrarily, it was significantly lower (47.4%) in the non-cancerous adjacent epithelium to cancerous lesion than those not only of cancer, but also chronic cholecystitis, XGC and normal gallbladder. Regarding to the expression in the stroma, the COX2 expression rate was 70.3%, 66.6% and 87.5% in cancer, chronic cholecystitis and XGC, respectively. Those rates were significantly higher than that of the normal gallbladder. Furthermore, the rate in non-cancerous adjacent stroma to cancer (36.8%) is significantly lower than that of cancer and XGC. However, the difference of rate between of normal and of chronic cholecystitis was not significant. The COX2 expression rates were significantly higher in both the epithelium and the stroma in well and moderately differentiated cancer group (n=47) than in poorly and undifferentiated cancer

group (n=17); 95.7% vs.78.5% and 76.5% vs. 41.1%, respectively. Our results suggest that COX-2 expression in the gallbladder may be regulated by various factors and not directly related to carcinogenesis. The significance of its repression in the non-cancerous adjacent tissue to cancer lesion should be re-evaluated.

2.2 INTRODUCTION

Cyclooxygenase (COX) is the rate-limiting enzyme in the conversion of arachidonic acid to prostanoids. Two COX isoforms have been cloned, of which COX-1 is constitutively expressed, while the expression of COX2 is low or nondetectable in most tissues, but can be readily induced in response to cell activation by cytokines, growth factors and tumour promoters (1-4). Thus, COX1 is considered a housekeeping gene and thought to be responsible for the synthesis of prostanoids involved in cytoprotection of the stomach (5) and renal blood flow(6). In contrast, COX2 is an inducible, immediate-early gene, and its role has been related to inflammation (7, 8), reproduction (1, 4) and carcinogenesis (9, 10, 11). Expression of COX2 is elevated in a variety of human malignancies and in their precursor lesions. Furthermore, genetic deletion or pharmacological inhibition of COX2 suppresses tumour growth in several animal models of carcinogenesis. In humans, elevated COX2 expression is associated with poor prognosis in adenocarcinomas of the digestive tract and the breast, and a selective inhibitor of COX2 reduced polyp burden in patients who suffer from familial adenomatous polyposis (12-15). Thus, COX-2 seems to be a relevant target in chemoprevention.

The present study was undertaken to determine whether there is any differential expression of COX1 and COX2 in normal gallbladder, chronic cholecystitis, xanthogranulomatous cholecystitis (XGC) and cancer.

2.3 MATERIALS AND METHODS

2.3.1 Tissue Specimen

We have examined surgically resected specimens of 64 cases of gallbladder carcinoma, 9 cases of chronic cholecystitis and 8 cases of XGC. These cases were collected from SGPGI of India. Eleven cases of normal gallbladder tissues collected from advanced cases of Japanese gastrointestinal cancer patients after extensive surgery. Amongst the 64 cases of cancer specimens we found normal epithelium in only 19 cases. Histologic diagnosis is made by haematoxylin and eosin stained sections.

2.3.2 Antibodies

Immunohistochemical staining was performed with polyclonal antibodies, goat antihuman COX1 IgG (Santa Cruz Biotechnology, California) and rabbit antihuman COX2 IgG (IBL, Gunma, Japan).

2.3.3 Immunohistochemistry

Tissues of gallbladder cancer and normal gallbladder, chronic cholecystitis and XGC were preserved in 10% formalin, embedded in paraffin, serially sectioned into 4 μm thick, mounted into polysine coated slides and deparaffinised afterwards. The slides were immersed for 20 min in 0.3% hydrogen peroxide in methanol to deplete endogenous peroxidase. After washing they were incubated in a humid chamber in room temperature with protein blocking agent for 5 minutes. Primary antibodies against COX1 and COX2 were used at a dilution of 1:40 and 1:50 respectively. Negative control was made by replacing primary antibody by bovine serum albumin and by putting primary antibodies in the smooth muscles of the same sections was used as positive control. After the application of primary antibodies slides were incubated in a humid chamber for 1 hour. Tissues sectioned were washed with PBS for 15 minutes after

changing the buffer for three times. Then biotinylated secondary antibodies were applied for 10 minutes in same chamber at room temperature. After washing for 15 minutes streptavidin peroxidase reagent was applied and incubated in the same chamber for 10 minutes at room temperature. Finally reaction product was visualized by developing color by incubating the slides within solution of 0.3% hydrogen peroxide, diaminobenzidine tetrahydrochloride and PBS. Counter staining was done with haematoxylin. The section was mounted in crystal mount and then coverslipped in xylene.

2.3.4 Evaluation of COX Expression

The expression of COX in the epithelium was examined under a light microscope. The COX expression was judged positive when more than 5% cells were stained. The staining cell fraction was evaluated as Grade I when 5 to 30% cells in one section are stained, Grade II; 30-60% cells are stained and Grade III; more than 60% cells are stained.

2.4 RESULTS

We observed homogeneous distribution of COX1 and heterogeneous expressions of COX2 in all tissues irrespective of histologic types, grades and invasion of cancer. Immuno-reactive COX-2 was highly expressed in cancer (Fig.2.5, 2.6), chronic cholecystitis (Fig.2.2), XGC (Fig.2.3) and in normal gallbladder tissues (Fig.2.1). COX-2 expressions were evaluated separately in the epithelium and stroma of the tissues and for cancer we tried to find correlation between COX-2 expression and histopathologic type, grade and the extent of the primary tumour (T category).

2.4.1 COX2 expression in the epithelium and stroma of the gallbladder

Our study reveals that the incidence of COX2 expression was significantly higher in the epithelium of cancer tissues (89%), chronic cholecystitis (100%) and XGC (87.5%) than that

of adjacent non-cancerous tissues (47.4%). Interestingly the incidence of COX-2 expression is also significantly higher in the normal gallbladder (81.8%) (Table 1).

No expression of COX2 was found in the stroma of the normal gallbladder unlike in the epithelium. The incidence of COX-2 expression in the stroma is significantly lower in normal gallbladder (0%) than those in cancer tissues (70.3%), chronic cholecystitis (66.6%) and XGC (87.5%). In the non-cancerous stroma adjacent to cancer the incidence of COX2 expression (36.8%) was significantly lower comparing to those in cancer (70.3%) and XGC (87.5%) and it was marked in the stroma of chronic cholecystitis (66.6%) (Fig.2.6).

2.4.2 COX2 expression according to histological grade

In Table 2 we studied to correlate COX2 expression with tumour differentiation. Out of 64 specimens, 41 were well differentiated, 6 were moderately differentiated, 14 were poorly differentiated and 3 were undifferentiated cancer. We put well and moderately differentiated carcinoma in a single group and poorly differentiated and undifferentiated in another group. The incidences of COX2 expression in the epithelium (78.5%) and stroma (41.1%) of poorly differentiated carcinoma was significantly lower than those in the epithelium (95.7%) and stroma (76.5%) of well and moderately differentiated carcinoma.

In the group of well and moderately differentiated carcinomas the intensity of COX2 staining was homogeneous, but it was heterogeneous in poorly differentiated and undifferentiated carcinomas. Out of 47 specimens of well and moderately differentiated carcinoma, 19 were classified as grade I, 6 were grade II, 20 were in grade III and the remaining 2 specimens did not express COX-2 at all. Where as out of 17 specimens of poorly differentiated and undifferentiated carcinomas, including poorly differentiated adenocarcinoma (n=13), Oat cell carcinomas (n=1) and mucinous carcinoma (n=3), 10 were grade I, 2 were in grade II, and the remaining of 5 were negative staining. The staining cell

fraction was significantly (P=0.0015) larger in well differentiated than in poorly differentiated carcinoma.

2.4.3 COX2 expression according to the extent of the primary tumour (T)

The extent of the primary tumour had been classified by T category according to the TNM criteria (30). Due to the non-availability of paraffin specimens of broad area of cancer, all 64 but two specimens of gallbladder cancer could be categorized. Of those 62 specimens, 4 were T1; tumour invades lamina propria or muscle layer, 15 were T2; tumour invades perimuscular connective tissue, but no extension beyond serosa or into the liver, 30 were T3; tumour perforates the serosa or directly invades one adjacent organ, or both (extension 2 cm or less into the liver) and the remaining 13 were T4; tumour extends more than 2 cm into the liver, and/or into two or more adjacent organs.

The incidence of COX2 expression in cancer tissue was gradually decreasing as the tumour penetration (Table 3). However, there was no statistical significance in the relationship between the extent of the primary tumour and the incidence of COX2 expression. The incidence of COX-2 expression in the stroma was between 50% and 80% and there was no significant correlation between their incidences and the extent of tumour invasion.

2.4.4 COX2 expression according to histopathological type

Sixty-four specimens of gallbladder cancer consisted of 58adenocarcinoma, 2 adenosquamous carcinoma, 1 oat cell carcinoma and 3 mucinous carcinoma. COX2 expression was highly marked without statistical significance in adenocarcinoma (epithelium; 91.3%, stroma; 70.6%), in adenosquamous carcinoma (epithelium; 100%, stroma; 100%), oat cell carcinoma (epithelium; 100%, stroma; 100%), but it was lower in mucinous carcinoma (epithelium, 33.3%, stroma, 33.3%).

2.5 DISCUSSIONS

To our knowledge this study is the first report regarding COX2 expression in gallbladder tissues in normal, inflammations and cancer conditions. Like colorectal and other cancers, we also found significant difference in the incidence of COX2 expression between cancer tissues and non-cancerous tissues adjacent to cancer tissues. Moreover, high expressions of COX-2 in chronic cholecystitis, XGC may suggest them as precancerous condition as was discussed in inflammatory bowel disease (31). But unexpectedly the incidence of COX2 expression in the non-cancerous epithelium adjacent to cancer was significantly lower than that in normal gallbladder epithelium (Table-1). The exact reason for the significant difference is not known at present, however, high expression of COX2 in the epithelium of normal gallbladder as well as inflammatory tissues can be explained by the presence of bile because bile acids activate the transcription of COX2 (16). While, in the stroma of normal gallbladder COX2 expression was nil, despite of high COX2 expression in stroma of inflammatory and cancer tissues. Based on these evidences, COX2 expression in the stroma might be assumed to be repressed by the intact basement membrane, which separates epithelial layer from the stroma layer as a barrier. Since the basement membrane in cancerous and inflammatory tissues is lacking in part or damaged, bile may reach the stroma through the barrier to induce COX-2. In addition, abundant inflammatory cells infiltrating in cancerous and inflammatory tissues produce various kinds of cytokines to induce COX2 (10). The COX2 expression is significantly less in the non-cancerous adjacent part than that in cancer tissues. Some cytokines like IFN-gamma (17), IL-4, IL-10 (18) and IL-13 (19), which are known to inhibit COX2 expression, may regulate COX2 expression of the non-cancerous adjacent tissues to cancer. However, much more studies should be required to prove our hypothesis.

It is often pointed out that poorly differentiated carcinoma is more invasive with a

very high metastatic potential (20) and COX2 expression is positively correlated to metastatic potential (11). Contrarily, we found that the incidence of COX2 expression in well and moderately differentiated carcinoma were significantly higher than those in poorly differentiated carcinoma of the gallbladder. The similar findings have been reported in hepatocellular carcinoma and authors claimed that COX-2 expression might involve in the initiation of carcinogenesis (21). However, our findings of high incidence of COX2 expression in normal and inflammatory gallbladder conditions do not support the above hypothesis at least in gallbladder carcinogenesis.

There are many studies suggesting that COX2 be not directly related with carcinogenesis. Though COX2 mRNA and protein have found to be over expressed in human colorectal (22), gastric (23), hepatocellular (21), lung (24) and pancreatic carcinoma (25). On the other hand, there is no remarkable expression of COX-2 in basal cell carcinoma (26) and mucinous carcinoma of the ovary (23). It is noteworthy that 15% of human colorectal cancer and 60 % of colorectal adenoma did not express COX-2 protein (27). The role of COX2 expression in gallbladder carcinogenesis should be evaluated with further study on the mechanism of positive and negative inducers of COX-2.

2.6 CONCLUSIONS

As conclusion, our results suggest that COX2 expression in the gallbladder may be regulated by various factors and not directly related to carcinogenesis. The significance of its repression in the non-cancerous adjacent tissue to cancer lesion and significantly less expression in the epithelium and stroma of poorly differentiated cancer than well-differentiated cancer should be re-evaluated. The role of COX2 expression in the process of carcinogenesis or tumour progression and also the mechanism of its suppression in the tissue adjacent to cancer of the gallbladder should be further clarified.

Table 2.1: COX 2 expressions in the epithelium and stroma of different Gallbladder lesions

Gallbladder tissues from	No. of cases	Incidence of COX-2 positivity in epithelium	Incidence of COX-2 positivity. in stroma
Normal Gallbladder	11	9/11 (81.8%)[1)]	0/11 (0%)[3)]
Cancer cells	64	57/64 (89.1%)[1)]	45/64 (70.3%)[3)]
Adjacent to cancer cells	19	9/19 (47.4%)[2)]	7/19 (36.8%)[4)]
Chronic cholecystities	9	9/9 (100%)[1)]	6/9 (66.7%)
Xanthogranulomatous cholecystitis	8	7/8 (87.5%)[1)]	7/8 (87.5%)[3)]

[1)]: P values of all are significant (<0.05) with respect to [2)].

[3)]: P values of all are significant (<0.05) with respect to[4)].

Table 2.2: COX-2 expression according to histological grade of gallbladder cancer

Histologic grade	No. of Cases	Incidence of COX-2 Positivity	
		Epithelium	Stroma
Well and moderately differentiated	47[$]	45/47 (95.7%)[1)]	36/47 (76.5%)[3)]
Poorly differentiated	17	12/17 (70.6%)[2)]	7/17 (41.1%)[4)]
Total	64	57/64 (89.0%)	43/64 (67.1%)

There was significant difference between 1) and 2), and 3) and 4) ($P<0.05$)

[$]The numbers of well and moderately differentiated cases are 41 and 6, respectively.

Table 2.3: COX-2 expression according to the extent of the primary tumour (T)

		Incidence of COX-2 positivity	
T	No. of cases	Epithelium	Stroma
T1	4	4/4 (100%)	2/4 (50%)
T2	15	14/15 (93.3%)	10/15 (66.6%)
T3	30	27/30 (90%)	23/30 (76.6%)
T4	13	10/13 (76.9%)	8/13 (61.5%)
Total	62	55/62 (88.7%)	43/62 (69.4%)

T is a category of the primary tumour in the TNM classification criteria.

Microscopic photographs of the diseased and normal gallbladder stained by immunoreactive anti COX-2 antibody with dilution 1:50 were shown. Positive staining was indicated with brownish pigmentation. Original magnification was described in each photograph.

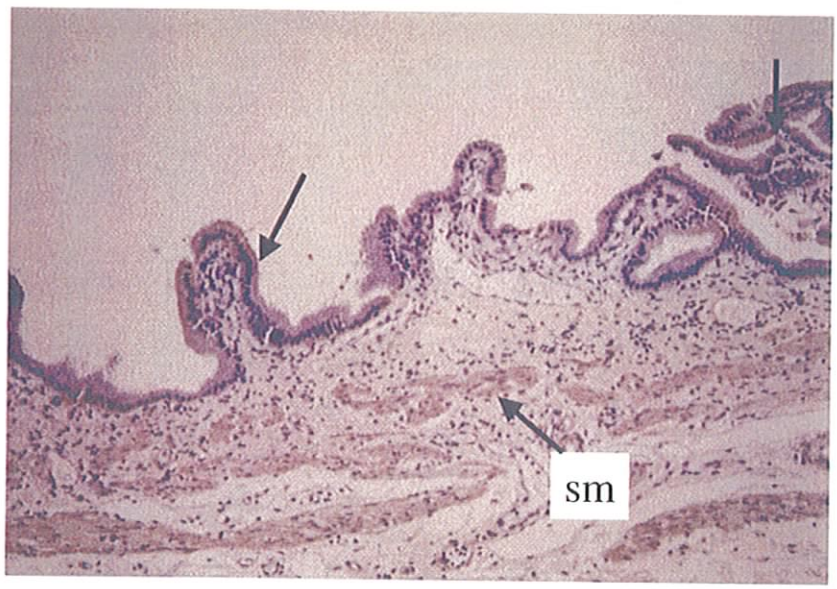

Fig.2.1: Normal gallbladder with magnification x33.
The epithelium (arrows) and smooth muscles (sm) expressed COX-2 weakly, while expression was not noted within the stroma

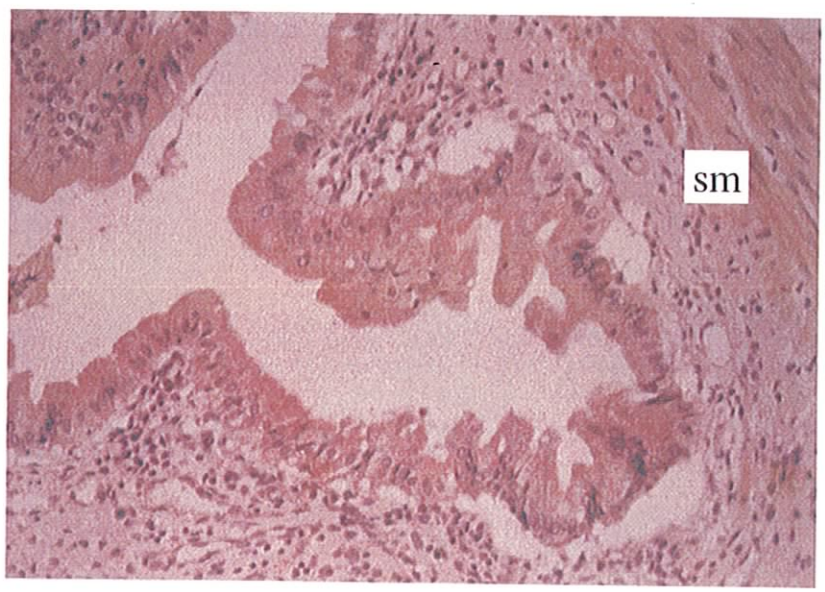

Fig.2.2: Chronic cholecystitis with magnification x66.
The hyperplastic epithelium and smooth muscles (sm) showed a high level of COX-2.

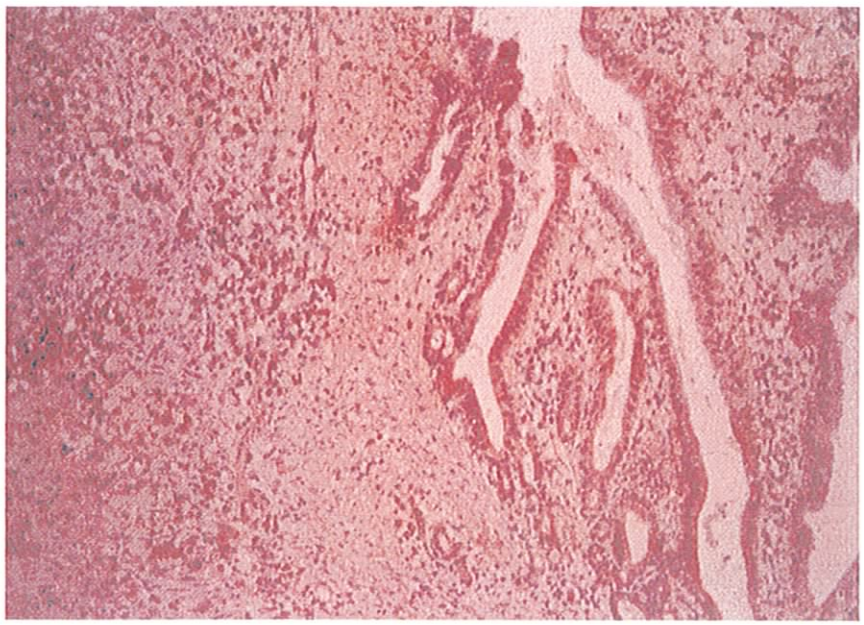

Fig.2.3: Xanthogranulomatous cholecystitis (XGC) with magnification x 33. The epithelium and stroma demonstrated a high level of COX-2 expression

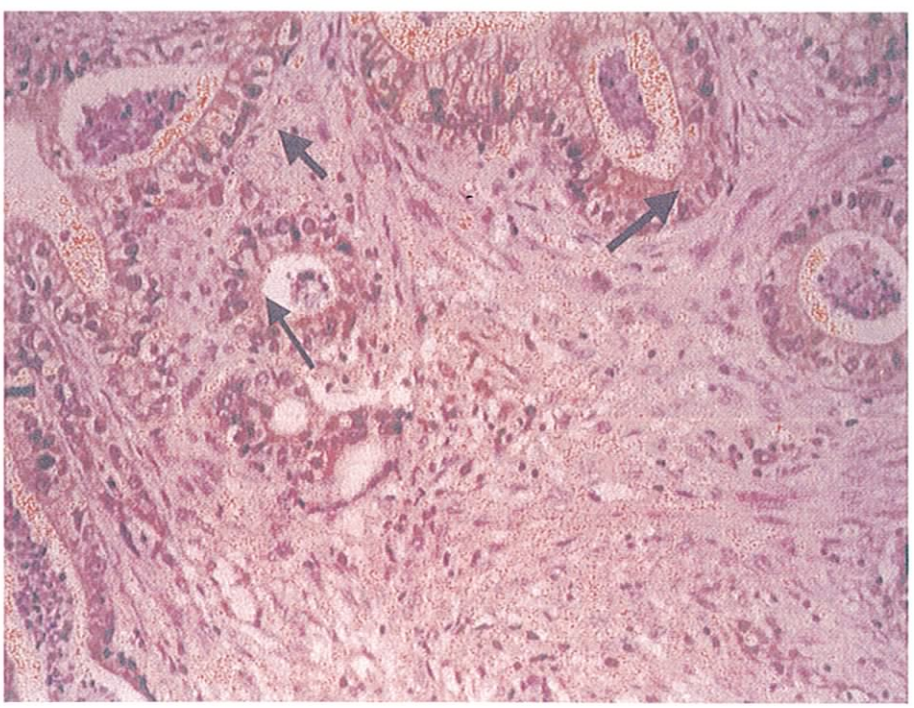

Fig.2.4: Well differentiated adenocarcinoma with magnification x66 High expression of COX-2 in cancer cells in the epithelium (arrows)

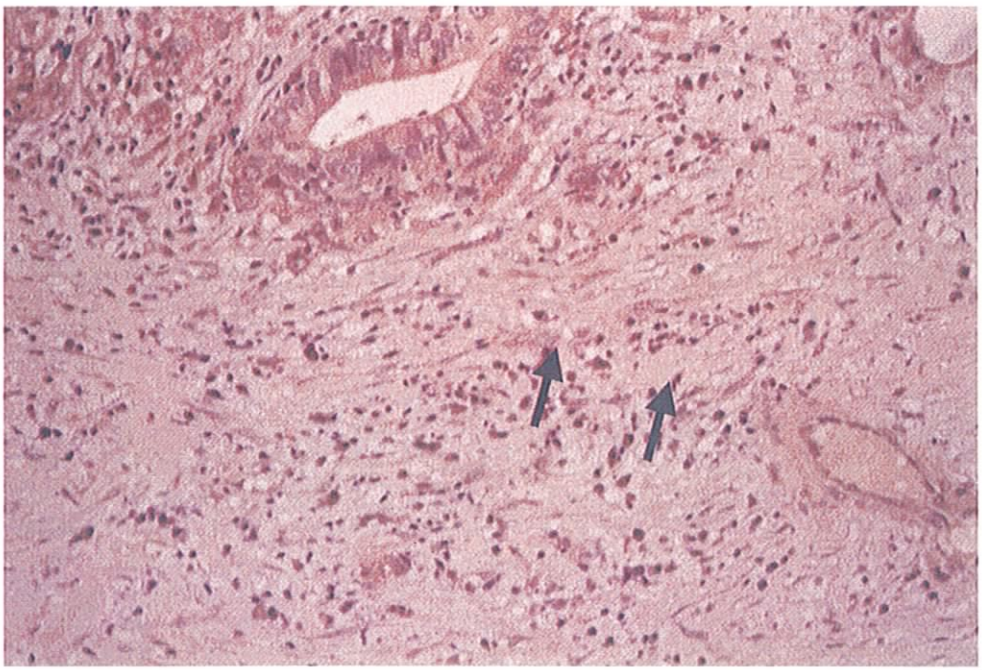

Fig.2.5: Stroma adjacent to well-differentiated carcinoma with magnification x66. Stroma (fibroblast) expressed COX-2 strongly (arrows)

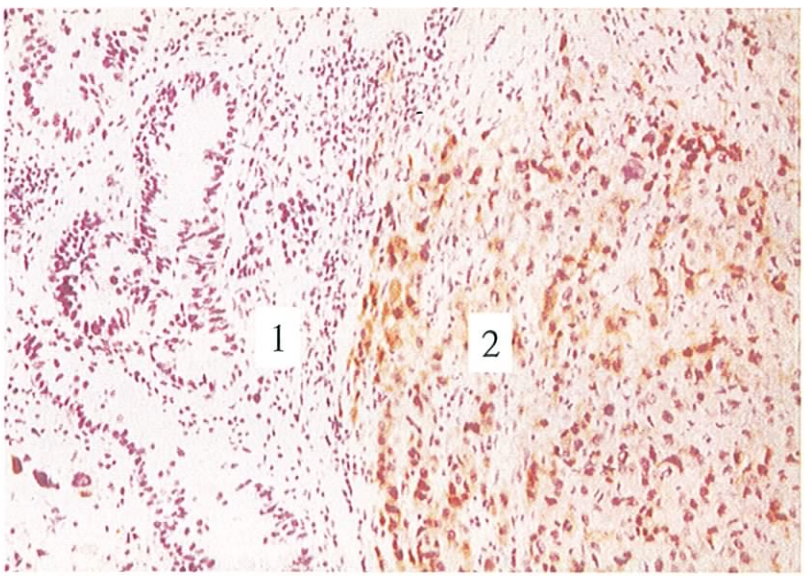

Fig.2.6: Cancer and adjacent non-cancerous tissue of the gallbladder with magnification x66. High expression of COX-2 in cancerous portion (2) and comparatively less expression in adjacent non-cancerous tissues (1)

2.7 REFERENCES

1. Herschman, H. R. Prostaglandin synthase 2. Biochim Biophys Acta, *1299:* 125-140, 1996.
2. Smith, W., Garavito, R. M., and Dewitt, D. L. Prostaglandin endoperoxide H synthases (cyclooxygenase)-1 and -2. J Biol Chem, *271:* 33157-33160, 1996.
3. Smith, W. L. and Marnett, L. J. Prostaglandin endoperoxide synthase: Structure and catalysis. Biochim Biophys Acta, *1083:* 1-17, 1991.
4. Williams, C. S. and Dubois, R. N. Prostaglandin endoperoxide synthase: why two isoforms? Am J Physiol, *270:* G393-G400, 1996.
5. Sakamoto, C. Roles of COX-1 and COX-2 in gastrointestinal pathophysiology. J Gastroenterol, *33:* 618-624, 1998.
6. Smith, W. L. and Bell, T. G. Immunohistochemical localization of prostaglandin forming cyclooxygenase in renal cortex. Am J Physiol, *235:* F451-F457, 1978.
7. Hla, T. and Neilson, K. Human cyclooxygenase-2 cDNA. Proc. Natl. Acad. Sci. USA, *89:* 7384-7388, 1992.
8. Hla, T., Ristimiki, A., Appleby, S., and Barriocanal, J. G. Cyclooxygenase gene expression in inflammation and angiogenesis. Ann NY Acad Sci, *696:* 197-204, 1993.
9. Oshima, M., Dinchuk, J. E., Kargman, S. L., Oshima, H., Hancock, B., Kwong, E., Trzaskos, J. M., Evans, J. F., and Taketo, M. M. Suppression of intestinal polyposis inApc ≲ 716 knockout mice by inhibition of cyclooxygenase2 (Cox-2). Cell, *87:* 803-809, 1996.
10. Tsujii, M. and DuBois, R. N. Alterations in cellular adhesion and apoptosis in epithelial cells overexpressing prostaglandin endoperoxide synthase 2. Cell, *83:* 493-501, 1995.
11. Tsujii, M., Kawano, S., and DuBois, R. N. Cyclooxygenase-2 expression in human colon cancer cells increases metastatic potential. Proc Natl Acad Sci USA, *94:* 3336-3340, 1997.
12. Kune, G. A., Kune, S., and Watson, L. F. Colorectal cancer risk, chronic illnesses, operation, and medications:case control results from the Melbourne Colorectal cancer study. Cancer Res, *48:* 4399-4404, 1988.
13. Rosenberg, L., Palmer, J. R., Zauner, Ā. G., Warshauer, M. E., Stolley, P. D., and Shapiro, S. A hypothesis: nonsteroidal anti-inflammatory drugs reduce the incidence of the large bowel cancer. J Natl cancer Inst, *83:* 355-358, 1991.
14. Suh, O., Mettlin, C., and Petrelli, N. J. Aspirin use,cancer, and polyps of the large bowel. Cancer(Phila.), *72:* 1171-1177, 1993.
15. Thun, M. J., Namboodiri, M. M., Calle, E. E., Flanders, W. D., and Health, C. W. J. Aspirin use and risk of fatal colon cancer. Cancer Res, *53:* 1322-1327, 1991.
16. Zhang, F., Subbaramaiah, K., Altorki, N., and Dannenberg, A. Dihydroxy bile acids activate the transcription of cyclooxygenase-2. Journal of Biological Chemistry, *273:* 2424-2428, 1998.
17. Barrios, R. M. and Kris, C. Novel regulation of cyclooxygenase-2 expression and prostaglandin E2 by IFN-g in human macrophases. Journal of Immunology, *161:* 2441-2448, 1998.
18. Niiro, H., Otsuka, T., Tanabe, T., Hara, S., Kuga, Y., Nemoto, Y., Tanaka, H., Nakashima, S., Kitajima, M., and Niho, Y. Inhibition by IL-10 of ininducible cyclooxygenase expression in lipopolysaccharide-stimulated monocytes:its underlying mechanism in comparison with interleukin-4. Blood, *85:* 3736, 1995.

19. Endo, T., Ogushi, F., and Sone, S. LPS-dependent cyclooxygenase-2 induction in human monocytes is down-regulated by IL-13, but not by IFN-g. Journal of Immunology, *156:* 2240, 1996.
20. Todoroki, T., Kawamoto, T., Takahashi, H., Takada, Y., Koike, N., Otsuka, M., and Fukao, K. Treatment of gallbladder cancer by radical resection. British journal of surgery, *86:* 622-627, 1999.
21. Koga, H., Sakisaka, S., Ohishi, M., Kawaguchi, T., Taniguchi, E., Sasatomi, K., Harada, M., Kusaba, T., Tanaka, M., Kimura, R., Nakashima, O., Kojiro, M., Kurohiji, T., and Sata, M. Expression of Cyclooxygenase-2 in Human Hepatocellular Carcinoma: Relevance to Tumour Dedifferenciation. HEPATOLOGY, *29:* 688-696, 1999.
22. Eberhart, C. E., Coffey, R. J., Radhika, A., Giardiello, F. M., Ferrbach, S., and Dubois, R. N. Upregulation of Cyclooxygenase 2 expression in human Colorectal adenomas and adenocarcinomas. Gastroenterology, *107:* 1183-1188, 1994.
23. Ristimiki, A., Honkanen, N., Jankala, H., Sipponen, P., and Harkonen, M. Expression of Cyclooxygenase-2 in human gastric carcinoma. Cancer Res, *57:* 1276-1280, 1997.
24. Hida, T., Yatabe, Y., Achiwa, H., Muramatsu, H., Kozaki, K., Nakamura, S., Ogaw, M., Mitsudomi, T., Sugiura, T., and Takahashi, T. Increased expression of Cyclooxygenase2 occurs frequently in human Lung cancers. Cancer Res, *58:* 3761-3764, 1998.
25. Tucker, O. N., Dannenbarg, A. J., Yang, E. K., Zhang, F., Teng, L., Daly, J. M., Soslow, R. A., asferre, J. L., Woerner, B. M., Koki, A. T., and Fahey III, T. J. Cyclooxygenase-2 expression is upregulated in Human Pancreatic Cancer. Cancer res, *59:* 987-990, 1999.
26. Leong, J., Hughes-Fulford, M., Rakhlin, N., Habib, A., Maclouf, J., and Goldyne, M. E. Cyclooxygenases in human and mouse skin and cultured human keratocytes: association of COX-2 expression with human keratinocyte differentiation. Exp Cell res, *224:* 79-87, 1996.
27. Elder, D. J. E. and Paraskeva, C. COX-2 inhibitors for colorectal cancers. Nature Medicine, *4:* 392-393, 1998.

CHAPTER – 3

EXPRESSIONS OF MUC1 CORE PROTEIN IN THE GALLBLADDER TISSUES

3.1. ABSTRACT

Significance of MUC1 core protein expression in the gallbladder tissues in relation to cancer and non-cancer disease have not quite understood. Clarifying significance of MUC1 expression was the aim of our study. A monoclonal antibody (CA15-3; DF3) was applied to stain MUC1 core protein in surgical specimens. MUC1 core protein expression is significantly high ($p<0.0001$) in gallbladder cancer (69/88, 78.4%), while, very trace in normal and inflammatory tissues. The expression rate is significantly lower ($p<0.0001$) when cancer did not penetrate the muscle layer than when cancers did penetrate the layer. The MUC1 core protein expression rate was 29% (4/14) in T1 tumors, while it was ranged from 79% to 93 % in the advanced T categories: 79% (11/14) in T4, 89% (40/45) in T3, and 93% (14/15) in T2, respectively. The polarized and depolarized staining patterns of MUC1 expression were recognized. Every cell of normal, inflammatory epithelia, including 8 xanthogranulomatous cholecystitis and T1 cancers had the polarized pattern. The depolarized pattern was dominant in cancer cells from the advanced categories T2, T3 and T4. That is, 60% (45/74) of cancer cells from the epithelial layer and 78 % (58/74) of penetrating cancer cells from deeper layers had the depolarized pattern. There was no significant correlation of MUC1 expression rate and staining pattern with cancer differentiation

and microscopic venous invasion. On the other hand, lymphatic vessel invasion was significantly correlated with MUC1 staining pattern but not with expression rate. In conclusion, MUC1 core protein expression rate was significantly higher in gallbladder cancer than normal and inflammatory gallbladder epithelium. In cancer cells, the depolarized staining pattern was dominant and depolarized MUC1 expression may predict lymphatic vessel invasion of the gallbladder cancer tissue.

3.2. INTRODUCTION

MUC1 (DF3) gene encodes a high molecular mass glycoprotein that is aberrantly expressed by malignant mammary epithelium. The DF3 glycoprotein is a member of a family of related carcinoma associated antigens with core proteins ranging from 160-230 kDa(1, 2).This antigen is expressed on the apical borders of secretory mammary epithelial cells and at high levels in the cytosol of less differentiated malignant cells(3). Different studies demonstrated that this family of glycoproteins regulates immune recognition and cellular adhesion (4, 5). Expression of mucin core protein and mucin carbohydrate antigens is correlated with the biologic behavior of pancreatic tumour (6). Mucin peptide core antigens are suitable markers for the tubule rich gastric carcinoma (7). Several reports demonstrated that MUC1 expression is strongly related to tumor progression within gastrointestinal cancers (8-10) and also in gallbladder cancer (11).

The normal epithelial cells secrete a variety of different mucins (high molecular weight glycoproteins); these mucins serve protective and lubricating roles in the normal epithelium of gastrointestinal organs (12). Alterations in the glycosylation of mucins have been described in cancer(13, 14). However, no comparative study has been found concerning MUC1 expression among normal, chronic inflammatory and cancer cells of the gallbladder. Therefore, we studied the status of MUC1 expression in normal gallbladder tissue, chronic cholecystitis (including

Xanthogranulomatous cholecystitis, which mimics cancerous tumors) and gallbladder cancers by immunohistochemistry.

3.3. MATERIALS AND METHODS

3.3.1. Tissue Specimen

We examined 88 surgical specimens of gallbladder cancer, 45 chronic cholecystitis specimens (including 7 Xanthogranulomatous cholecystitis (XGC)) and 5 normal gallbladder specimens obtained at the time of surgical treatment for gastrointestinal disease. Three pathologists, who are the co-authors of this study, independently performed pathologic evaluations of the specimens and disclosed the findings of their individual determinations.

For the 88 cancer specimens, the primary tumors T category have been classified according to T category in the TNM criteria (15) as follows: T1, Tumor invades lamina propria or muscle layer; T1a, Tumor invades lamina propria, T1b, Tumor invades muscle layer. T2: Tumor invades perimuscular connective tissue; no extension beyond serosa or into liver, T3: Tumor perforates the serosa (visceral peritoneum) and/or one other adjacent organ or structure, such as the stomach, duodenum, colon, or pancreas, omentum or extrahepatic bile ducts, T4: Tumor invades main portal vein or artery or invades multiple extrahepatic organs or structures. Out of the 88-gallbladder cancers, 14 tumors were T1, 15 were T2, 45 were T3 and the remaining 14 were T4.

3.3.2. Immunohistochemistry

All specimens were fixed in 10% formalin, embedded in paraffin, serially sectioned into 4 μm thick cuts and mounted on polysine coated slides. The slides were immersed for 20 min in 0.3% hydrogen peroxide in methanol to deplete the endogenous peroxidase. After washing, they were

incubated with a protein-blocking agent for 5 minutes. Primary antibodies against MUC1 core protein (monoclonal antibody, mouse anti-human CA 15-3, clone DF3 (IgG1, DAKO Corporation) were used at a dilution of 1:50. For the negative controls, the primary antibody was replaced with PBS. The slides were incubated with primary antibody in a humid chamber for 1 hour, washed with PBS for 15 minutes, and underwent changing of the buffer 3 times. Then, biotinylated secondary antibodies were applied for 10 minutes at room temperature. After washing, streptavidin peroxidase reagent was applied and the samples were incubated for 10 minutes at room temperature. Lastly, the slides were visualized by incubation within solution containing 0.3% hydrogen peroxide and diaminobenzidine tetrahydrochloride in PBS. Counterstaining was performed with haematoxylin, prior to mounting in crystal.

3.3.3. Evaluation of MUC1 core protein expression:

Three pathologists examined the expression of MUC1 core protein under a light microscope independently. The MUC1 core protein expression was judged as positive when more than 5% of cells were stained.

3.3.4. Statistics

Statistical analysis was conducted via the Chi-square test and p values of less than $p<0.05$ were regarded as significant.

3.4. RESULTS

3.4.1. MUC1 core protein expression among normal, inflammation and cancer cells:

MUC1 core protein expression in epithelium and cancer cells in the gallbladders was estimated separately in the lamina propria and the layers deeper than muscle layer, which consisted of the

muscle layer, perimuscular connective tissue and serosa. Two types of staining patterns were recognized: polarized and depolarized. In the polarized type, MUC1 expression is restricted predominantly in the apical membrane of the cell (Fig 3.1-3.4). In the depolarized type, the membrane and cytoplasm of the cell, as well as the stroma adjacent to the basal membrane of the malignant glands were stained (Fig 3.5).

In the normal gallbladder tissue, the expression rate of MUC1 was 20% (1/5) in the lamina propria, with a polarized staining pattern. There was no MUC1 expression in the layers deeper than muscle layer both in inflammations and normal gallbladder (Fig 3.1-3.3). In the chronic inflammatory gallbladder tissue, only 2 of 45 specimens (4.4%) expressed MUC1 in the lamina propria and the staining pattern was of the polarized type (Fig 3.2&3.3). There was no statistical difference in the rate and type of MUC1 core protein expression in the lamina propria and in the layers deeper than muscle layer between normal and chronic inflammation tissues.

On the other hand, in the gallbladder cancer, the lamina propria had a significantly ($p<0.0001$) higher expression of MUC1 - 78.4% (69/88) - than in non-cancerous (normal and chronic inflammation) epithelium (Table 3.1). The staining pattern of MUC1 core protein was exclusively of the polarized type in the lamina propria of the non-cancerous gallbladder epithelium. However, in the gallbladder cancer, both staining patterns were marked: 34.8% (24) for the polarized type and 65.2% (45) for the depolarized type. In 74 specimens with cancer cell invasion to the layers deeper than muscle layer (T2-T4), the MUC1 expressed in 89% (66/74) of them and 88% of MUC1 expressed specimens (58/66) showed depolarized type and only 12% (8/66) demonstrated polarised type.

3.4.2. MUC1 core protein expression in cancer with relation to histopathology

Tumor Differentiation: Eighty-two specimens were adenocarcinoma and two were adenosquamous carcinoma, while two showed signet ring cell carcinoma and the remaining two were mucinous carcinoma. Adenosquamous and mucinous carcinomas expressed MUC1 with a depolarized staining pattern, while the signet ring cells did not show MUC1 expression. Out of 88 carcinomas, 51 were classified as well differentiated, 21 were classified as moderately differentiated and 16 were classified as poorly differentiated carcinomas. The MUC1 expression rates in the cancer cells on the epithelial layer were as follows: 72% in well, 81% in moderate and 94% in poorly differentiated carcinomas, respectively. In the sub-mucosal layer, it was 86%, 90%, and 94% in well, moderate and poorly differentiated carcinomas, respectively. These results suggested no correlation in MUC1 expression rate and cancer differentiation. The depolarised type of MUC1 expression rates in the cancer cells on in the lamina propria was as follows: 39% in well, 57% in moderate and 81% in poorly differentiated carcinomas, respectively. In the deeper layer, it was 73%, 76%, 94% in well, moderate and poorly differentiated carcinomas; respectively. There is no significant correlation of MUC1 staining pattern with tumour differentiation.

T category: The MUC1 expression rate of 29% (4/14) in the epithelial layer of T1 tumors was significantly ($p<0.0001$) less than the rate noted in the advanced T categories; that is, 93% (14/15) in T2, 89% in T3 (40/45) and 79% in T4 tumors (11/14), respectively (Table3.2). All of the cells in the MUC1 core protein -positive T1 cancers displayed polarized staining. On the other hand, 87.6 % (57/65) and 80.3%(53/66) respectively in the epithelium and submucosal layer of the MUC1 core protein -expressing cancer cells in the advanced T categories -- T2 (14), T3 (40) and T4 (11) - had a depolarized pattern. In these advanced T categories, cancers

penetrating beyond the epithelial layer demonstrated very high MUC1 expression rates: as 100% (15/15), 84.4% (38/45) and 92.8% (13/14) in T2, T3 and T4, respectively. There is no correlation between the MUC1 expression rate and the staining pattern among T2, T3 and T4 tumors.

Lymphatic vessel invasion: Lymphatic vessel invasion was noted in 59 specimens of 74 advanced (T2-T4) cancer specimens. In these lymphatic vessel invasion positive specimens, MUC1 core protein expression rates are 89.8% (53/59) and 88.1% (52/59), respectively, in the epithelial and sub-mucosal layer. In the specimens where lymphatic vessel invasion is not present MUC1 expression rate was 93.3%(14/15) and 86.6%(13/15) in the epithelial and sub-mucosal layer, respectively. There is no correlation between MUC1 expression rate and lymphatic vessel invasion. Regarding to staining pattern, polarised type of expression rates were 24.5 %(13/53) and 9.6 %(5/52) respectively, in the epithelial and sub-mucosal layer. Depolarised type of expression rates were 75.5 %(40/53) and 90.4 %(47/52), respectively, in the epithelial and sub-mucosal layer (Table 3.3). Depolarised type of staining pattern is significantly high ($p<.005$) in epithelial and sub-mucosal layer where lymphatic vessel invasion is positive. In the specimens where lymphatic vessel invasion is negative polarised type of MUC1 staining pattern is 50% and 31% in epithelial and sub-mucosal layer respectively and depolarised type of staining pattern is 50% and 69% epithelial and sub-mucosal layer respectively. There is no correlation of MUC1 staining pattern where lymphatic vessel invasion is negative.

Venous invasion: Venous invasion was assessed in 74 advanced cancers (T2~T4) under the microscope and was noted in 32 specimens of these specimens. In these venous invasion-positive specimens, the mucin expression rates are 84% and 94 %, respectively, in the epithelial layer and in the sub-mucosal layer. In the specimens where there is no venous invasion, the mucin

expression rates are 77% and 86%, respectively. Therefore, the mucin expression rate has no relation to the degree or presence of venous invasion. But is in these venous invasion-positive specimens, depolarised type of expression rates are 63% and 88 %, respectively, in the epithelial layer and in the sub-mucosal layer. In the specimens where there is no venous invasion, the depolarised type of mucin expression rates is 47% and 71%, respectively. There is no significant correlation with depolarised type expression rate and venous invasion.

3.5. DISCUSSIONS

Despite the dismal prognosis of patients with gallbladder cancer, the relevance of biologic characteristics to clinical medicine has not fully studied. Recently, several reports pointed out that the expression of MUC1 may relate closely to prognosis in patients with gastrointestinal cancers (7, 16-18) and the greater the increase in expression the more the cells lose their apical polarity(19, 20). We also previously reported that the depolarised expression of MUC1 in gallbladder cancer would be a potential prognostic predictor (11) and Yamashita, et, al. demonstrated that MUC1 expression was significantly related to prognosis in patients with cholangiocarcinomas (10). MUC1 and its family of glycoproteins have been reported to regulate immune recognition(4), cellular adhesion of cancers (5) and cellular differentiation in breast cancer(21). However, the status of MUC1 core protein expression in gallbladder cancer compared to that of in normal tissue and inflammatory lesions have not been studied yet and it may lead to an improved understanding of the role of MUC1 in cancer biology. Therefore, an aim of this study was to clarify the significance of MUC1 core protein expression in cancerous and non-cancerous lesions of the gallbladder.

Our study revealed that the MUC1 core protein expression rate is significantly higher in cancer cells than in non-cancerous cells. The mechanism of high expression of MUC1 has been

studied in colon cancer and it has been observed that the activity of GalNAc transferases is increased in cancer, specifically within the rough endoplasmic reticulum (RER). O-glycosyltion usually occurs in golgibodies of normal cell, but Egea et al advocate that it occurred in the swollen RER in spite of golgibodies (22). Swelling of the RER may be responsible for cellular stress and neoplastic transformation. In gallbladder cancer, a similar mechanism may occur. We have seen that the depolarised staining pattern is dominant in cancer cells. Egea et al demonstrated in colon cancer that in typical cancers golgi stacks are not observed, probably due to the lack of polarization of the cells and the fact that mucus droplets are also distributed in a non-polarized fashion (22). This lack of polarization of the cells may be responsible for the depolarised expression of MUC1 noted in gallbladder cancer. Previous studies are there that GalNAc transferases activity vary with cellular differentiation and malignant transformations(23) and MUC1 expression also related with tumour differentiation and malignant transformation(24). In our study MUC1 expression is significantly lower in T1 than higher category (T2, T3, and T4) but no relation between T2, T3 and T4. Depolarized type of stainig pattern is significanty related with lymphatic vessel invasion in both epithelial and submucosal layer. Kashiwagi et al also demonstrated similar type of study (25). More over in our recent publications we have seen that MUC1 is highly expressed in our all 5-cell line and area containing MUC1 gene (1q21-q25) is gained in 3 out of 5 gallbladder cancer cell lines (26). These results support our hypothesis that MUC1 is related with gallbladder cancer invasion. And though there is no significant correlation of MUC1 expression rate with tumor differentiation and venous invasion. But depolarised expression is more in venous invasion positive cases and poorly differentiated cancer specimens. Further study may reveal its significance.

Xanthogranulomatous cholecystitis mimics gallbladder cancer clinically and radiologically (27). Interestingly, there is a significant difference in MUC1 expression and

staining pattern between XGC and cancer. However, we did not find any significant difference in MUC1 expression and the staining pattern between normal and XGC tissue. (Less than 5% cells are stained in XGC cases and the staining pattern is also polarized). So, from this study and also from our previous study of COX2 (28) expression in gallbladder tissue, we can say that XGC is not a pre-cancerous condition.

3.6. CONCLUSIONS

In conclusion, MUC1 core protein expression is significantly higher in gallbladder cancer than in normal and inflammatory gallbladder epithelium. In cancer cells, the depolarised staining pattern is dominant. MUC1 core protein expression is significantly low in T1 category than T2, T3 and T4. In our study lymphatic vessel invasion is significantly related with depolarized type of staining pattern in deeper layer. So we can say that MUC1 expression may be related with gallbladder cancer invasion. Based upon this study and the others referenced above, we further conclude that xanthogranulomatous cholecystitis may not be a pre-cancerous condition.

Legends

MUC1 expression detected by the immunoperoxidase method using DAB as a coloring agent (brownish pigment).

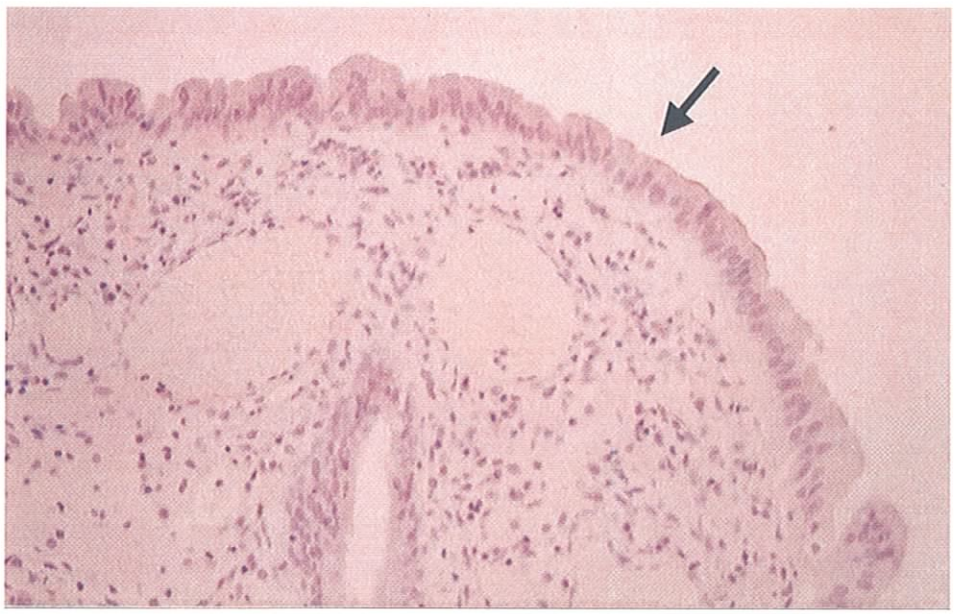

Fig3.1 Normal gallbladder (x33):
Less than 5% of epithelial cells (arrow) expressed MUC1 on the apical surface

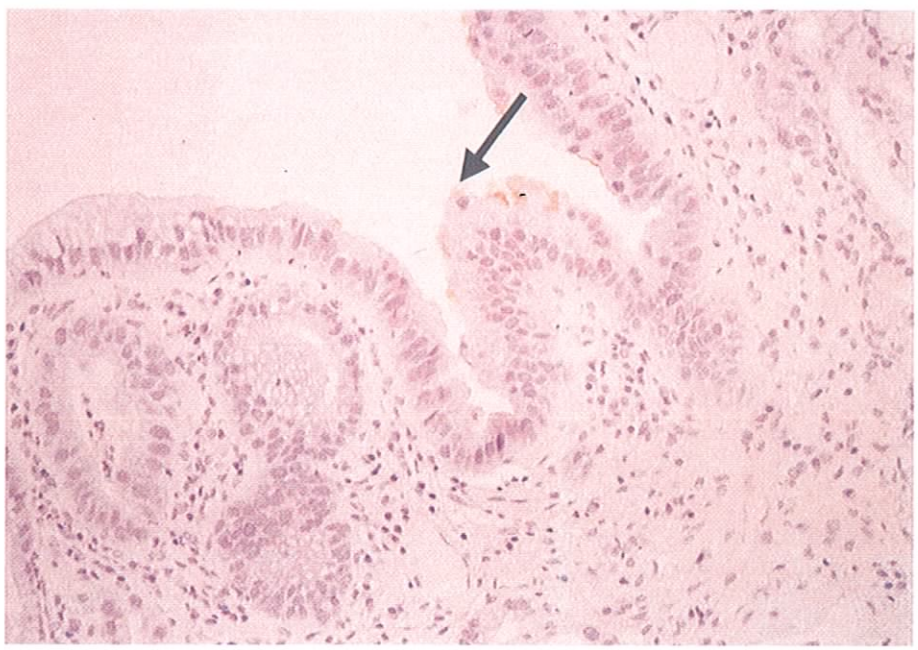

Fig.3.2 Chronic cholecystitis (x33):
Less than 5% of epithelial cells (arrow) expressed MUC1 in a polarized pattern

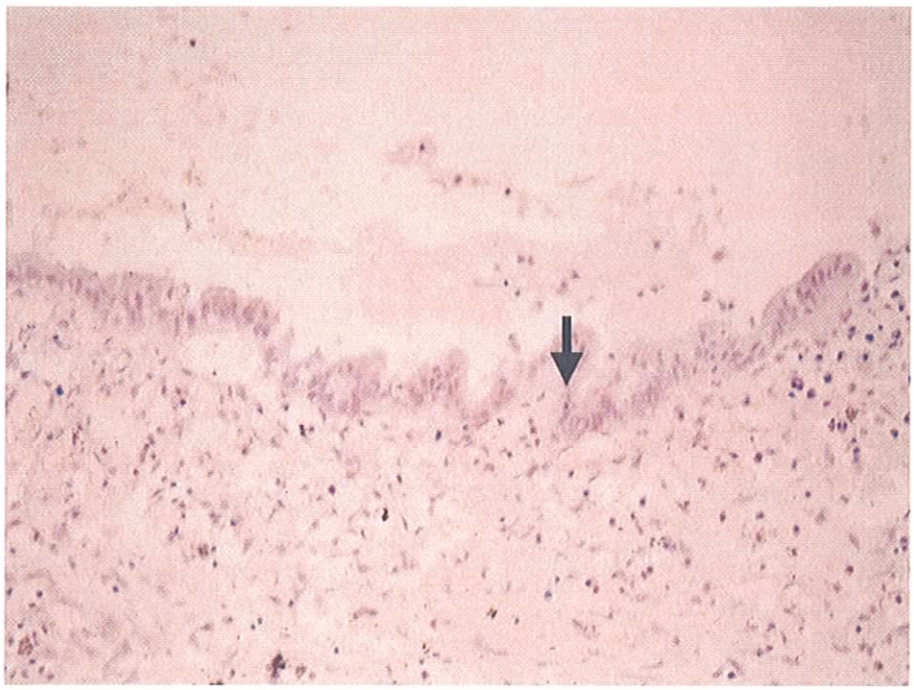

Fig3.3 Xanthogranulomatous cholecystitis (x33):
Less than 5% of the epithelial samples (arrow) expressed MUC1 in a polarized pattern.

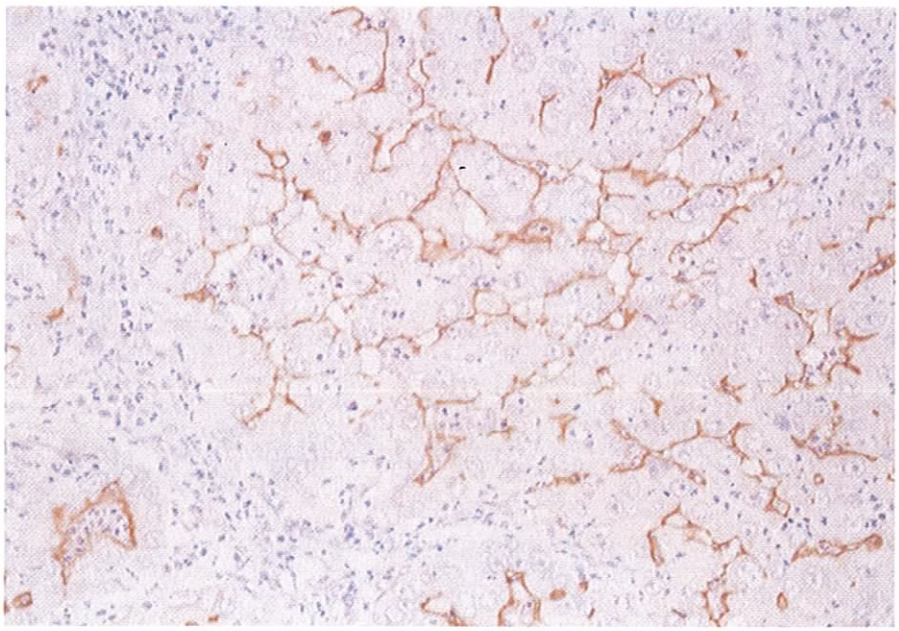

Fig 3.4 Well- differentiated adenocarcinoma (x33):
Cancer cells extensively expressed MUC1 in a polarized pattern

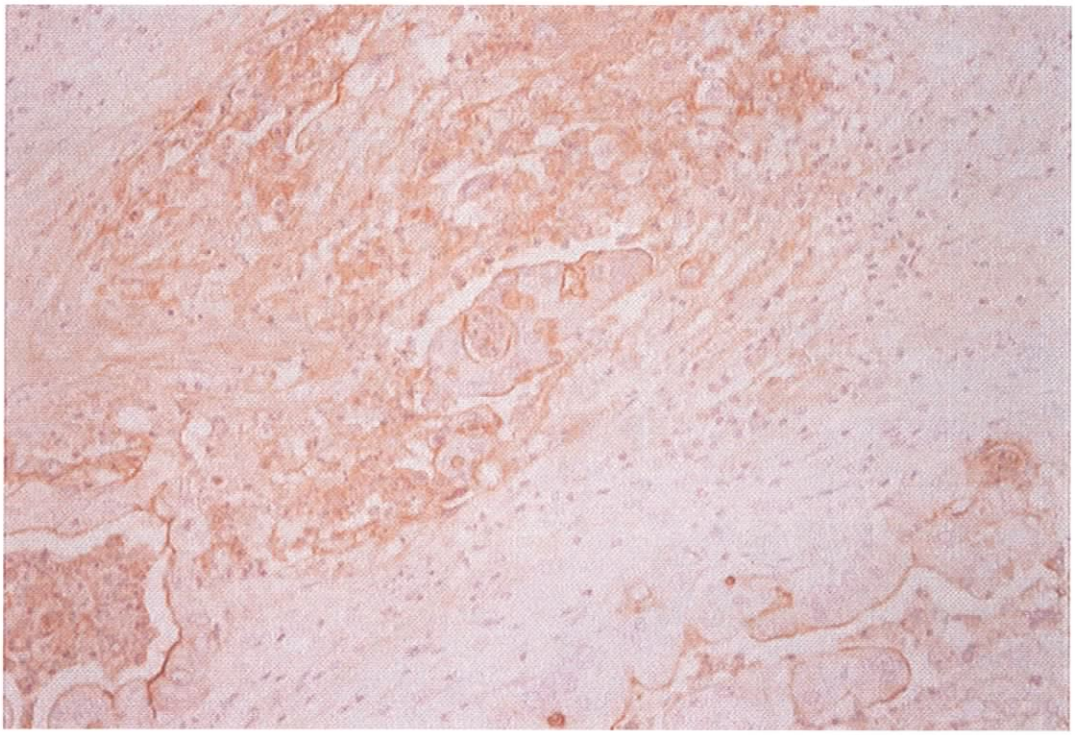

Fig3.5 Moderately differentiated carcinoma (x33):
MUC1 is expressed in the cytoplasm, as well as along the entire surface and within the stroma adjacent to the basal membrane (depolarized pattern)

Table3.1 MUC1 expression in different gallbladder tissues:

Different gallbladder tissue (No.of specimens)	Different Layer of the Gallbladder Wall	
	Mucosal	Submucosal
Cancer (88)	69/88(78%)	66/74 (89%)
Chronic Cholecystitis (45)	2/45 (4.4%)	0/45(0%)
Normal gallbladder (5)	1/5 (20%)	0/5(0%)

Chi square P<0.0001

Table3.2. The positive rate of MUC1 expression according to the T category

T category (No. of Patient)	The MUC1 Expression Rate (%) in the layer of gallbladder wall	
	Mucosal	Submucosal
T1 (14)	28.5 (4/14) [a]	40(2/5)[e]
T2 (15)	93.3 (14/15) [b]	100 (15/15) [f]
T3 (45)	88.8 (40/45) [c]	84.4 (38/45) [g]
T4 (14)	78.5 (11/14) [d]	92.8 (13/14) [h]

T category represents the extent of primary tumor invasion classified by TNM criterion.
a and e are significantly ($p<0.0001$) lower than b, c, d and f, g, h.

Table no 3.3. Mucin staining pattern in relation with Lymphatic vessel invasion.

Type of staining pattern	Percentage of Staining Pattern in Lymphatic Vessel Invasion Positive Tumors (n=53) in Layers	
	Mucosal (n=53)	Submucosal (n=52[a])
Polarized type	24.5%(13/53)	9.61%(5/52)
Depolarized type	75.47%(40/53)	90.38%(47/52)

The number of advanced tumour with MUC1 expression and lymphatic invasion positive is 53.
A: One tumour had not expressed MUC1 in the submucosal layer.
P value (Fisher"s exact test) = 0. 0005

3.7 REFERENCES

1. Abe, M. and Kufe, D. W. Identification of a family of high molecular weight tumour-associated glycoproteins. J Immunol, *139:* 257-261, 1987.
2. Abe, M. and Kufe, D. Structural analysis of the DF3 human breast carcinoma- associated protein. Cancer Res, *49:* 2834-2839, 1989.
3. Kufe, D., Inghirami, G., Abe, M., Hayes, D., Justi-wheeler, H., and Schlom, J. Differential reactivity of a novel monoclonal antibody (DF3) with human malignant versus benign breast tumors. Hybridoma, *3:* 223-232, 1984.
4. Hayes, D. F., Silberstein, D. S., Rodrique, S. W., and Kufe, D. W. DF3 antigen,a human epithelial cell mucin, inhibits adhesion of eosinophils to antibody coated targets. J Immunol, *145:* 962-970, 1990.
5. Lightenberg, M. J. L., Buijs, F., Vos, H. L., and Hilkens, J. Suppression of cellular aggregation by high levels of episialin. Cancer Res, *52:* 2318-2324, 1992.
6. Osako, M., Yonezawa, S., Siddiki, B., Huang, J., Ho, J. J. L., Kim, S. Y., and Sato, E. Immunohistochemical study of mucin carbohydrates and core proteins in human pancreatic tumours. Cancer, *71:* 2191-2199, 1992.
7. Baldus, S., Zirbes, T., Engel, S., Hanish, F., Monig, S., Lorenzen, J., Glossman, J., Fromm, S., Thiele, J., Pichlamaier, H., and Dienes, H. Correlation of the immunohistochemical reactivity of mucin peptide cores MUC1 and MUC2 with the histopathological subtype and prognosis of gastric carcinomas. Int J Cancer, *79:* 133-138, 1998.
8. Utsunomia, T., Yonezawa, S., Sakamoto, H., Kitamaru, H., Hokita, S., Aiko, T., Tanaka, S., Irimura, T., Kim, S., and Sato, E. Expression of MUC1 and MUC2 mucins in gastric carcinomas: Its relationship with the prognosis of the patients. Clin Can Res, *4:* 2605-2614, 1998.
9. Guddo, F., Giatromanolaki, A., Koukourakis, M., Reina, C., Vignola, A., Chlouverakis, G., Hilkens, J., Gatter, K., Harris, A., and Bonsignore, G. MUC1 (episialin) expression in non-small cell lung cancer is independent of EGFR AND c-erb-2 expression and correlates with poor survival in node positive patients. J Clin Pathol, *51:* 667-671, 1998.
10. Yamashita, K., Yonezawa, S., Tanaka, S., Shirahama, H., Sakoda, K., Imai, K., Xing, P., Mckenzie, I. F. C., Hilkens, J., Kim, S., and Sato, E. Immunohistochemical study of mucin carbohydrates and core proteins in hepatolithiasis and cholangiocarcinoma. Int. J. Cancer, *55:* 82-91, 1993.
11. Kawamoto, T., Shoda, J., Irimura, T., Miyahara, N., Furukawa, M., Ueda, T., Asano, T., Kano, M., Koike, N., Fukao, K., Tanaka, N., and Todoroki, T. Expression of MUC1 mucins in the subserosal layer correlates with postsurgical prognosis of pathological ttumour stage2 carcinoma of the gallbladder. Clin. cancer Res, *7:* 1333-1342, 2001.
12. Neutra, M. and Forstner, J. Gastrointestinal mucus:synthesis, secretion and function, p. 975-1009. New York: Raven, 1987.
13. Itzkowitz, S., Yuan, M., Montgomery, C., Kjeldsen, T., Takahashi, H., Bigbee, W., and Kim, Y. Expression of Tn, sialosyl-Tn and T antigens in human colon cancer. Cancer Res, *49:* 197-204, 1989.
14. Springer, G. T and Tn , general carcinoma autoantigens. Science, *224:* 1198-1206, 1984.
15. Greene, F., Page, D., and Fleming, I. AJCC Cancer staging Manual. *In*. Philadelphia-New York: Springer, 2002.

16. Utsunomia, T., Yonezawa, S., Sakamoto, H., Kitamaru, H., Hokita, S., Aiko, T., Tanaka, S., Irimura, T., Kim, S., and Sato, E. Expression of MUC1 and MUC2 mucins in gastric carcinomas: Its relationship with the prognosis of the patients. Clin. Can. Res, *4:* 2605-2614, 1998.
17. Symonds, D. A. and Vickery, A. L., Jr Mucinous carcinoma of the colon and rectum. Cancer (Philla), *37:* 1891-1900, 1976.
18. DeMascarel, A., Coindre, J. M., DeMascarel, I., Torjani, M., Maree, D., and Hoerni, B. The prognostic significance of specific histologic features of carcinoma of the colon and rectum. Surg. Gynecol. Obstet, *153:* 511-514, 1981.
19. Hilkens, J., Buijs, F., Hilgers, J., Hageman, P., Calafat, J., Sonnenberg, A., and Valk, M. V. Monoclonal antibodies against human milk-fat globule membranes detecting differentiation antigens of the mammary gland and its tumours. Int. J. Cancer, *34:* 197-206, 1984.
20. Zaretsky, J. Z., Weiss, M., Tsarfaty, I., Hareuveni, M., Wreschner, D. H., and Keydar, I. Expression of genes coding for pS2,c-erbB2, estrogen recepter and the H23 breast tumor-associated antigen. A comparative analysis in breast cancer. FEBS Lett, *265:* 46-50, 1990.
21. Lundy, J., Thor, A., Maenza, R., Schlom, J., Forouhar, M., Testa, M., and Kufe, D. Monoclonal antibody DF3 correlates with tumour differentiation and hormone receptor status in breast cancer patients. Breast Cancer Res Treat, *5:* 269-276, 1985.
22. Egea, G., Franci, C., Gambus, G., Lesuffleur, T., Zweibaum, A., and Real, F. cis-Golgi resident proteins and O-glycans are abnormally compartmentalized in the RER of colon cancer cells. Int.J Sci, *105:* 819-830, 1993.
23. Reis, C., David, L., Correa, P., Carneiro, F., Bolos, C., Garcia, E., Mandel, U., Clausen, H., and Sobrinho-simoes, M. Intestinal metaplasia of human stomach displays distinct patterns of mucin (MUC1, MUC2, MUC5AC, and MUC6) expression. Cancer Res, *59:* 1003-1007, 1999.
24. Boland, C. R., Montgomery, C. K., and Kim, Y. S. Alterations in human colonic mucin occuring with cellular differentiation and malignant transformation. Proc .Natl. Acad. USA, *79:* 2051-2055, 1982.
25. Kashiwagi, H., Kijima, H., Dowaki, S., Ohtani, Y., Tobita, K., Tsukui, M., Tanaka, Y., Matsubayasi, H., Tsuchida, T., Yamazaki, H., Nakamura, M., Ueyama, Y., Tanaka, M., Tajima, T., and Makuuchi, H. DF3 expression in human gallbladder carcinoma: significance for lymphatic invasion. Int J Oncol, *16:* 455-459, 2000.
26. Ghosh, M., Koike, N., Yanagimoto, G., Tsunoda, S., Kaul, S., Hirano, T., Emura, F., Kashiwagi, H., Kawamoto, T., Ohkohchi, N., Saijo, K., Ohno, T., Miwa, M., and Todoroki, T. Establishment and Characterisation of Human Unique gallbladder Cancer Cell Lines. Int J Oncology, *24:* 1189-1196, 2004.
27. Enomoto, T., Todoroki, T., Koike, N., Kawamoto, T., and Matsumoto, H. Xanthogranulomatous cholecystitis mimicking stage IV gallbladder cancer. Hepatogastroenterology, *Accepted*, 2003.
28. Ghosh, M., Kawamoto, T., Koike, N., Fukao, K., Yoshida, S., Kashiwagi, H., Kapoor, V., Agarwal, S., Krishnani, N., Uchida, K., Miwa, M., and Todoroki, T. Cyclooxygenase expression in the gallbladder, International Journal of Molecular Medicine. International Journal of Molecular Medicine, *6:* 527-532, 2000.

CHAPTER – 4

ESTABLISHMENT AND CHARACTERIZATION OF GALLBLADDER CANCER CELL LINES

4.1. ABSTRACT

Gallbladder cancer has a dismal prognosis. Understanding of the disease at the biological, genetic, molecular, cellular, and clinical level is essential for effective diagnostics and therapeutics. However, established gallbladder cells lines are still insufficient in number and also not well characterized for better understanding and further research. Establishment and characterization of human gallbladder cancer cell lines are the main aim of our present study. We have established five cell lines from resected specimens and metastatic sites of gallbladder cancers. These cell lines revealed typical histopathological characteristics of the tumour. We have examined growth characteristics and colony-forming ability of the established cell lines in terms of their cell cycle parameters and, expression of tumour markers like, Carcinoembryonic antigen (CEA), carbohydrate antigen Sialyl Lewis^{a} (CA19-9), and MUC1, oncogenes (c-kit and c-erbB2) by flowcytometer. Comparative genomic hybridisation (CGH) analysis was performed to detect changes in the gene copy numbers. Human origin of the cell lines was confirmed by chromosomal analysis. Cells maintained differentiation characteristics of the original tumours. Doubling time of different cell lines varied from 30 to 96 hrs. All cell lines formed colonies in the colony forming assays, expressed CEA, CA 19-9,MUC-1 and oncogene c-erbB2 tumour markers in their extra cellular domain. Cell cycle parameter showed chromosomal aneuploidy. CGH showed gain of chromosomal region

bearing MUC1, SRC, hTERT in gallbladder cell lines. These newly established cell lines might serve as a useful model for studying the molecular pathogenesis and testing new therapeutic reagents for gallbladder. These chromosomal aberrations and imbalances provide some starting points for molecular analyses of genomic regions and genes in gallbladder carcinogenesis.

4.2. INTRODUCTION

Gallbladder cancer has a very poor prognosis due to lack of characteristic signs and symptoms and frequent late diagnosis. For better therapeutics, in-depth study and knowledge of biological characteristics of the disease is required. These often require *in vitro* models of the disease and establishment of tumor derived cell lines. So far, only a few gallbladder carcinoma cell lines are available in the literature (1-5).

We have established five gallbladder carcinoma cell lines designated as TGBC1, TGBC24, and TGBC44 from metastatic sites and TGBC2, TGBC14 from primary sites. Here we report biologic and genetic characteristics of the 5 cell lines for expected contribution to studies on pathogenesis and new therapeutics of the gallbladder cancer.

4.3. MATERIALS & METHODS

4.3.1. Cell culture: Cell lines were established from pathologically proven gallbladder carcinomas samples of Japanese patients. Solid tumours obtained under sterile conditions from the tumor were washed and cut into small pieces in phosphate buffer saline (PBS) supplemented with 100U/ml penicillin and 100 μg/ml streptomycin (Invitrogen Japan, Tokyo, Japan). Ascites obtained from tumor bearing patients was centrifuged (1000 rpm, 5 min at 4^0C) and removed supernatant. These small tissue fragments and cell aggregate were subcutaneously inoculated into back of 6-week old nude mice (BALB/c nu/nu. Clea Japan

Inc.,Osaka,Japan). After passing 3-4 generations in the nude mice when the final tumor sizes became approximately $1cm^3$, we removed the tumor from the mice, finely cut into pieces, wash in PBS with antibiotics and centrifuged (1000 rpm, 5 min at 4^0C). The pellet suspended in 10 ml of PBS containing 0.25% trypsin was incubated in a 37^0 C for 10 min. Thereafter, fragments were filtrated through a 100 μm pore mesh to remove undigested tissue, the cell suspension was centrifuged (1000 rpm, 5 min at 4^0C), resuspended in growth medium (Dulbecco ' s modified Eagle medium, DMEM) (Nissui Seiyaku Co, Tokyo, Japan) supplemented with 10% heat inactivated fetal bovine serum (FBS, Iwaki Glass Co., Tokyo, Japan) and seeded into 24 well tissue plates.

4.3.2. Morphology

Original tumour paraffin sections and subcutaneous tumor after inoculation under skin were stained with haematoxylin and eosin and observed under microscope (Olympus, Tokyo, Japan). *In vitro* morphology of the cultured cells was observed every day under phase contrast microscope (Olympus). For electron microscopy, 10^6 cells of each cell lines were cultured in a plastic dish and fixed with 2% gluteraldehyde (pH 7.4), post fixed in 1% OsO_4 in the same buffer and embedded in Epon after dehydration in graded alcohol.

4.3.3. Growth properties

To determine population-doubling time, $5x10^4$ or 10 x 10^4 cells are seeded in to 35 mm dish. The number of the cells was counted for every alternate day till 15th day from four dishes. Culture was fed every 3-4 days. The cell viability was checked by dye exclusion test using 0.4% trypan blue and the number of the viable cells was counted under a phase contrast microscope using haemocytometer.

4.3.4. Ability of colony and tumour formation

For colony formation, in each experiment 10 dishes of 1ml of 1.5 x10^4 cells were irradiated with 50 Gy X-ray. Then 100 or 200 intact cells in 1ml were added in each dish and cultured for 2 weeks. Number of colonies was counted after staining with crystal violet. For estimation of tumour formation ability, 1~5 x 10^7 cells were injected in the right thigh of five-week-old nude mice (Balb/c nu/nu).

4.3.5. Expression of Tumour marker and oncogene

Cell surface tumour markers were analysed by flow cytometry using FACScan (Becton Dickinson, Mountain View, CA). The mouse monoclonal antibody 116NS19-9, directly against the carbohydrate antigen (CA19-9) (Dakocytomation Co. Ltd., Kyoto, Japan), a monoclonal antibody II-7 directly against carcinoembryonic antigen (CEA)(Dakocytomation), l FITC conjugated monoclonal antibodies HMPIV and 9G6, directly against MUC-1 and c-erbB2 respectively (BD bioscience, Tokyo, Japan) and a FITC conjugated monoclonal antibody 104D2, directly against c-kit were used. Cells were harvested in 6-cm dishes and separated by scraper. After washing with PBS, all cells were incubated with respective monoclonal antibodies in 4°C for 15 minutes, Cells incubated with HMPIV, 9G6 and 104D2 were directly analysed with FACScan. Cells incubated with other monoclonal antibodies were washed with PBS again and stained with FITC −conjugated secondary antibodies and incubated again at 4^0C for 10 min. After the incubation, cells were washed with PBS and analysed with FACScan. Results were compared with negative controls revealed the staining of the cell lines with FITC conjugated secondary antibody without primary antibody or IgG1 alone. KMBC cell line used for the positive control for CA19-9 (6), MKN -45 cell line was used as a positive control for CEA (7), Mz-Cha-1 cell line for MUC1 (8), MDA-MB 453 cell line for c-erbB2 (9) and HEL cell line for c-kit (10).

4.3.6. Chromosomal Analysis

G banding method was used for chromosomal analysis (11).

4.3.7. Cell Cycle Parameter Analysis

Cultured cells ($1x10^6$) at passage 60 and normal lymphocytes, which were used as a control for the diploidy (2n), were fixed with 70% ethanol supplemented with 0.5% RNAse to remove all RNA. The DNA content of the nuclei was analysed using propidium iodide stain and FACScan (Becton Dickinson).

4.3.8. Radioimmunoassay

Forty-six hours after culturing of cells, the number of cells and the volume of the spent medium were measured. The concentration of tumour markers (CEA and CA19-9) per one ml of the spent medium was measured by radioimmunoassay with a RIA kits (referred by SRL inc., Hachiogi in Tokyo Japan).

4.3.9. Comparative Genomic Hybridization (CGH) Analysis

High molecular weight DNA was extracted from the 5 cell lines and normal reference DNA from blood lymphocytes of healthy volunteers by agglutination partition method (Sepagene®, Sanko Junyaku Co., Ltd., Tokyo, Japan). CGH analysis was performed according to the procedure described by Kusano et al (12).

CGH Analysis. High molecular weight DNA was extracted from the 8 cells (TGBC, TBCN) and control DNA from blood lymphocytes of healthy volunteers by agglutination partition method (Sepagene®, Sanko Junyaku Co., Ltd., Tokyo, Japan).

CGH analysis was performed according to the procedure described by Kallioniemi et

al. (1994), with some modifications. Briefly, DNA extracts from tumor cells and control normal cells were labeled with SpectrumGreen-dUTP and SpectrumRed-dUTP (Vysis Inc., Downers Grove, IL) by nick translation, respectively. Each labeled DNA sample and Cot-1 DNA (Gibco Life Technologies, Gaithersburg, MD) were dissolved in 10 μl of hybridization buffer containing 50% v/v formamide, 10% w/v dextran sulfate, and 2×SSC (standard sodium citrate buffer), pH 7. Slides containing normal metaphase chromosomes were denatured in 70% formamide/2×SSC, pH 7 at 70°C for 110 seconds. The hybridization was performed in a humid chamber for 72 hours at 37℃. After hybridization, the slides were washed for 7.5 min in 50% formamide/2×SSC, pH 7 (3 times) and 2×SSC, pH 7 at 45°C and for 7.5 min in PN Buffer (PN: 0.1 M sodium phosphate, 0.1% nonidet p40, pH 8) and finally for 7.5 min in distilled water at room temperature. The specimens were mounted in an anti-fade solution containing 0.125 mg/ml 4',6-diamino-2-phenylindole as a counterstain. Images were captured with a 100 X Plan-APOCHROMAT objective and a CCD camera (C5985, HAMAMATSU PHOTONICS K.K., Hamamatsu, Japan). The digital image analysis system (isis ver. 3.4.5, Carl Zeiss Vision Co., Ltd., Tokyo, Japan) developed for CGH was used in this experiment. At least 10 representative images were analyzed, and the results from these were combined to produce an average fluorescence ratio for each chromosome. Increases and decreases in DNA sequence copy number were defined by tumor/reference ratios of greater than 1.2 and less than 0.8, respectively. Each CGH experiment included a normal SpectrumRed-labeled DNA sample from a healthy man as a negative control, and a SpectrumGreen-labeled MPE-600 breast cancer cell line DNA sample as a positive control. The cut-off values described earlier were determined from the negative control hybridizations as well as from positive specimens.

4.4. RESULTS

4.4.1. Morphology

Amongst our established five cell lines, TGBC-1 and TGBC-2 were derived from a lymph node and the primary lesion of a well differentiated and partly poorly differentiated adenocarcinoma of the gallbladder, respectively (Fig4.1A, 4.2A). TGBC-14 was taken from the primary tumor consisted mainly of anaplastic and partly adenosquamous carcinoma cells (Fig4.3A). TGBC-44 and TGBC-24 were from metastatic lymph nodes and ascites of patients with adenosquamous gallbladder carcinoma containing poorly differentiated adenocarcinoma component, respectively (Fig 4.4A, 4.5A) (Table4.1). Established cell lines grew as an adherent monolayer with characteristic epithelial morphology (Fig.4.1~4.5). TGBC1, TGBC 2 and TGBC24 had predominantly spherical or fusiform morphologies on the culture dish (Fig 4.1B, 4.2B, 4.4B). TGBC14 had polygonal morphology having large nuclei (Fig4.3B). TGBC44 had spindle or spherical morphology and grow as monolayer and partly formed as grape like clusters (Fig4.5B). The cultured cells maintained consistent morphology from the primary culture to the following subculture passages. Cells have grown continuously for more than 60 passages to-date. Transmission electron micrographs showed formation of microvilli, tight junction, cytoplasm containing desmosome, mucin particle and abundant of microfilaments in the cell lines (Fig4.6).

4.4.2. Growth Characteristics

Mean population doubling time ($\pm$SD; standard deviation) in the exponentially growing phase was 40$\pm$0.2, 37$\pm$0.2, 94 $\pm$0.1, 34$\pm$0.2 and 28$\pm$0.2 hours for TGBC1, TGBC2, TGBC14, TGBC24 and TGBC44, respectively (Table 4.1). DNA histogram analysis using flow cytometry (Fig 4.7) revealed that all the cell lines are aneuploid with the DNA index that varies from 1.25 to 1.50 (Table 4.2).

4.4.3. Colony and tumour formation assays

Every cell line formed colony as shown in Table 4.3 and formed tumours in nude mouse but TGBC-14. The tumor formation ability in nude mice was not tested for TGBC-14, because of its very slow growth rate in the dish. We have developed a xenograft model of TGBC-44 in nude mouse (13).

4.4.4. Expression tumor markers and Oncogene

The flow cytometry using FACScan revealed that all the five cell lines expressed CEA, CA19-9 in their extra cellular domain. The CEA levels in the spent medium were less than measurement limits (0.5ng/ml) for TGBC-1, TGBC-2 and TGBC-44, but those for TGBC-14 and TGBC-24 were 15.3 and 1.6 ng/ml, respectively. Regarding to the level of CA19-9, all the 5-cell lines were less than measurement limit (6U/ml), but 28 U/ml for TGBC-44 (Table 4. 1). The flow cytometry analysis also demonstrated that on the cell surface of all the 5-cell lines MUC1 was highly expressed and cerbB2 was very little, but c-kit was not detected.

4.4.5. Chromosomal Analysis and Comparative Genomic Hybridization (CGH)

There are gain, loss, translocation, derivative chromosomes and other abnormalities. However no clearly typical marker chromosome was found in the five cell lines except that 5_P was gained in 4 out of 5 cell lines (Fig.4.8) shows a representative karyotype of TGBC-24.

CGH revealed genetic copy-number aberrations in different points (Table 4.4). We have found gain of 1q21 (MUC1 region)- in 3 cell lines, 1q21-25(Cox2-region) in 3 cell lines, 1q41(transforming growth factor beta-2-region) in 3 cell lines, 5_P12 (Pancreatitis associated protein region) in 3 cell lines, 2q14-q21(RAB 6 region)- in 4 cell lines, 6p12(VEGF region) in 3 cell lines, 6p 21.3 (TNFA region) in 3 cell lines, 7q21 (MDR1 region) in 4 cell lines, 7q31

(MET region) in 4 cell lines, 12_P (Ras region) in 4 cell lines, 17q (cerbB2 region) in 3 cell lines, 8q24 (c Myc region) in 3 cell lines, 7p12 (EGFR region) in 4 cell lines, 5p15(human telomerase, hTERT region) in 4 cell lines, CEA-19q13.2 in 3 cell lines, AKT2 gene 19q13.1 in 3 cell lines and also 20q gain in 5 cell lines, loss of 21q21 in 3 cell lines. 5q21-APC is lost in TGBC 14 but not gained anywhere. 9p21 lost in TGBC1. 12q14-CDK4 gained in 2 cell lines, 17p13.1 p53 gained in TGBC-14, TGBC-1, and TGBC-2. 18q21.3 (DPC4) lost in TGBC-14 but gained in TGBC2. But as-a-whole- gained portions were more than lost portion. 4q12 (C KIT) was not gained and we did not find c-kit expression in our cell lines. CA19-9 (CD77)-22q11.2-13

4.5. DISCUSSIONS

Different profiles of chromosomal copy-number abnormalities have been revealed in our gallbladder cancer cell lines. Because the chromosomal regions of copy number gains nd losses often found in tumor genomes are suggested to be important for the characteristics of the tumour, we focused on the overlapped chromosomal abnormalities which were found in > 3 out of 5 TGBC cell lines in this study. There is the possibility of existence of oncogenes related with the development of gallbladder cancer in the regions of chromosomal amplifications. Amplification of 3q26-qter was observed in TGBC14, TGBC24 and TGBC44 cells, whereas amplification of 5P was observed in TGBC1 and TGBC2 cells. These regions are known to contain the genes HTR (RNA component of human telomerase, 3q21-28) and HTERT (catalytic component of human telomerase, 5p15), respectively. 5p15 is hTERT has been implicated in human cell immortalization and cancer cell pathogenesis (14). Gain of 5p was the most frequent chromosomal aberration in gallbladder (15). Copy number increase of this gene has been also observed in other cancers such as breast (16) gastric and colon (17). In our cell lines amplifications and gain of 5P14-qter is gained in 4 out of 5 gallbladder cancer

cell lines. These results indicate that the copy number increases of telomerase related genes play an important role in TGBC gallbladder tumors. The amplifications or copy number gain of 17q21-23 and 8q23-qter were found in TGBC24, TGBC44 and TGBC2. Oncogenes ERBB2 (17q21) and MYC (8q24) are mapped in these regions and they are known to be often amplified in various types of tumors. It has been reported that ERBB2 may play an important role in gallbladder carcinogenesis (18). The biological behaviours of TGBC2, TGBC24 and TGBC44 are also considered to be influenced by these oncogenes.

Cancer of the biliary tract has been understood to associated with point mutations of K-ras aproto-oncogenes and alterations of APC and p16, and DPC4 tumor suppressor genes by a combination of chromosomal deletion, mutation, or methylation; and infrequently microsatellite instability (19). Mutations of $p16^{Ink4}$ /CDKN2 and $p15^{Ink4B}$/ MTS2 in biliary tract cancers (20) is already reported. By CGH analysis of TGBC cells, chromosomal gain of 12p12(KRAS2 locus) was observed in 4 out of 5 TGBC cell lines. The loss of 9p21(CDKN2 locus) in TGBC1 and the loss of 5q21 (APC region) in TGBC14 cell line were observed (data not shown). Therefore, contribution of copy number changes in K-ras, CDKN2 and APC to character of TGBC1, TGBC2, and TGBC24 TGBC44 cells is suggested.

Both copy number increases of 1q41-qter and 6p12-21 were found in TGBC1, TGBC24 and TGBC44, which are derived from the metastatic sites of primary gallbladder cancer. No changes in these regions were found in TGBC-2 and TGBC14 , which are derived from the primary site. The 1q41-qter and 6p12-21 regions contain TGFβ2 (1q41) and VEGF (6p12) genes. VEGF is known as one of the most major angiogenic factors. Whereas, it is reported that the expression of TGFβ2 increases according to cancer progression and it strongly influences angiogenesis and macrophase infiltration into the tumor TGFβ2 (21). Therefore, the gains or amplifications of 1q41-qter and 6p21-21 may relate to the metastatic and malignant characteristics of these 3 cell lines, TGBC1, TGBC24, and TGBC44.

Region 19q showed gains in 3 cell lines. The AKT2 gene has been reported to be amplified and over expressed in ovarian (22) breast cancer (23). All 5 of our cell lines have gains of 2p(PAP and RAB1 region) and 20q. The 20q gain is common in pancreatic cancer (24). Whereas, the chromosomal loss of 3p12-13 was observed in TGBC1, TGBC2 and TGBC14.

Our present cell lines are from primary and metastatic lesion of the biliary tract cancer. Besides the difference from the genetic studies like karyotype and CGH of our cell lines from primary and metastatic sites of the same tumour, we found no other essential difference when compared to previously reported cell lines.

4.6. CONCLUSIONS

In conclusion, we state that our highly characterized cell lines will be effective tool for gallbladder cancer research. Chromosomal aberrations and imbalances provide some starting points for molecular analyses of genomic regions that may harbor genes of pathogenesis importance in gallbladder carcinogenesis. Numerous genetic variability of gallbladder cancer revealed in this study supports the idea that accumulation of genetic changes is important for tumour progression.

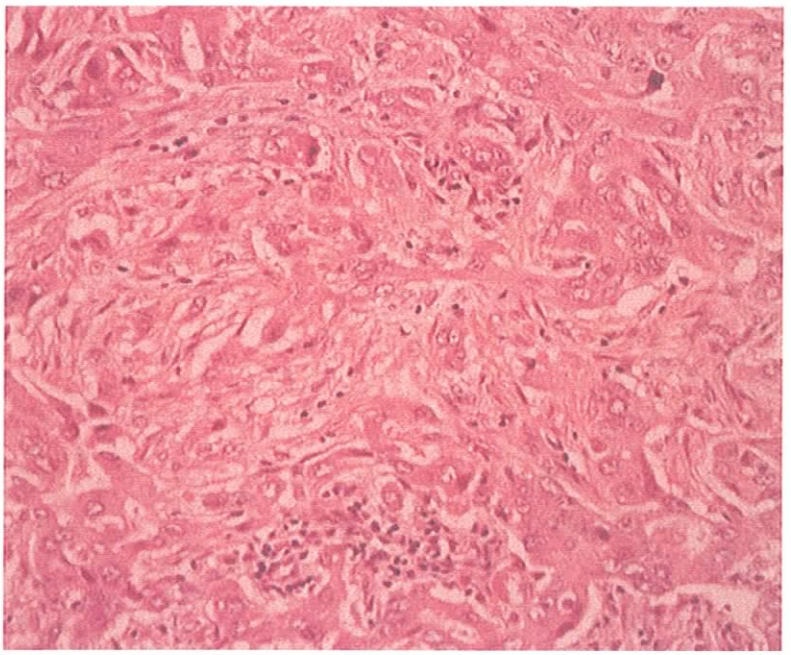

Fig.4.1A Microphotograph of lymph node metastasis derived from a tumor consisted of well differentiated partly poorly differentiated gallbladder carcinoma (x20)

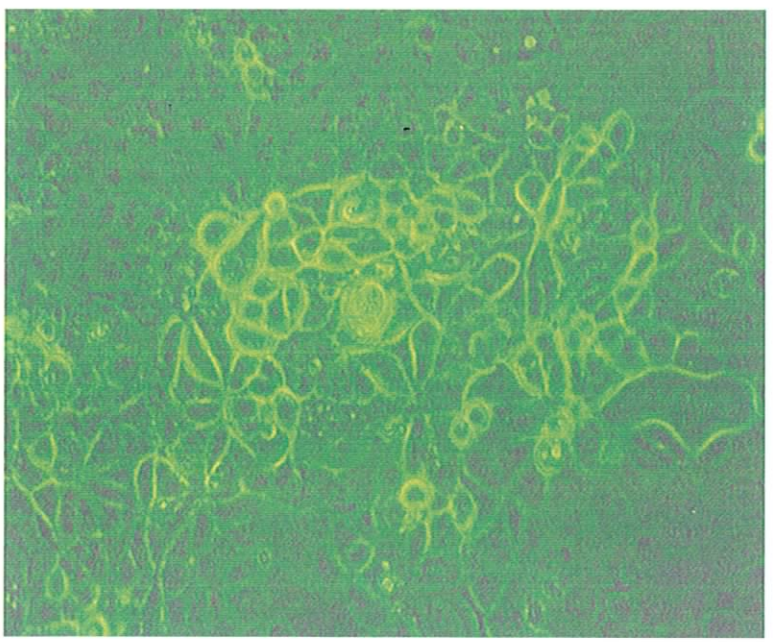

Fig. 4.1B Phase contrast microphotograph (H-E; x400) of TGBC-1 cells in a Petri dish, which was established from the tumor of Fig. 4.1A

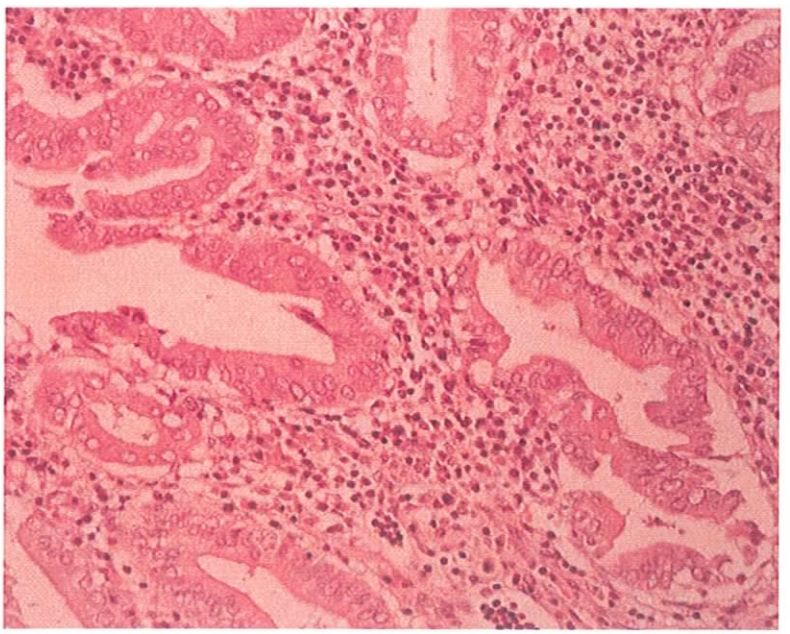

Fig. 4.2A Microphotograph of the primary gallbladder cancer consisted of well-differentiated partly poorly differentiated carcinoma cells (x20)

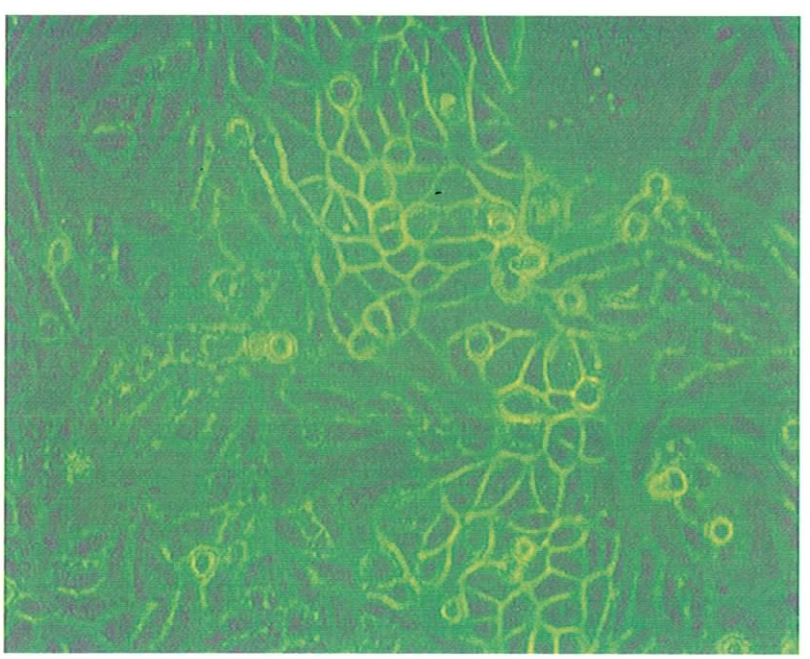

Fig 4.2B Phase contrast microphotograph (H-E; x400) of TGBC-2 cells, which was established from the tumor of Fig. 4.2A

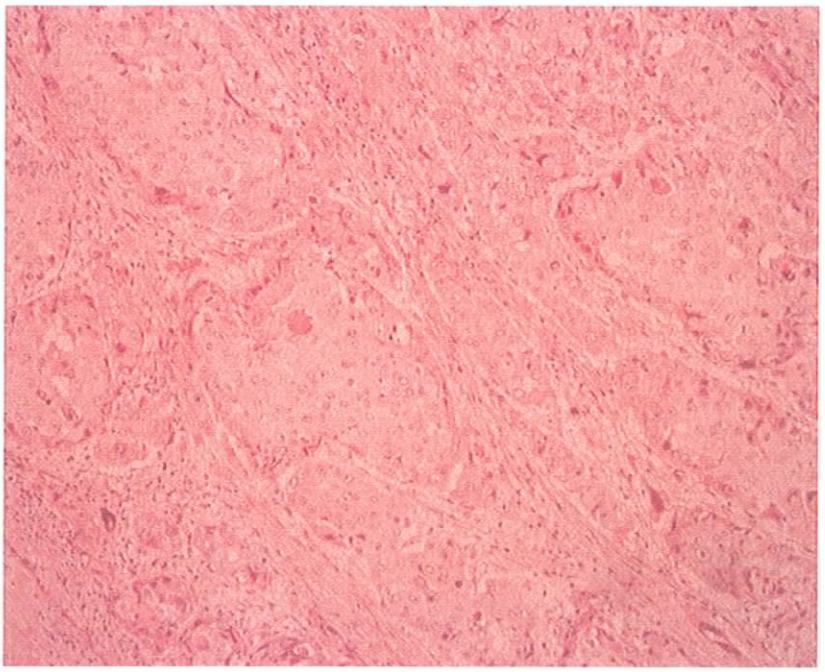

Fig.4.3A Microphotograph of the primary gallbladder cancer consisted of adenosquamous partly anaplastic carcinoma cells (x20)

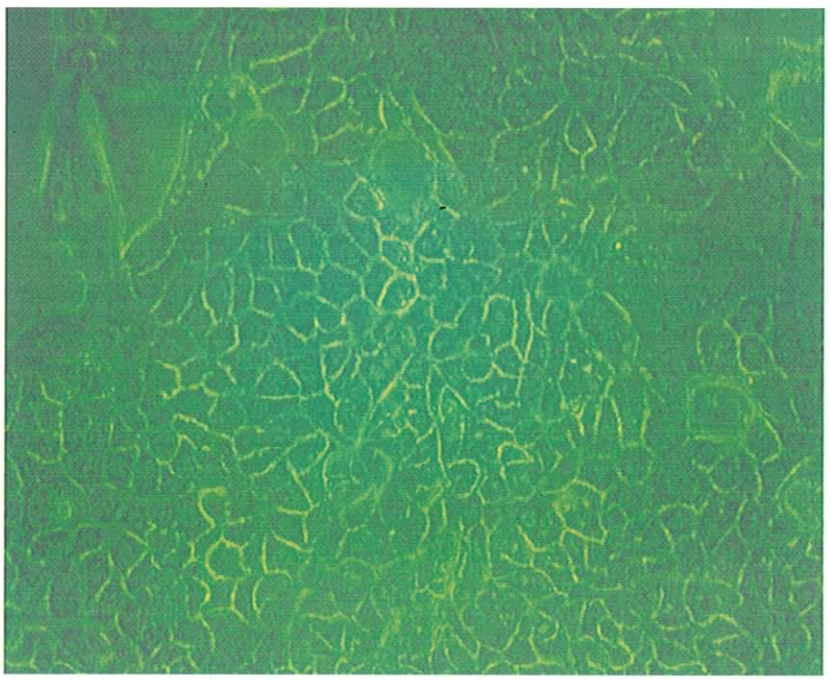

Fig. 4.3B Phase contrast microphotograph (H-E; x400) of TGBC-14 cell line, which was established from the tumor of Fig. 4.3A

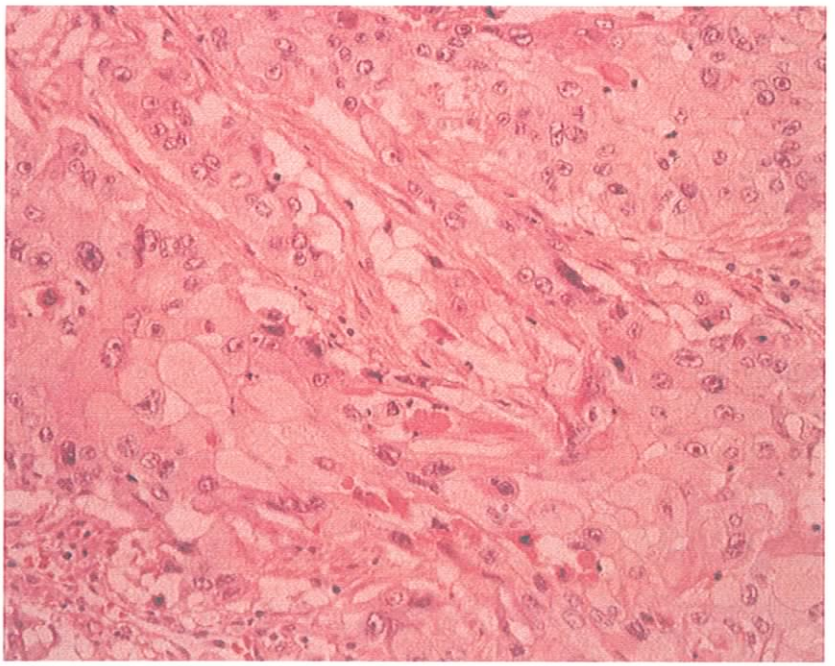

Fig. 4.4A Microphotograph of the primary gallbladder cancer consisted of adenosquamous partly poorly differentiated carcinoma cells (x20)

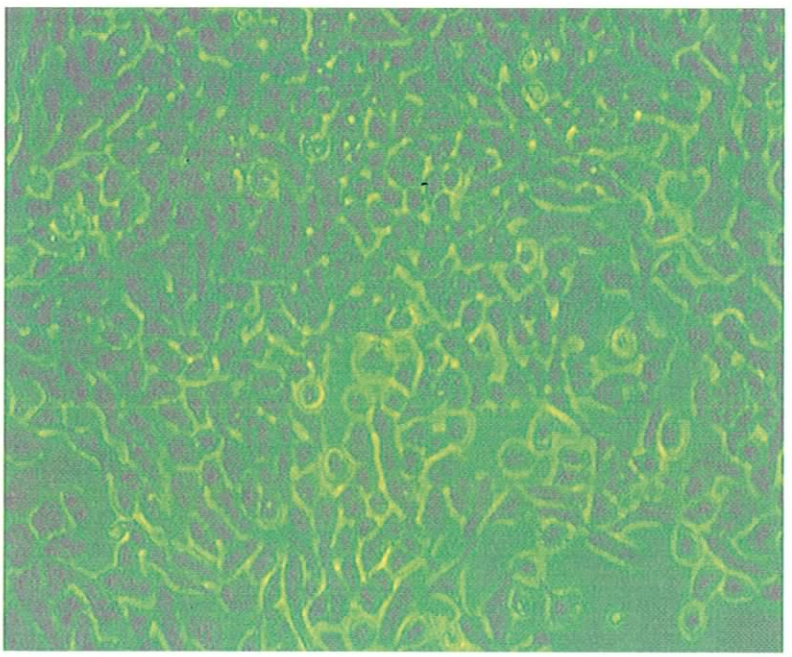

Fig. 4.4B Phase contrast microphotograph (H-E; x400) of TGBC-24 cell line, which was established from cells of ascites derived from the tumor of Fig. 4.4A

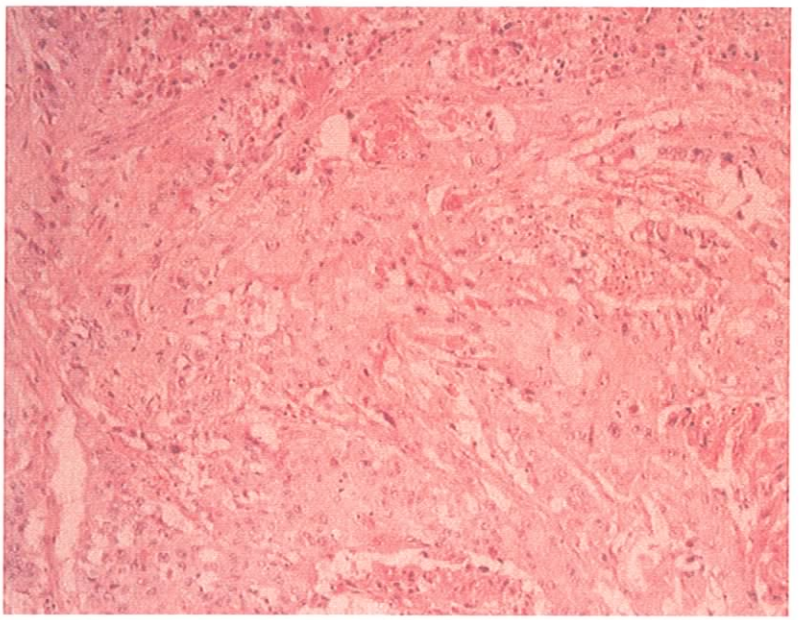

Fig. 4.5A Microphotograph of lymph node metastasis from the gallbladder cancer consisted of adenosquamous partly poorly differentiated carcinoma cells (x20)

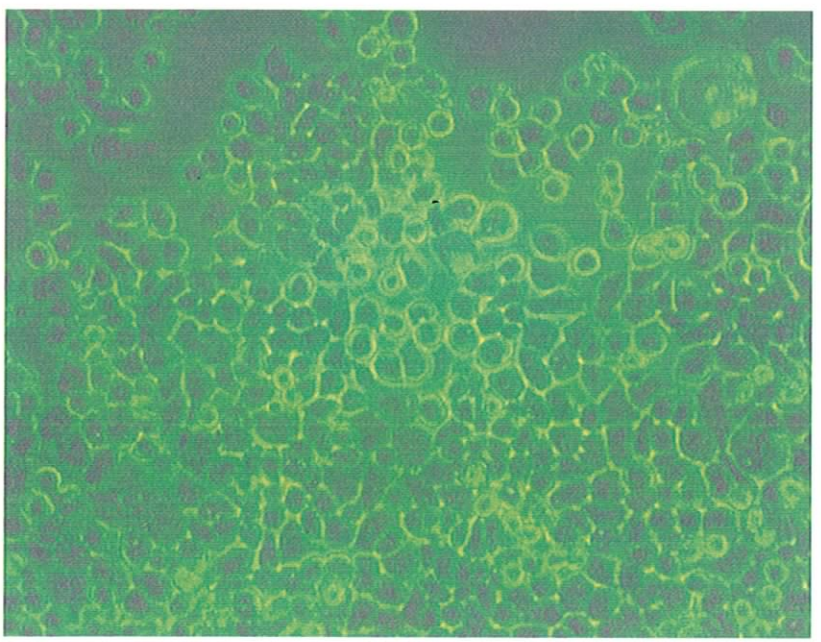

Fig. 4.5B Phase contrast microphotograph (H-E; x400) of TGBC-44 cell line, which was established from cells of tumor of Fig. 4.5A

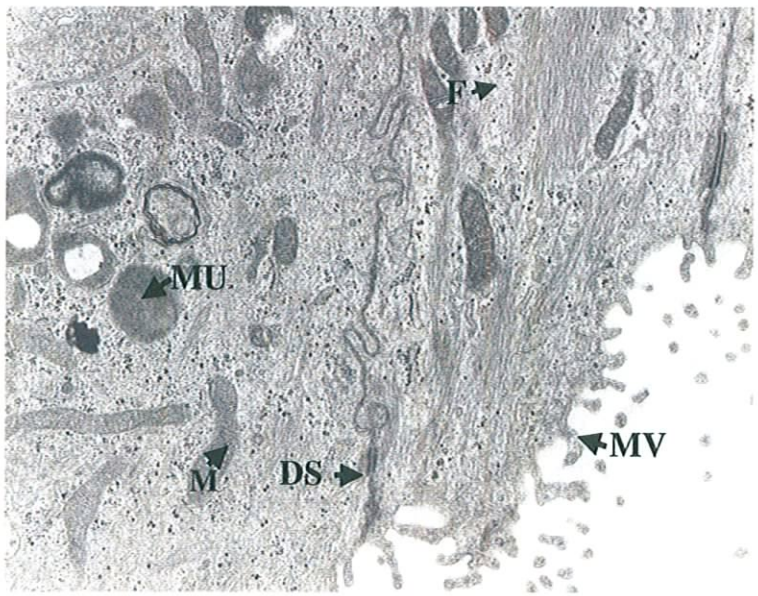

Fig. 4.6 Electron micrograph of TGBC-1 cell shows well differentiated adenocarcinoma with microvilli (MV), mitochondria (M), tight junction (TJ), mucin (MU), bridge formation, cytokeratin (C), Golgibodies (GB), lysosome (L)

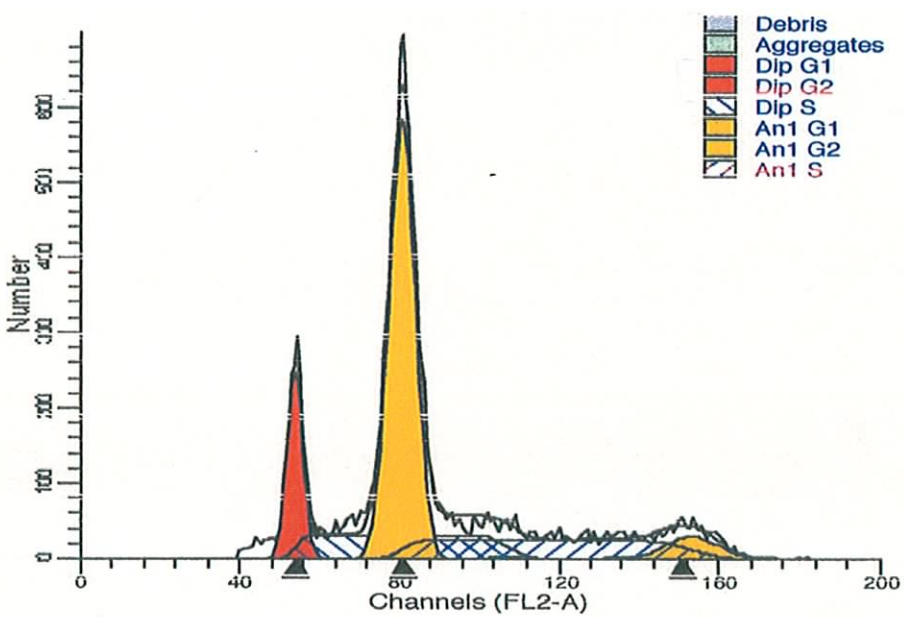

Fig. 4.7 DNA histogram of TGBC-44 cells shows an aneuploid DNA pattern

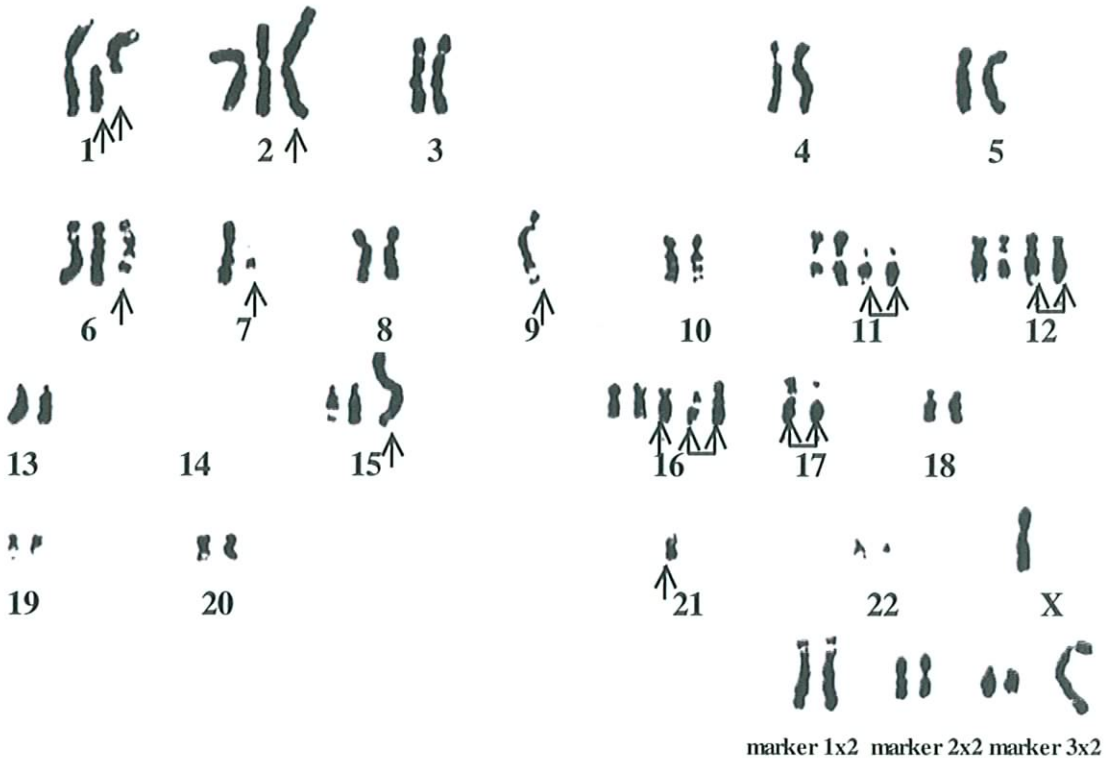

Fig. 4.8 Representative karyotype of TGBC-24 shows the chromosomal changes.
55-60<3n>, X, -X [10], -X [10], del (1) (p11)[10], del (1) (q21)[10], der (2) t (1; 2)(q24; p23)[10], -3[10], add (3), (q25)[3], -4[10], -5[10], i (6)(p10)[10], -7[7], add (7), (q11)[10], -8[10], -9[10], -9[4], der (9) t (9; 15) (q13; q11) ins (9;?)(q 13;?)[10], der (9) t (9:15) ins, (9;?)[6], -10[10], -10[4], +11[9], del (11)(p11)[10], del (11)[9], + 12[6], del (12)(p?)[8], del (12)[6], -13[10], -13[4], -14[10], -14[10], -14[10], -14[10], -15[6], der (15) t (15; 15)(p11; q11) ins (15;?)(p 11; ?)[3], +16[10], +add (16)(q24)[7], add (16)(q12) x2 [10], -17[10], add (17)(q21) x 2[10], -18[10], -19[10], -20[10], -21[10],
-21[10], add (21)(p11)[10], -22[10], +mar1x2 [10], mar2x2 [10], mar3 [10], mar3 [7], +1- 4mar

Table 4.1. Characteristics of Established Cell Lines

	TGBC-1	TGBC-2	TGBC-14	TGBC-24	TGBC-44
Original tissues	LN	PT	PT	Ascites	LN
Histologic type	W/P	W/P	ADS/ANA	ADS/P	ADS/P
Tumorigenesis in nude mice	Yes	Yes	Not tested	Yes	Yes
A mean PDT (hours)	40	37	94	34	28
CEA (ng/ml)	<0.5	<0.5	15.3	1.6	0.5
CA19-9 (U/ml)	<6	<6	<6	<6	28

LN: Lymph node metastasis, PT: Primary tumor, W: Well differentiated, P: Poorly differentiated. ADS: Adenosquamous, ANA: Anaplastic, PDT: Population doubling time (hours), CEA: Carcinoembryonic antigen, CA19-9: Carbohydrate antigen (Sialyl Lewis[a])

Table 4. 2. Cell Cycle Parameters

Cell lines	DNA Index	Cell Cycle Phase			CV
		G0/G1	S	G2/M	
TGBC1	1.41	70.09%	20.53%	2.0%	6.9
TGBC2	1.25	46.58%	51.19%	2%	5.07
TGBC14	1.47	68.29%	31.29%	2.0%	5.11
TGBC24	1.41	63.92%	22.63%	1.91%	4.16
TGBC44	1.50	67.03%	26.04%	1.91%	4.08

CV: Coefficient of variation

Table 4.3. Colony Characteristics

Cell names	Type	Size (μm)	Plating Efficiency ±SD(%)
TGBC-1	Flat, segregated	143.2±47.5μm	19±6%
TGBC-2	Flat, segregated	155± 43μm	26±11%
TGBC-14	Flat, segregated	63±27μm	13±5%.
TGBC-24	Flat, segregated	160±60μm	11±5%
TGBC-44	Flat, segregated	131±53μm	23 ±16%

Table 4.4. Overlapping regions of common DNA copy number changes in more than 3 cell lines

Chromosomal locus	TGBC1	TGBC2	TGBC14	TGBC24	TGBC44	Cancer related gene
1q21-q25	G	NC	G	NC	G	MUC1,COX2
1q41-qter	G	NC	NC	G	G	TGFβ2
2p12-pter	G	G	NC	G	G	RAB1,PAP
2q12-q21	G	NC	G	G	G	RAB6
3q13	G	G	G	NC	NC	
3q26-qter	NC	NC	G	G	G	hTR
5p12-pter	G	G	NC	G	G	hTERT
6p12-pter	G	NC	NC	G	G	TNFA, VEGF
6q12	G	NC	NC	G	G	
7p12-pter	G	G	NC	G	G	EGFR
7q21-q31	G	G	L	G	G	MET, MDR
8q23-qter	NC	G	NC	G	G	cMYC
11q12-q23	G	G	NC	G	G	
12p12-pter	G	G	L	G	G	RAS,CDK2/CCNA
16q21-qter	NC	G	L	G	G	
17p13-pter	G	G	G	NC	NC	P53
17q21-q23	NC	G	NC	G	G	ERBB2
18p11-pter	G	G	G	NC	NC	

19q13-qter	G	NC	G	NC	G	TGFβ1,AKT2,CEA
+20p12-pter	G	G	G	NC	NC	PCNA
+20q12-qter	G	G	G	G	G	SRC
Xq12-q24	NC	NC	G	G	G	
3p12-p13	L	L	L	NC	NC	
9q21	L	NC	L	L	NC	
21q21	L	L	L	NC	NC	

G-gain,L-loss and NC-no change

4.7 REFERENCES

1. Homma, S., Hasumura, S., Nagamori, S., and Kameda, H. Establishment and characterization of a human gall bladder carcinoma cell line NOZ. Hum Cell, *1:* 95-97, 1988.
2. Egami, H., Sakamoto, K., Yoshimura, R., Kikuchi, H., and Akagi, M. Establishment of a cell line of gallbladder carcinoma (GBK-1) producing human colony stimulating factor. Jpn J Cancer Res, *77:* 168-176, 1986.
3. Jiao, W., Miyazaki, K., and Kitajima, Y. Exogenous expression of E-cadherin in gallbladder carcinoma cell line G-415 restores its cellular polarity and differentiation. Int J Oncol, *19:* 1099-1107, 2001.
4. Nishida, T., Iwasaki, H., Johzaki, H., Tanaka, S., Watanabe, R., and Kikuchi, M. A human gall-bladder signet ring cell carcinoma cell line. Pathol Int, *47:* 368-376, 1997.
5. Knuth, A., Gabbert, H., Dippold, W., Klein, O., Sachsse, W., Bitter-Suermann, D., Prellwitz, W., and Meyer zum Buschenfelde, K. Biliary adenocarcinoma. Characterisation of three new human tumor cell lines. J Hepatol, *1:* 579-596, 1985.
6. Yano, H., Maruiwa, M., Iemura, A., Mizoguchi, A., and Kojiro, M. Establishment and characterization of a new human extrahepatic bile duct carcinoma cell line (KMBC). Cancer, *69:* 1664-1673, 1992.
7. Tanaka, T., Kanai, F., Okabe, S., Yoshida, Y., Wakimto, H., Hamada, H., Shiratori, Y., Lan, K., Ishitobi, M., and Omata, M. Adenovirus-mediated prodrug genetherapy for carcinoembryonic antigen-producing human gastric carcinoma cells in vitro. Cancer res, *56:* 1341-1345, 1996.
8. Kawamoto, T., Shoda, J., Irimura, T., Miyahara, N., Furukawa, M., Ueda, T., Asano, T., Kano, M., Koike, N., Fukao, K., Tanaka, N., and Todoroki, T. Expression of MUC1 mucins in the subserosal layer correlates with postsurgical prognosis of pathological ttumour stage2 carcinoma of the gallbladder. Clin. cancer Res, *7:* 1333-1342, 2001.
9. Kalloniemi, O., Kalloniemi, A., Kurisu, W., Thor, A., Chen, L.-C., Smith, H. S., Waldman, F., Pinkel, D., and Gray, J. ERBB2 amplification in breast cancer analyzed by fluorescence in situ hybridization. Proc.Natl.Acad.Sci, *89:* 5321-5325, 1992.
10. Furitsu, T., Tsujimura, T., Tono, T., Ikeda, H., Kitayama, H., Koshimizu, U., Sugahara, H., Butterfield, J., Ashman, L., Kanayama, Y., Matsuzawa, Y., Kitamura, Y., and Kanakura, Y. Identification of mutations in the coding sequence of the proto-oncogene c-kit in a human mast cell leukemia cell line causing ligand-dependent activation of c-kit product. J.Clin. Invest, *92:* 1736-1744, 1993.
11. Seabright, M. A rapid banding technique for human chromosomes. Lancet, *2:* 971-972, 1971.
12. Kusano, N., Okita, K., Shirahashi, H., Hanada, T., Shiraishi, K., Oga, A., Kawandu, S., Furuya, T., and Sasaki, K. Chromosomal imbalances detected by comparative genomic hybridyzation are associated with outcome of patients with hepatocellular Carcinoma. Cancer, *94:* 746-751, 2002.
13. Emura, F., Kamma, H., Ghosh, M., Koike, N., Kawamoto, T., Saijo, K., Ohno, T., Ohkohchi, N., and Todoroki, T. Establishment and characterization of novel xenograft models of human biliary tract carcinomas. Int. J Oncol, *23:* 1293-1300, 2003.
14. Lee, K., Nguyen, C., Ulrich, A., Pour, P., and Ouellette, M. Immortalization with telomerase of the Nestin-positive cells of the human pancreas. Biochem Biophys Res Commun, *301:* 1038-1044, 2003.
15. Gorunova, L., Parada, L., Limon, J., Jin, Y., Hallen, M., Hagerstrand, I., Iliszko, M., Wajda, Z., and Johansson, B. Nonrandom chromosomal aberrations and cytogenetic

heterogeneity in gallbladder carcinomas. Genes Chromosomes Cancer, *26:* 312-321, 1999.

16. Yano, Y., Yoshida, K., Osaki, A., Toge, T., Tahara, H., Ide, T., and Yasui, W. Expression and distribution of human telomerase catalytic component, hTERT, in human breast tissues. Anticancer Res, *22:* 4101-4107, 2002.
17. Nowak, J., Januszkiewicz, D., Lewandowski, K., Nowicka-Kujawska, K., Pernak, M., Rembowska, J., Nowak, T., and Wysocki, J. Activity and expression of human telomerase in normal and malignant cells in gastric and colon cancer patients. Eur J Gastroenterol Hepatol, *15:* 75-80, 2003.
18. Kiguchi, K., Carbajal, S., Chan, K., Beltran, L., Ruffino, L., Shen, J., Matsumoto, T., Yoshimi, N., and DiGiovanni, J. Constitutive expression of erbB-2 in gallbladder epithelium results in development of adenocarcinoma. Cancer Res, *61:* 6971-6976, 2001.
19. Rashid, A. Cellular and molecular biology of biliary tract cancers. Surg Oncol Clin N Am, *11:* 995-1009, 2002.
20. Yoshida, S., Todoroki, T., Ichikawa, Y., Hanai, S., Suzuki, H., Hori, Fukao, K., Miwa, M., and Uchida, K. Mutations of p16Ink4 /CDKN2 and p15Ink4B/ MTS2 genes in biliary tract cancers. Cancer Res, *55:* 2756-2760, 1995.
21. Kitamura, K., Kasuya, K., Tsuchida, A., Mimuro, A., Inoue, K., Aoki, T., Aoki, T., and Koyanagi, Y. Immunohistochemical analysis of transforming growth factor beta in gallbladder cancer. Oncol Rep, *10:* 327-332, 2003.
22. Arboleda, M., Lyons, J., Kabbinavar, F., Bray, M., Snow, B., Ayala, R., Danino, M., Karlan, B., and Slamon, D. Overexpression of AKT2/protein kinase Bbeta leads to up-regulation of beta1 integrins, increased invasion, and metastasis of human breast and ovarian cancer cells. Cancer Res, *63:* 196-206, 2003.
23. Bacus, S., Altomare, D., Lyass, L., Chin, D., Farrell, M., Gurova, K., Gudkov, A., and Testa, J. AKT2 is frequently upregulated in HER-2/neu-positive breast cancers and may contribute to tumor aggressiveness by enhancing cell survival. Oncogene, *21:* 3532-3540, 2002.
24. Shiraishi, K., Okita, K., Kusano, N., Harada, T., Kondoh, S., Okita, S., Ryozawa, S., Ohmura, R., Noguchi, T., Y, I., Akiyama, T., Oga, A., Fukumoto, Y., T, F., Kawauchi, S., and Sasaki, K. A comparison of DNA copy number changes detected by comparative genomic hybridization in malignancies of the liver, biliary tract and pancreas. Oncology, *60:* 151-161, 2001.

CHAPTER – 5

MORTALIN EXPRESSIONS IN GALLBLADDER CANCER CELL LINES

5.1. ABSTRACT

Background: Mortalin/mthsp70/PBP74/Grp75, a member of the Hsp70 family of chaperones, was shown to have different sub cellular localizations in normal and immortal cells. It has been implicated in multiple functions ranging from stress response, intracellular trafficking, antigen processing, and control of cell proliferation, differentiation, and tumorigenesis. **Aim**: To study this protein in relation to gallbladder cancer. **Materials and methods**: We checked the Mortalin expression in gallbladder cancer cell lines with fluorescence anti Mortalin antibody. Mortalin expression was checked in the gallbladder cancer cell lines by western blot. We double stained gallbladder cancer cell lines with Mortalin and PI and checked the Mortalin expression in relation to cell cycle by laser scan cytometry Camera. Mortalin expression in relation with cell cycle was checked by western blot in TGBC2 cell line. **Results**: In the entire analysed gallbladder cancer cell lines Mortalin expressed in a perinuclear fashion. By western blot experiment Mortalin expression is high in gallbladder cancer cell lines in comparison with the fibroblast. By laser scan cytometry Mortalin was expressed through out the cell cycle in the entire analysed cell lines by laser scan cytometry and also by western blot. **Conclusion:** Gallbladder cancer cell lines expressed Mortalin in a

perinuclear fashion. Mortalin expression is high in gallbladder cancer cell lines in comparison to normal fibroblast. There is no difference in Mortalin expression and staining pattern in primary or metastatic tumors. There is no relation of Mortalin with cell cycle. May be Mortalin expression is not regulated by cell cycle but by some other mechanism.

5.2. INTRODUCTION

Mortalin is a member of heat shock protein 70 (hsp70) family of proteins. It is differentially distributed in normal and cancerous cells.(1). cDNAs encoding the pancytoplasmically distributed protein (mot-1) and the perinuclear protein (mot-2) were cloned from normal and immortal fibroblasts, respectively(2).These were shown to be different by two amino acids(2) and have contrasting biological activity(3).The mot-1cDNA encoded pancytoplasmic distribution when introduced into NIH 3T3 cells caused cellular senescence like phenotype in these cells(2). The mot-2 cDNA that encoded perinuclear protein resulted in malignant transformation of NIH 3T3 cells (3) and extension of life span of normal fibroblast (4).It is already reported that Mortalin is inevitable for normal cell activity (5, 6) and not only staining pattern but also structure and even activity of Mortalin is also changed in cancer cells than normal cells (2, 3). Mortalin is reported to be involved in control of cell proliferation (3, 4), differentiation (7) and tumorigenesis (3, 8). Mortalin is also shown to cause inactivation of tumor suppressor protein p53 (9). All these functions of Mortalin prompted us to check Mortalin expression in gallbladder cancer. We first checked Mortalin expression in gallbladder cancer. Then we checked Mortalin expression in the cell lines in comparison with normal cells and also checked Mortalin expression in relation with cell cycle in gallbladder cancer cell lines.

5.3. MATERIALS AND METHODS

5.3.1. Cell culture

We have selected 7 gallbladder cell lines to check the Mortalin expression. TGBC1, TGBC2, TGBC14, TGBC24, TGBC44 are our gallbladder cell lines, Mz-Cha-1, Mz-Cha- 2 are gallbladder cancer cell lines established by Knuth et al. (10) All Cells were cultured in DMEM with 10% FBS.

5.3.2. Immunostaining

We used normal human fibroblast derived from surgical specimen as a positive control. Since all cells express Mortalin, as negative control non-immune immunogloblin instead of primary antibody was used for Mortalin positive cells in our experiment. Gallbladder cancer cultured on cover slips placed in12 well plastic plates. After 24 h, when cells had attached to the surface and spread well, they were washed thrice with cold PBS and fixed with a prechilled methanol/acetone (1/1, v/v) mixture for 5 min on ice. Fixed cells were washed with PBS, permeabilized with 0.1% Triton X-100 in PBS for 10 min, and blocked with 2% bovine serum albumin (BSA) in PBS for 10 min. They were incubated with anti-mortalin antibody (1) (1:600 dilution in PBS with 1% BSA) for 1 hr at room temperature, washed with PBS with 0.1% Triton X-100, for 3 times, and then incubated with fluorescein isothiocyanate-conjugated anti-rabbit immunoglobulin G for 30 minutes (Amarsham Texas Red, FITC-1: 100, Molecular Probe Alexa 594,488-1:5000 in 2% BSA/PBS for 30 min. After six washings in PBS with 0.1% Triton X-100 (0.2%) on shaker for 10 minutes each time, cells were again washed with PBS on shaker for 10 minutes. Then staining with PI (20microgm/ml), RNAase (200micro gram/ml /PBS for 30 minutes at 37^0 cover with foil. Ringe in milli Q, cells were mounted in a slide with Fluoromount (Difco). The cells were examined under an Olympus BH-2 microscope with an epifluorescence optic.

5.3.3. Western blots Analysis

Gallbladder cancer cell lines (TGBC1, TGBC2, TGBC24, TGBC44, and Mz-Cha-1) lysates and normal fibroblast TIG 1 lysate as control, containing Protein samples (10 μg) were separated on SDS–polyacrylamide gels and electro blotted onto nylon membranes (Millipore) using a semi-dry-transfer apparatus. Immunoassays were performed with polyclonal anti-mortalin (1) at dilution 1: 10000 or anti-actin (MAB1501R; Chemicon, USA) monoclonal antibodies at dilution 1:5000. The immunocomplexes formed were visualized with horseradish-peroxidase-conjugated secondary antibodies using an enhanced chemiluminescence kit (Amersham Biosciences).

5.3.4. Laser Scans Cytometry

We doubled stained TGBC1, TGBC2, TGBC24, TGBC44, Mz Cha1, and Mz-Cha2 cells with Mortalin and PI and Olympus LSC 2 camera scanned the Mortalin expression and cell cycle phase. The result was analysed using the computer software. Mortalin expression was analysed in relation with cell cycle phase.

5.3.5. Mortalin expression in TGBC2 cell line in different phase of cell cycle by western blot

We have grown the TGBC 2 cells in 10% FCS overnight. Added thymidine (2mM) and incubate for 16 hrs. Then wash three times with fresh medium and grow 8hr in 10% FCS. Add 2mM thymidine and incubate for 16 hrs (double thymidine block). Wash three times with fresh medium and refed with 10% FCS medium. Harvest cells at different times for cell cycle analysis. S phase=2-4h, G2/M phase 6-8h, M phase-10hr and did the western blot experiment.

5.4. RESULTS

5.4.1. Immunostaining

Mortalin is expressed in all the 7 cell lines in a peri nuclear pattern (fig 5.1). In the normal cells Mortalin expressed in pancytoplasmic pattern (Fig. 5.2). So we observed that in the epithelial cancer also Mortalin expressed and expression is in perinuclear pattern.

Amongst the cell lines only TGBC2 and TGBC14 are only primary tumour. Rest others are metastatic tumour. But Mortalin expression is not different from primary and metastatic tumour. So Mortalin expression is not related with primary or metastatic tumour.

5.4.2. Western blot

By western blot experiment Mortalin expression is different in the cell lines. In comparison to the normal cell fibroblast cell line mortalin expression is high inTGBC1, TGBC2, TGBC24, TGBC44, and Mz-Cha-1 (Fig-5.3). We did not find any correlation of Mortalin expression between and primary and metastatic tumour cell lines of gallbladder cancer cell lines. So our observation is that Mortalin expression is higher in gallbladder cancer cell line in comparison to the normal fibroblast.

5.4.3. Laser Scan Cytometry

In laser scan cytometry Mortalin was present through out the cell cycle of all the analysed cell lines (Fig 5.4). In gallbladder cancer cell lines, originated from primary tumors and metastatic tumors Mortalin was present in each phase of the cell cycle. In each phase of the cell cycle some cells are Mortalin positive and some did not express Mortalin. So may be Mortalin expression is not related with cell cycle.

5.4.4. Mortalin expression in TGBC2 cell line in different phase of cell cycle by western blot

We checked Mortalin expression in different cell cycle phase in TGBC2 cell line by western blot and found that Mortalin is present in each phase of cell cycle (Fig 5.5). So reconfirmed our result of laser scan cytometry and again found that Mortalin is present in each phase of the cell cycle. So there is no relation of Mortalin with cell cycle.

5.5. DISCUSSIONS

This is the first study of Mortalin expression in epithelial malignancy. From our studies we have seen that Mortalin is expressed in each cell line of gallbladder cancer. In all gallbladder cancer cell lines Mortalin expressed in a perinuclear pattern. We observed that Mortalin expression pattern is different from normal and cancer cells but there is no relation of Mortalin expression and staining pattern according to the origin of the tumour, primary or metastatic. It is already reported that Mortalin expression is different in normal and immortal cells and in immortal cells expression pattern is perinuclear pattern (11). So Mortalin can be used as a marker for diagnosis of gallbladder cancer cells.

Mortalin is high in our gallbladder cancer cell lines in comparison to the normal cells. Mortalin is reported to be high in immortal cells and other cancer cells (3, 8, 12, 13). So we can assume that Mortalin is related with gallbladder cancer also.

In our laser scan cytometry observation we found that all the analysed cell lines irrespective of gallbladder cancer cell lines, primary or metastatic tumors. Mortalin is expressed in each phase of the cell cycle. In each phase of the cell cycle of each cell line some cells are Mortalin positive and some cells are Mortalin negative. We reconfirmed our result by western blot experiment also and found the same result. So may be Mortalin expression is not regulated by the cell cycle. Some other mechanism may be responsible for Mortalin

expression regulation. It is already reported that Mortalin inactivates the p53 tumour suppressor gene (4, 9). May be p53 gene has some role in Mortalin regulation.

Mortalin controls cell proliferation (3, 4), differentiation (7) and tumorigenesis (3, 8, 12, 13). Mortalin is also shown to cause inactivation of tumor suppressor protein p53 (9). TP53 inactivation has an important and early role in gallbladder carcinoma associated with gallstones and chronic inflammation. TP53 may be involved in biliary tract carcinogenesis (14-16). So Mortalin may have a role in gallbladder cancer. Mortalin can be used as a novel approach in treatment of gallbladder tract cancer.

5.6. CONCLUSIONS

From our study we found that Mortalin is expressed in gallbladder cancer in a perinuclear fashion. Mortalin expression is high in the gallbladder cancer cells. Expression and staining pattern were not related with origin of the cell line, primary or metastatic and it was not regulated by cell cycle. May be other mechanism is responsible for its regulation which is yet to be clearly understood.

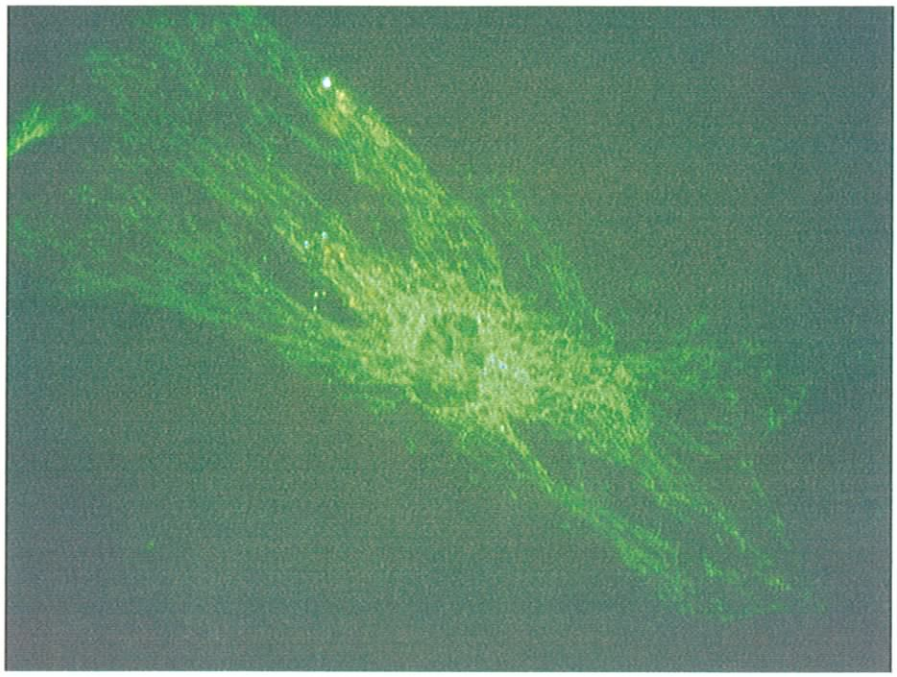

Fig-5.1 Pancytoplasmic pattern of Mortalin in normal fibroblast as positive control

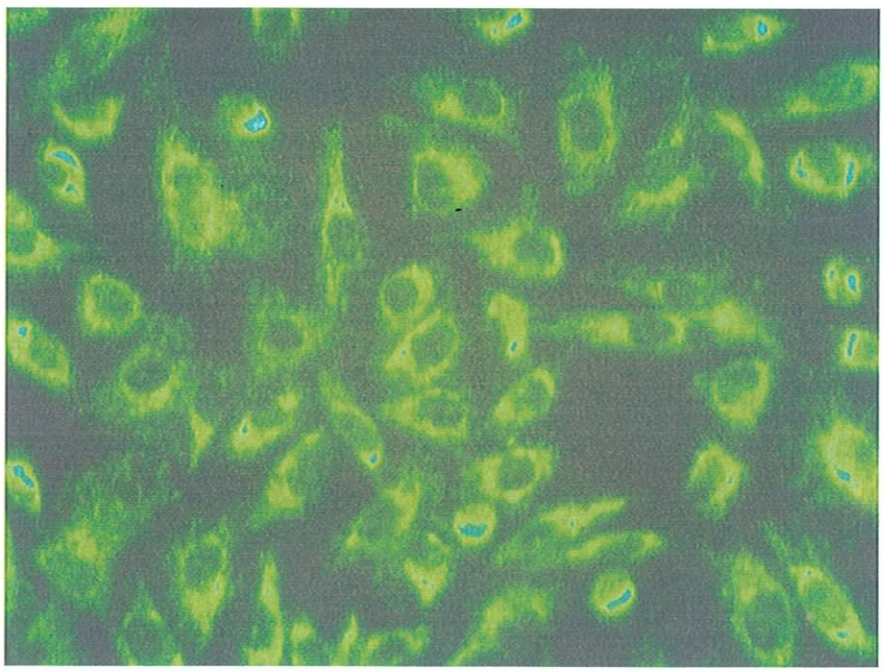

Fig 5.2 Perinuclear pattern of Mortalin in TGBC2 cell line

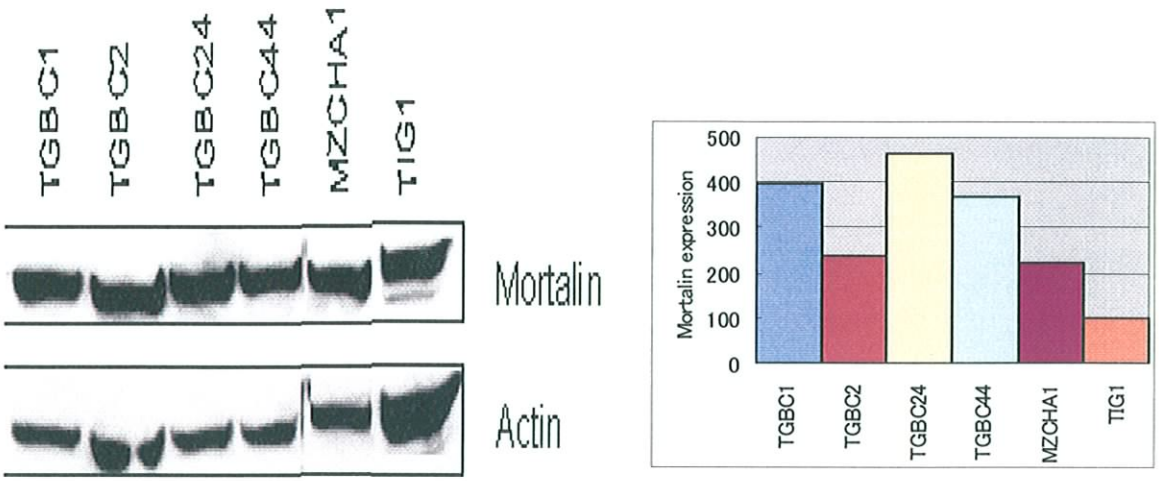

Fig 5.3 Mortalin expression in different gallbladder cancer cell lines by western blot experiment showed high expression of Mortalin in comparison to TIG1 normal fibroblast

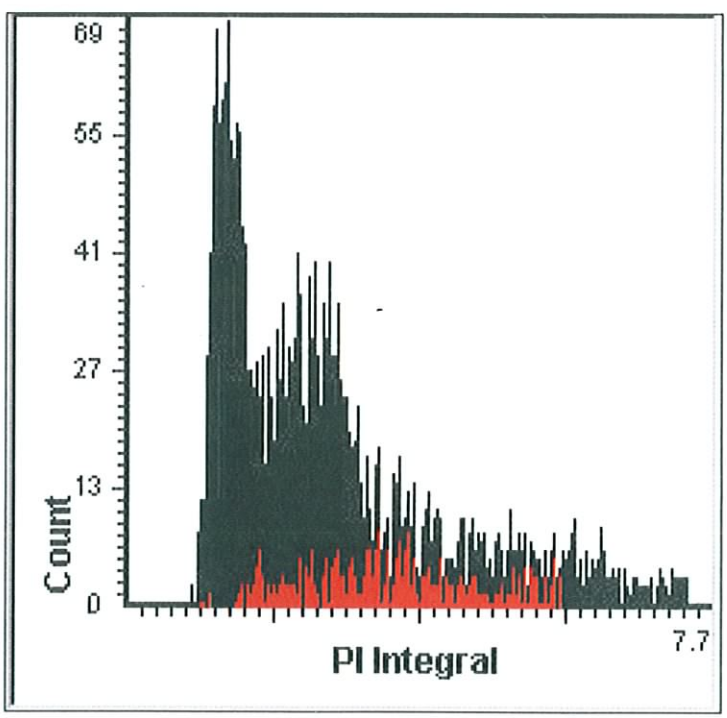

Fig 5.4 DNA histogram in TGBC2 cell line double stained with Mortalin and PI. Red color shows PI indicating Mortalin expression in different phase of cell cycle in TGBC2 cell line

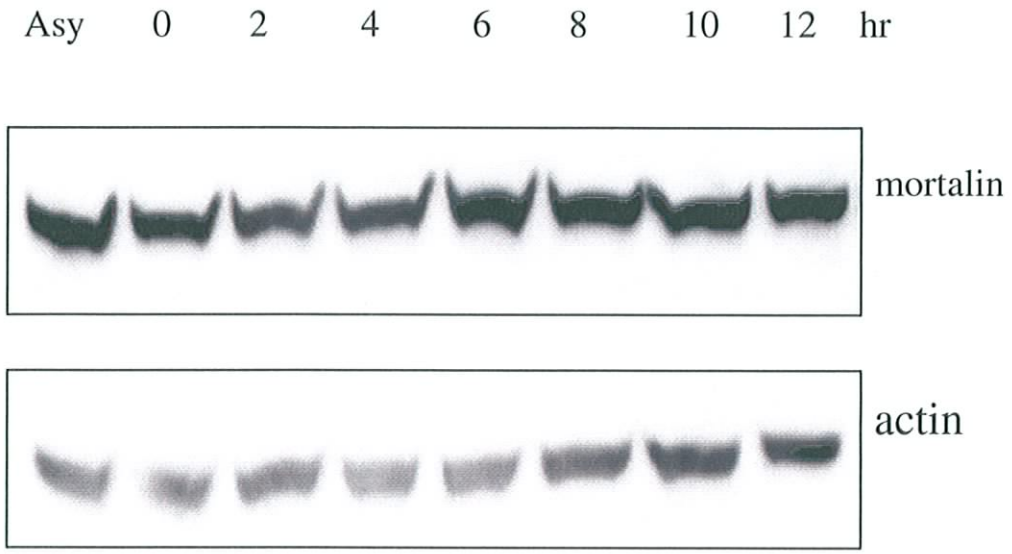

Fig 5.5 Mortalin expression in different cell cycle phase of TGBC2 cell line by western blot

5.7 REFERENCES

1. Wadhwa, R., Kaul, S., Ikawa, Y., and Sugimoto, Y. Identification of a novel member of mouse hsp70 family. Its association with cellular mortal phenotype. J Biol Chem, *268:* 6615-6621, 1993.
2. Wadhwa, R., Kaul, S., Sugimoto, Y., and Mitsui, Y. Induction of cellular senescence by transfection of cytosolic mortalin cDNA in NIH 3T3 cells. J Biol Chem, *268:* 22239-22242, 1993.
3. Kaul, S., Duncan, E., Englezou, A., Takano, S., Reddel, R., Mitsui, Y., and Wadhwa, R. Malignant transformation of NIH3T3 cells by overexpression of mot-2 protein. Oncogene, *17:* 907-911, 1998.
4. Kaul, S., Reddel, R., Sugihara, T., Mitsui, Y., and Wadhwa, R. Inactivation of p53 and life span extension of human diploid fibroblasts by mot-2. FEBS Lett., *474:* 159-164, 2000.
5. Krimmer, T., Rassow, J., Kunau, W., Voss, W., and Pfanner, N. Mitochondrial protein import:the ATPase domain of matrix hsp70 is crucial for binding to Tim44, while the peptide binding domain and the carboxy- terminal segment play a stimulatory role. Mol. Cell. Biol, *20:* 5879-5887, 2000.
6. Geissler, A., Rassow, J., Planner, N., and Voos, W. Mitochondrial import driving forces:enhanced trapping by matrix hsp70 stimulates translocation and reduces the

membrane potentialdependence of loosely folded preproteins. Mol.Cell.Biol, *21:* 7097-7104, 2001.

7. Xu, J., Xiao, H., and Sartorelli, A. Attenuation of the induced differentiation of HL-60 leukemia cells by mitochondrial chaperone HSP70. Oncol Res, *11*, 1999.
8. Takano, S., Wadhwa, R., Yoshii, Y., Nose, T., Kaul, S., and Mitsui, Y. Elevated levels of mortalin expression in human brain tumors. Exp Cell Res, *237:* 38-45, 1997.
9. Wadhwa, R., Takano, S., Robert, M., Yoshida, A., Nomura, H., Reddel, R., Mitsui, Y., and Kaul, S. Inactivation of tumor suppressor p53 by mot-2, a hsp70 family member. J Biol Chem, *273:* 29586-29591, 1998.
10. Knuth, A., Gabbert, H., Dippold, W., Klein, O., Sachsse, W., Bitter-Suermann, D., Prellwitz, W., and Meyer zum Buschenfelde, K. Biliary adenocarcinoma. Characterisation of three new human tumor cell lines. J Hepatol, *1:* 579-596, 1985.
11. Wadhwa, R., Kaul, S., Mitsui, Y., and Sugimoto, Y. Differential subcellular distribution of mortalin in mortal and immortal mouse and human fibroblasts. Exp Cell Res 442-448, 1993.
12. Takahashi, S., Mikami, T., Watanabe, Y., Okazaki, M., Okazaki, Y., Okazaki, A., Sato, T., Asaishi, K., Hirata, K., and Narimatsu, E. Correlation of heat shock protein 70 expression with estrogen receptor levels in invasive human breast cancer. Am J Clin Pathol, *101:* 519-525, 1994.
13. Bini, L., Magi, B., Marzocchi, B., Arcuri, F., Tripodi, S., Cintorino, M., Sanchez, J., Frutiger, S., Hughes, G., Pallini, V., Hochstrasser, D., and Tosi, P. Protein expression profiles in human breast ductal carcinoma and histologocally normal tissue. Electrophoresis, *18:* 2832-2841, 1997.
14. Rashid, A. Cellular and molecular biology of biliary tract cancers. Surg Oncol Clin N Am, *11:* 995-1009, 2002.
15. Furubo, S., Harada, K., Shimonishi, T., Katayanagi, K., Tsui, W., and Nakanuma, Y. Protein expression and genetic alterations of p53 and ras in intrahepatic cholangiocarcinoma. Histopathology, *35:* 230-240, 1999.
16. Ohashi, K., Nakajima, Y., Kanehiro, H., Tsutsum, M., Taki, J., Aomatsu, Y., Yoshimura, A., Ko, S., Kin, T., Yagura, K., Konishi, Y., and Nakano, H. Ki-ras mutations and p53 protein expressions in intrahepatic cholangiocarcinomas: relation to gross tumor morphology. Gastroenterology, *136:* 1612-1617, 1995.

CHAPTER 6

CONCLUSIONS

Our established cell lines will be an ideal tool for in vitro studies of gallbladder cancer biology and testing of anti cancer drugs for gallbladder cancer. Studying different molecules in relation with gallbladder cancer like COX-2, MUC1, c-erbb2, c-kit will be highly effective in making molecule targeting chemotherapy for gallbladder cancer. The development and progression of cancer are accompanied by complex genetic alterations resulting in changes in patterns of gene expression in cancer. Gene amplifications and deletions contribute to changes in the expression of oncogenes and tumour suppressor genes respectively. The genetic analysis by CGH revealed an initial impression of genetic changes in relation to gallbladder cancer. For more detail genetic analysis in the next step we are going to make array CGH.

Our study revealed that:

- COX2 and MUC1 studies are the first reports regarding COX2 and MUC1 expression in gallbladder cancer in comparison with normal and inflammations.
- Our study revealed that COX2 expression in the gallbladder may be regulated by various factors and not directly related to carcinogenesis.
- MUC1 expression was significantly higher in gallbladder cancer cells than in normal and inflammatory gallbladder cells. In cancer cells, the depolarized staining pattern was dominant, while in non-cancerous tissues the polarized pattern was dominant. Lymphatic vessel invasion is significantly related with depolarised expression.

- Our newly established cell lines might serve as a useful model for studying the molecular pathogenesis and testing of new therapeutics against gallbladder and bileduct cancer. These chromosomal aberrations and imbalances provide a starting point for molecular analyses of genomic regions and genes in gallbladder and bile duct carcinogenesis.
- Our cell lines expressed Mortalin in a perinuclear fashion Mortalin expression is high in our cell lines, and Mortalin expression is not regulated by the cell cycle but may be by some other mechanism.

Future Work:

1. Array CGH in the gallbladder cancer cell lines.
2. Targeting different molecules like anti COX2, anti Mortalin, anti her2 using our cell lines as a future target of anti cancer drug against gallbladder cancer.

List of Publications

1. **Ghosh M,** Koike N, Tsunoda S, Hirano T, Kaul S, Kashiwagi H, Kawamoto T, Ohkohchi N, Saijo K, Ohno T, Miwa M, Todoroki T. (2004) **"**Characterisation and Genetic analysis in the newly established Human Bile Duct Cancer Cell Lines". **International Journal of Oncology.** Vol 26:449-456, 2005.
2. **Ghosh M.,** Koike N., Yanagimoto G, Tsunoda S, Kaul S, Hirano T, Emura F, Kashiwagi H, Kawamoto T, Ohkohchi N, Saijo K, Ohno T, Miwa M, Todoroki T. (2004) "Establishment and Characterisation of Unique Human gallbladder Cancer Cell Lines". **International Journal of Oncology,** Vol. 24:1189-1196, 2004.
3. **Ghosh M.,** Kawamoto, T. , Kamma, H., Koike, N., Miwa ' M., Kapoor, V. K ., Krishnani, N., Agrawal, S., Okouchi, N. and. Todoroki , T., "Different Expression of MUC1 in the Gallbladder Disease". **Internet Journal of Surgery**. Vol. 4, No. 2 (10 pages) **http://www.ispub.com/ostia/index.php?xmlFilePath=journals/ijs/vol4n2/muc1.xml**
4. **Ghosh, M.,** Kawamoto, T., Koike, N., Fukao, K., Yoshida, S., Kashiwagi, H., Kapoor, V., Agarwal, S., Krishnani, N., Uchida, K., Miwa, M., and Todoroki, T. (2000), "Cyclooxygenase expression in the gallbladder", **International Journal of Molecular Medicine**. Vol. 6, Page 527-532.
5. G**hosh M.,** Kamma, H., Kawamoto, T.,Koike, N., Miwa ' M., Kapoor, V. K ., Krishnani, N., Agrawal, S., Okouchi, N. and. Todoroki , T., "Expression of MUC1 core protein in the gallbladder tissues---Cancer , Inflammations and normal gallbladder"--. Submitted to European Jornal of Oncology (EJSO), October 1st. 2004.