

# Percutaneous endoscopic discectomy might be effective in selected cases of pyogenic spondylitis

Mamoru Kono<sup>1</sup>, Masao Koda<sup>1</sup>, Tetsuya Abe, Kousei Miura, Katsuya Nagashima, Kengo Fujii, Hiroshi Kumagai, Hiroshi Noguchi, Toru Funayama and Masashi Yamazaki

## Abstract

**Background:** Percutaneous endoscopic discectomy (PED) has been reported to be an effective procedure and minimally invasive surgical therapy for various spinal pathologies. **Objective:** To evaluate the clinical outcome of patients with pyogenic spondylitis who were treated with PED. **Methods:** Twenty-four patients with pyogenic spondylitis who underwent PED were evaluated for medical history, level of the affected intervertebral space, mode of onset, plain radiographs, epidural or psoas abscesses on MRI, results of blood and intraoperative sample cultures, preoperative C-reactive protein (CRP) level, time until postoperative CRP normalization (CRP < 0.3), and any additional surgery. Patients who underwent additional surgery and showed uncontrollable inflammation were considered to have “failed” PED for pyogenic spondylitis. To elucidate the factors that were significantly associated with a failure of PED for pyogenic spondylitis, statistical analyses were conducted by univariate analysis. **Results:** Control of inflammation was achieved in 19 of 24 patients (76%) after PED for pyogenic spondylitis. The remaining five patients failed to achieve infection control by PED. One such patient was not able to control the infection after PED, and another patient developed an epidural abscess 2 weeks after PED. Remaining three “failed” patients had exacerbations of their infections during the postoperative course and required additional surgery. Univariate analyses demonstrated that diabetes mellitus (DM;  $p = 0.05$ ), hemodialysis due to DM-induced renal failure ( $p = 0.02$ ), concomitant malignant disease ( $p = 0.09$ ), and acute onset ( $p = 0.05$ ) were possibly correlated with PED failure. Stepwise logistic regression analysis revealed that hemodialysis due to DM-induced renal failure was an independent factor associated with PED failure ( $p = 0.03$ ). **Conclusions:** PED might be considered as one of the alternative therapeutic options before invasive radical surgeries for pyogenic spondylitis after failure of standard conservative therapy. Even by less invasive PED, pyogenic spondylitis patients with DM-hemodialysis showed poor outcome.

## Keywords

diabetes mellitus, hemodialysis, immunocompromised patients, percutaneous endoscopic discectomy, pyogenic spondylitis

Date received: 25 March 2019; Received revised 10 September 2019; accepted: 8 October 2019

## Introduction

Conservative therapy with local rest and antibiotics had been considered as the gold standard treatment for pyogenic spondylitis, except for the following conditions: bacterial culture or tissue diagnosis is absent, neurological deficit, mechanical instability, failure of response with

Department of Orthopedic Surgery, University of Tsukuba, Ibaraki, Japan

### Corresponding author:

Mamoru Kono, Department of Orthopedic Surgery, University of Tsukuba, Tennodai, Tsukuba City, Ibaraki 3058575, Japan.

Email: mamoru.kono@gmail.com



Creative Commons Non Commercial CC BY-NC: This article is distributed under the terms of the Creative Commons Attribution-NonCommercial 4.0 License (<http://www.creativecommons.org/licenses/by-nc/4.0/>) which permits non-commercial use, reproduction and distribution of the work without further permission provided the original work is attributed as specified on the SAGE and Open Access pages (<https://us.sagepub.com/en-us/nam/open-access-at-sage>).

correct adequate antibiotics, and spinal deformity, of which conditions should be considered to surgical intervention.

<sup>1,2</sup>However, the number of complicated cases with difficulty to treat by standard conservative therapies due to aging of the Japanese population and increases in the number of patients with multiple comorbidities and the number of immunocompromised hosts. Therefore, it is important to minimize the invasiveness of the alternatives to the standard conservative therapies. Percutaneous drainage is one minimally invasive treatment option for intractable pyogenic spondylitis.<sup>3</sup> Previous studies have demonstrated the efficacy of percutaneous endoscopic discectomy (PED) as a minimally invasive surgical therapy for various spinal pathologies.<sup>4-9</sup> However, the optimal indication and limitation of PED for pyogenic spondylitis remains to be elucidated, although the previous reports described the usefulness of PED for pyogenic spondylitis by relatively small case series. Therefore, the primary aim of the present study was to elucidate the limitation of PED for pyogenic spondylitis by analyzing outcome of our retrospective case series.

## Patients and methods

### Patients

In the present study, we retrospectively reviewed the clinical records of 28 patients who underwent PED for pyogenic spondylitis between June 2009 and June 2015 at our institution. Three patients with microbiology cultures positive for mycobacterium tuberculosis or mycobacterium avium species, because infections with these bacteria cause different clinical entities than pyogenic spondylitis, and one patient who died from systemic disseminated bacteremia within 2 weeks of PED were excluded. Therefore, the present study included 24 patients (19 male and 5 female) (Table 1). The average age at the time of surgery was 69.2 years (range 46–88 years), and the average follow-up period was  $28.7 \pm 21.6$  weeks after PED (Tables 1 and 2).

### Data collection

The patients were retrospectively evaluated for medical history, level of the affected intervertebral space, mode of onset, plain radiographs, presence or absence of epidural or psoas abscesses on magnetic resonance imaging (MRI), results of blood and intraoperative sample cultures, preoperative C-reactive protein (CRP) level, time until postoperative CRP normalization (CRP < 0.3), and any additional surgery. The mode of onset was evaluated using the Kulowski classification,<sup>10</sup> and plain radiographs were evaluated using the modified Griffiths classification (Table 3).<sup>11</sup>

### Surgical Procedure of PED

PED was performed under general anesthesia. The surgery was performed with the patient in the prone position. A

**Table 1.** Patient background.

Male:female	15:9
Age at surgery (years)	69.2 $\pm$ 13.3
Follow-up [Initiation of symptom, according to Kulowski classification] (weeks)	28.7 $\pm$ 21.6
Concomitant diseases, <i>n</i>	
DM	10
HD	5
Malignancy	5
Steroid and/or immunosuppressant	2
Imaging findings	
X-ray (modified Griffiths classification)	
I	13
II	9
III	2
MRI	
Epidural abscess	3
Psoas abscess	4
Laboratory data	
CRP	3.1 (0.03 to 13.03)
Positive blood bacterial culture	9 patients
Positive intraoperative sample culture	4 patients

DM: diabetes mellitus; HD: hemodialysis; MRI: magnetic resonance imaging; CRP: C-reactive protein.

small 1 cm incision was made into the skin, and a spinal endoscope (Richard Wolf GmbH, Knittlingen, Germany) was inserted into the center of the affected intervertebral disc under fluoroscopy via a posterolateral approach. A sample was collected from the lesion and submitted for bacterial culture testing. The cartilage end plate was then curetted. Bleeding from the vertebral end plate was confirmed by washing with physiological saline, after which the surgery was completed. The wound drain was left in place for 1 week on average. The mean duration of surgery was 81 min (range 39–158 min), and the volume of blood loss was minimal in all patients (Table 2).

### Statistical analyses

To elucidate the factors that were significantly associated with a failure of PED for pyogenic spondylitis, statistical analyses were conducted as follows. Patients who underwent additional surgery after PED due to intractable pain and/or neurological deficit and who showed uncontrollable inflammation (sustained elevation of CRP level more than  $1.0 \text{ mg dl}^{-1}$ ) 6 weeks after PED were considered to have “failed” PED for pyogenic spondylitis. Univariate analysis was used to determine the correlations between PED failure and patient factors (age, sex, concomitant diseases including diabetes mellitus (DM), hemodialysis due to DM-induced renal failure, concomitant malignant diseases, and initiation of symptoms according to the Kulowski classification), imaging assessments (affected vertebral level, plain radiograph class according to the modified Griffiths classification, and epidural or psoas abscess observed on MRI), and laboratory data (CRP level before PED surgery and positive pre- and/or

**Table 2.** Precise demographic data.

No	Age	Sex	BMI	Kulowski	DM	HD	Steroid	Malignancy	Neurological deficit	Level	X-ray (Griffith)	Epidural abscess	Psoas abscess	Operation time (min)	Blood loss (ml)
1	82	M	18.4	Acute	+				+	L2/3	II			158	<10
2	74	M	21.3	Chronic						L2/3	II			90	<10
3	76	F	21.5	Acute				+	+	L4/5	II			45	<10
4	83	F	24.0	Acute	+					L2/3	I		+	55	<10
5	78	M	17.0	Chronic				+		L4/5	II		+	94	<10
6	66	M	21.0	Acute	+					L1/2	I			110	<10
7	64	M	18.1	Acute				+		L4/5	I	+	+	71	<10
8	58	M	33.8	Acute	+					L2/3	II			119	<10
9	88	M	19.6	Chronic						L3/4	I			86	<10
10	82	M	20.9	Chronic						L1/2	II			68	<10
11	63	M	28.0	Chronic						L2/3	II			75	<10
12	85	M	22.6	Chronic						L2/3	I			52	<10
13	83	F	21.3	Acute						L2/3	III			93	<10
14	46	M	23.7	Acute					+	L4/5	I	+		39	<10
15	73	M	19.1	Acute	+		+			L3/4	I		+	51	<10
16	69	M	23.9	Acute						Th11/12	I			44	<10
17	71	F	19.0	Acute	+	+	+			L4/5	I	+		109	<10
18	57	M	21.2	Chronic				+		L5/S	I			87	<10
19	87	M	17.8	Chronic						L1/2	II			84	<10
20	61	M	18.9	Acute	+	+				L5/S	I			57	<10
21	46	M	30.8	Acute	+	+				L5/S1	I			101	<10
22	52	F	23.7	Acute	+	+			+	L5/S1	II	+		131	<10
23	46	N	18.4	Chronic						L2/3	III			58	<10
24	71	N	25.8	Acute	+	+		+		L2/3	I			71	<10

DM: Diabetes mellitus, HD: Hemodialysis

**Table 3.** Details of the modified Griffiths classification.

Disease stage	Disease state
Stage I Early stage	Narrowing of intervertebral disc spaces, worm-eaten destruction of vertebral endplates, absorption, and irregularities of limbus vertebrae
Stage II Progressive (destructive) stage	Bone destruction and peripheral reactive formation of new bone
Stage III Healing (osteosclerotic) stage	Osteosclerosis, formation of osteophytes, and block vertebrae

intraoperative bacterial cultures). Factors that showed a  $p < 0.1$  were selected for further analyses. Next, the selected factors were used for logistic regression analyses using a stepwise method to determine which factors were significantly associated with failure of PED for pyogenic spondylitis. The values of  $p < 0.05$  were considered statistically significant. All analyses were conducted using JMP (version 10.0.2; SAS Institute, Cary, North Carolina, USA).

## Results

Comorbidities included diabetes, which was defined as the need for insulin injections or oral diabetes drugs, in 10

patients; use of oral steroids in 2 patients, dialysis due to DM-induced chronic kidney failure in 5 patients, cancer in 5 patients, liver cirrhosis in 3 patients, and prior infection of another site in 4 patients. The onset was acute in 15 patients and insidious in 9 patients. Concomitant epidural and psoas abscesses were observed in 4 and 4 patients, respectively. Bony changes detected on plain radiographs according to the modified Griffiths classification included grade I changes in 13 patients, grade II in 9 patients, and grade III in 2 patients. The level of the affected intervertebral space was T11/12 in one patient, L1/2 in three patients, L2/3 in nine patients, L3/4 in two patients, L4/5 in five patients, and L5/S1 in four patients (Tables 1 and 2).

Bacteria were detected in the preoperative blood cultures of nine patients. Bacteria included methicillin-sensitive *Staphylococcus aureus* in two patients, *Streptococcus* in four patients, *Escherichia coli* in one patient, *Klebsiella pneumoniae* in one patient, and *Corynebacterium* in one patient. Bacteria were also detected in the intraoperative sample cultures of four patients. Bacteria included methicillin-resistant *S. aureus* in one patient, *Staphylococcus epidermidis* in one patient, *K. pneumoniae* in one patient, and Gram-positive bacteria in one patient. As a result, definitive pathogen detection was obtained in 13 of 24 patients (Table 4).

Control of inflammation was achieved in 19 of 24 patients (76%) after PED for pyogenic spondylitis

**Table 4.** Outcome date.

No	Pre-operative antibiotics	Pre-operative blood culture	Disc culture	WBC ( $\times 10^3 \mu\text{l}^{-1}$ )			CRP ( $\text{mg l}^{-1}$ )			Time to CRP <0.3	Open surgery
				Pre	3 weeks postoperatively	Final	Pre	3 weeks postoperatively	Final		
1	LVFX	Streptococcus		9.3	5.3	4.9	3.35	0.33	0.12	5w	
2				6.3	6.2	6.9	0.26	0.18	0.18	2w	
3	SBT/CPZ			3.4	2.0	2.6	4.44	1.94	3.03	Failed	
4	SBT/ABPC	Streptococcus		6.9	6.8	4.8	2.72	5.32	0.04	6w	
5				6.7	4.4	5.2	0.71	1.31	0.2	6w	
6		Klebsiella	Klebsiella	5.2	4.0	4.2	2	0.74	0.12	4w	
7				5.2	3.6	3.6	4.67	0.26	0.13	4w	
8	CTRX			5.0	3.8	4.3	3.16	3.31	1.16	Failed	6w after PED
9				5.2	3.9	3.7	1.13	0.3	0.28	4w	
10	CEZ	MSSA		13.0	6.4	5.2	13.03	3.04	0.28	9w	
11				5.7	4.2	4.0	4.93	0.72	0.2	6w	
12				10.3	4.6	3.4	7.55	0.2	0.06	1w	
13	DRPM	Streptococcus		3.0	4.3	4.4	0.03	0.08	0.07	2w	
14	VCM	Corynebacterium		7.3	4.6	4.6	2.19	6.16	0.15	4w	
15	ABPC	Escherichia coli		7.8	4.6	4.3	2.49	0.17	0.11	1w	
16	ABPC	Streptococcus		5.7	5.5	6.0	1.27	0.48	0.18	5w	
17	MEPM			7.5	6.8	6.0	1.06	0.06	0.13	1w	
18			S.epidermis	9.5	6.5	5.5	1.02	0.15	0.07	2w	
19				10.4	9.9	9.6	0.76	0.14	0.04	1w	
20	VCM		MRSA	4.5	4.2	7.9	2.92	0.81	3.6	Failed	3Mo after PED
21				6.7	8.9	5.9	5.57	1.4	0.22	5w	
22	CEZ	MSSA		8.0	4.8	4.6	1.3	1.51	0.35	Failed	
23	CEZ			2.1	8.4	6.7	0.11	1.06	0.09	6w	
24			GPC	12.3	9.5	10.6	9.22	1.5	1.02	Failed	5w after PED

LVFX: levofloxacin; SBT/CPZ: sulbactam/cefoperazone; SBT/ABPC: sulbactam/ampicillin; CTRX: ceftriaxone; CEZ: cefazolin; DRPM: doripenem; VCM: vancomycin; ABPC: ampicillin; MEPM: meropenem; MSSA: methicillin-susceptible *Staphylococcus aureus*; MRSA: methicillin-resistant *Staphylococcus aureus*; S. epidermis: *Staphylococcus epidermidis*; GPC: Gram-positive cocci.

(Figure 1). In those who achieved inflammation control, the average time between PED and negative conversion of CRP level was  $3.9 \pm 2.3$  weeks (Table 4).

The remaining five patients failed to achieve infection control by PED. One such patient, a 75-year-old woman with hepatitis C, was not able to control the infection after PED and died 9 months after surgery (Figure 2(a) to (c)). Another patient who failed PED developed an epidural abscess 2 weeks after PED, requiring additional posterior decompression due to lower extremity palsy. The patient died 3 months after PED (Figure 2(d) to (f)). Remaining three "failed" patients had exacerbations of their infections during the postoperative course and required additional surgery (Figure 2(g) to (o)).

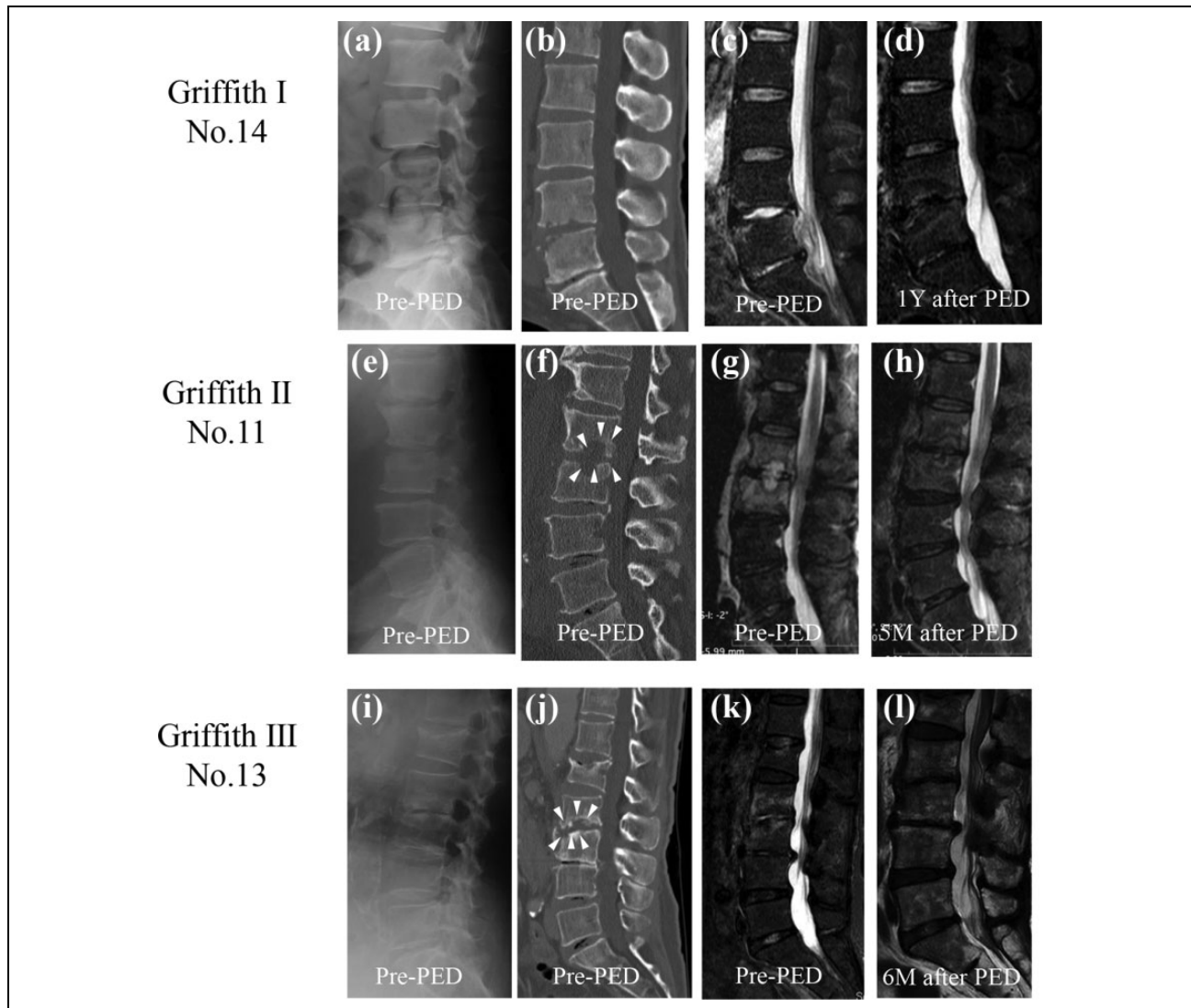
Univariate analyses demonstrated that DM ( $p = 0.05$ ), hemodialysis due to DM-induced renal failure ( $p = 0.02$ ), concomitant malignant disease ( $p = 0.09$ ), and acute onset ( $p = 0.05$ ) were possibly correlated with failure of PED surgery. Stepwise logistic regression analysis revealed that hemodialysis due to DM-induced renal failure was an independent factor associated with PED failure ( $p = 0.03$ ), whereas the other factors we examined, including DM

( $p = 0.1$ ), concomitant malignant diseases ( $p = 0.13$ ), and acute onset ( $p = 0.9$ ), were not significantly associated with PED failure (Table 5).

## Discussion

The present study found that hemodialysis due to DM-induced renal failure was an independent risk factor for PED failure in patients with pyogenic spondylitis. There is a possibility that DM-hemodialysis patients fall into unfavorable outcome regardless of which surgical procedures is performed because DM-hemodialysis patients are extremely immunocompromised. True limitation of PED for pyogenic spondylitis remains unclear.

The traditional treatment of pyogenic spondylitis includes bed rest and administration of antibiotics following an evaluation of blood cultures and tissue biopsy. An additional conservative treatment option is percutaneous puncture and insertion of a drainage tube.<sup>12</sup> However, these conservative therapy options generally lead to prolonged recovery times. Because the mean age of patients with pyogenic spondylitis is rising, reduction in treatment times



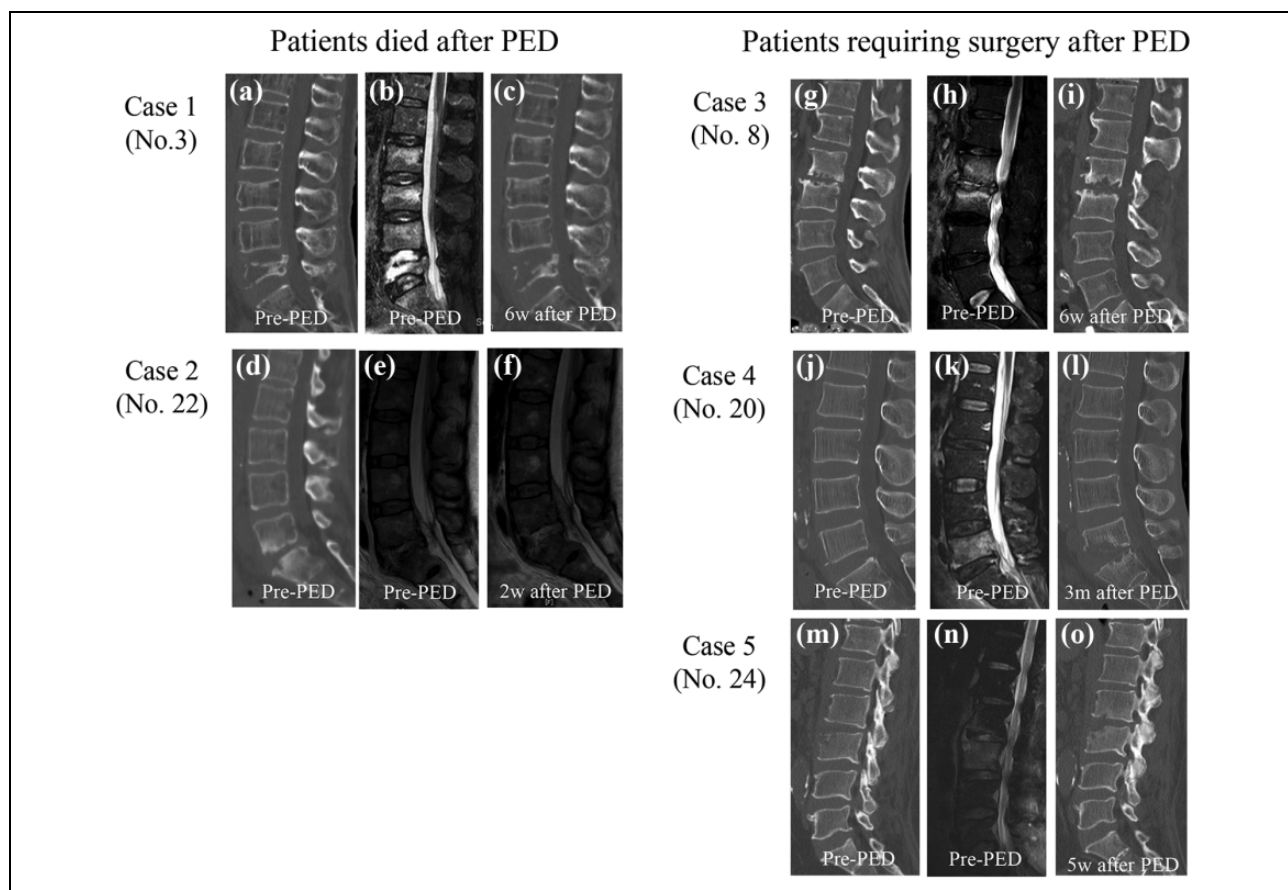
**Figure 1.** Successful patients whose initial X-ray evaluation was graded to Griffith I~III. (a to d) Case No. 14, a 46-year-old man with *Corynebacterium* at L4/5: (a) preoperative radiograph (Griffiths I), (b) preoperative CT, (c) preoperative MRI (T2 weighted), and (d) postoperative MRI (T2 weighted) 1 year after PED. (e to h) Case No. 11, a 63-year-old man with at L2/3: (e) preoperative radiograph (Griffiths II), (f) preoperative CT (arrow head, bone destruction), (g) preoperative MRI (T2 weighted), and (h) postoperative MRI 5 months after PED. (i to l) Case No. 13, a 83-year-old woman with  $\alpha$ -streptococcus spondylodiscitis at L2/3: (i) preoperative radiograph (Griffiths III), (j) preoperative CT (arrow head, bone destruction), (k) preoperative MRI (T2 weighted), and (l) postoperative MRI 6 months after PED. CT: computed tomography; MRI: magnetic resonance imaging; PED: percutaneous endoscopic discectomy.

is desirable. Furthermore, the incidence of pyogenic spondylitis is rising in immunocompromised hosts, such as patients taking oral steroids, diabetic patients, and long-term hemodialysis patients.<sup>13</sup>

Patients with increased susceptibility to infection might be resistant to conventional conservative treatments and thus require surgical intervention.<sup>14</sup> However, it can be difficult to weigh the pros and cons of surgical invasiveness versus efficacy in immunocompromised patients. The surgical invasiveness of extensive lesion curettage and spinal fusion combined with autologous bone grafts cannot be ignored, particularly in immunocompromised patients, although it is a curative surgical procedure for pyogenic

spondylitis. Hence, less invasive surgical procedures such as PED may be a safer option in this patient population.

PED for pyogenic spondylitis has several advantages. First, PED is a minimally invasive procedure and can be performed without extensive soft tissue dissection. Second, tissue collection can be performed under endoscopy, allowing for direct detection of pathogens. Third, intensive curettage and washing of the infection focus can help control the infection, compared with a simple percutaneous puncture and drainage tube insertion. Finally, the PED surgical procedure encourages bleeding from the vertebral endplates<sup>4</sup>, which maximizes the effects of antibiotics. On the other hand, PED for pyogenic spondylitis has several limitations.



**Figure 2.** Failed patients. (a to c) Case 1 (No. 3), a 76-year-old woman at L4/5: (a) preoperative CT, (b) preoperative MRI (T2 weighted), and (c) postoperative CT 6 weeks after PED with recurrent. (d to f) Case 2 (No. 22), a 52-year-old woman with MSSA at L5/S: (d) preoperative CT, (e) preoperative MRI (T2 weighted), and (f) postoperative MRI (T2 weighted) 2 weeks after PED with recurrent epidural abscess. (g to i) Case No. 8, a 58-year-old man at L2/3: (g) preoperative CT, (h) preoperative MRI (T2 weighted), and (i) postoperative CT 6 weeks after PED with recurrent. (j to l) Case No. 20, a 61-year-old man with MRSA at L5/S: (j) preoperative CT, (k) preoperative MRI (T2 weighted), (l) postoperative CT 3 months after PED with recurrent infection and advanced kyphosis. (m to o) Case No. 24, a 71-year-old man with GPC at L2/3: (m) preoperative CT, (n) preoperative MRI (T2 weighted), and (o) postoperative CT approximately 5 weeks after PED with recurrent. CT: computed tomography; MRI: magnetic resonance imaging; PED: percutaneous endoscopic discectomy; MRSA: methicillin-resistant *Staphylococcus aureus*; MSSA: methicillin-sensitive *Staphylococcus aureus*.

First, PED cannot control the intervertebral instability that frequently occurs as a consequence of inflammatory destruction of the vertebral endplates. Second, compared with curettage/bone grafting, PED cannot introduce fresh bone tissue to act as a scaffold for re-vascularization and new bone formation. In spite of these limitations, minimally invasive PED, rather than aggressive surgical treatment, should be considered after failed conservative therapy, especially in immunocompromised patients.<sup>5</sup>

We found that infection was difficult to control in patients with end-stage kidney failure caused by DM. It can be difficult to determine the optimal surgical strategy in such severely immunocompromised patients. In those immunocompromised patients that fail PED, extensive lesion curettage and spinal fusion combined with autologous bone grafts is the next treatment option. However, DM-hemodialysis patients generally have several other severe comorbidities, including coronary artery disease,

liver dysfunction, cerebrovascular diseases, and so on that restrict their ability to tolerate invasive surgical procedures. In this patient population, the optimal choice of surgical procedures remains unclear.

Major limitations of the present study were small number of patients, relatively short-term follow-up and limited outcome measure focusing only to the attenuation of inflammation parameter. Small sample size leads to difficulty in interpretation of the results. Although the analysis of cause of treatment failure is obscure because of the small number of failure patients, we tried to clarify the cause of treatment failure to determine the future direction of our daily clinical practice. Short follow-up period can give rise to incomplete conclusion. In the present study, we only evaluated the attenuation of the inflammatory parameter. Further investigation including clinical outcome measures and radiographic parameters is needed to elucidate true efficacy of PED for pyogenic spondylitis.

**Table 5.** Univariate analysis and stepwise logistic regression.

Univariate analysis	p Value
Age	0.29
Sex	0.23
Acute initiation of symptoms	0.05 <sup>a</sup>
DM	0.05 <sup>a</sup>
HD	0.02 <sup>a</sup>
Malignancy	0.09 <sup>a</sup>
Affected vertebral level	0.18
Vertebral destruction	0.44
Epidural abscess	0.82
Psoas abscess	0.26
Pre-PED CRP level	0.74
Bacterial culture identification	0.48
Stepwise logistic regression	p Value
DM	0.1
HD	0.03 <sup>b</sup>
Malignancy	0.13
Acute initiation of symptoms	0.9

<sup>a</sup>P < 0.1 were possibly correlated with failure of PED surgery.

<sup>b</sup>P < 0.05 was an independent factor associated with PED failure.

## Conclusion

PED might be considered as one of the alternative therapeutic options before invasive radical surgeries for pyogenic spondylitis after failure of standard conservative therapy.

Even by less invasive PED, pyogenic spondylitis patients with DM-hemodialysis showed poor outcome. Further investigation is needed to determine the optimal treatment strategies for pyogenic spondylitis in severely immunocompromised patients.


## Declaration of conflicting interests


The author(s) declared no potential conflicts of interest with respect to the research, authorship, and/or publication of this article.

## Funding

The author(s) received no financial support for the research, authorship, and/or publication of this article.

## ORCID iDs

Mamoru Kono  <https://orcid.org/0000-0003-4978-0813>

Masao Koda  <https://orcid.org/0000-0003-0982-5386>

## References

- Boody BS, Jenkins TJ, Maslak J, et al. Vertebral osteomyelitis and spinal epidural abscess: an evidence-based review. *J Spinal Disord Tech* 2015; 28(6): 316–327.
- BWerner Zimmerli. Vertebral osteomyelitis. *N Engl J Med* 2010; 362: 1022–1029.
- Berbari EF, Kanj SS, Kowalski TJ, et al. 2015 Infectious Diseases Society of America (IDSA) clinical practice guidelines for the diagnosis and treatment of native vertebral osteomyelitis in adults. *Clin Infect Dis* 2015; 61(6): 26–46.
- Ito M, Abumi K, Kotani Y, et al. Clinical outcome of posterolateral endoscopic surgery for pyogenic spondylodiscitis. *Spine* 2007; 32(2): 200–206.
- Verdu-Lopez F, Vanaclocha-Vanaclocha V, Gozalbes-Esterelles L, et al. Minimally invasive spine surgery in spinal infections. *J Neurosurg sci* 2014; 58: 34–56.
- Funayama T, Abe T, Sakane K, et al. Outcomes of percutaneous endoscopic debridement and drainage for septic spondylodiscitis with marked bone destruction. *Internet J Spine Surg* 2014; 9(1): 1–8.
- Yang SC, Fu TS, Chen LH, et al. Percutaneous endoscopic discectomy and drainage for infectious spondylitis. *Int Orthop* 2007; 31: 367–437.
- Pola E, Pambianco V, Autore G, et al. Minimally invasive surgery for the treatment of thoraco lumbar pyogenic spondylodiscitis: indications and outcomes. *Eur Rev Med Pharmacol Sci* 2019; 23(2): 94–100.
- Kulowski J. Pyogenic osteomyelitis of the spine: an analysis and discussion of 102 cases. *J Bone Joint Surg* 1936; 18: 343–364.
- Griffiths HE and Jones DM. Pyogenic infection of the spine. A review of twenty-eight cases. *J Bone Joint Surg* 1971; 53(3): 383–391.
- Gouliouris T, Aliyu SH, and Brown NM. Spondylodiscitis: update on diagnosis and management. *J Antimicrob Chemother* 2010; 65(3): 11–24.
- Fu TS, Yang SC, Tsai TT, et al. Percutaneous endoscopic debridement and drainage in immunocompromised patients with complicated infectious spondylitis. *Minim Invasive Ther Allied Technol* 2010; 19(1): 42–47.
- Yoshimoto M, Takebayashi T, Kawaguchi S, et al. Pyogenic spondylitis in the elderly: a report from Japan with the most aging society. *Eur Spine J* 2011; 20(4): 649–654.
- Fukuda K, Miyamoto H, Uno K, et al. Indications and limitations of conservative treatment for pyogenic spondylitis. *Clin Spine Surg* 2014; 27: 316–320.