

# Chronic myelitis associated with zoster sine herpette

## A case report

Zenshi Miyake, MD, PhD, Yasushi Tomidokoro, MD, PhD\*, Seitaro Nohara, MD, Akira Tamaoka, MD, PhD

### Abstract

**Rationale:** Neurological complications of varicella-zoster virus (VZV) infection include cerebral infarction, meningoencephalitis, segmental sensory disturbance, facial nerve palsy, and myelitis. Chronic myelitis is rarely reported. Diagnosis of VZV infection can be confirmed by elevated anti-VZV immunoglobulin G (IgG) antibody or detection of VZV DNA in the cerebrospinal fluid (CSF), the former reported to be superior. The detection rate of VZV DNA is generally thought to decrease with time after the onset of the condition. The utility of VZV DNA polymerase chain reaction (PCR) is thus thought to be limited to the acute phase of the disease. The presence of skin lesions also helps to render a diagnosis; however, cases of zoster sine herpette (ZSH), the occurrence of segmental symptoms without skin lesions, renders the diagnosis of VZV infection more difficult. Antiviral drugs, such as acyclovir, are the treatment of choice to resolve VZV infections.

**Patient concerns:** A 65-year-old Japanese man felt heaviness and a throbbing pain on the ulnar side of the right forearm. He was previously diagnosed with cervical spondylosis, and received nonsteroidal anti-inflammatory drugs with little improvement. Contrast cervical magnetic resonance imaging showed a swelling and an increased signal intensity of the spinal cord, and an enhancing lesion, all of which were suggestive of myelitis.

**Diagnosis:** We found no evidence for diagnoses of sarcoidosis, Behçet disease, multiple sclerosis, or neuromyelitis optica spectrum disorder. The CSF analysis revealed an elevation of the total protein concentration and that the patient was positive for VZV DNA, while anti-VZV IgG was not elevated. The patient was therefore diagnosed with ZSH myelitis.

**Interventions:** We administered acyclovir and valaciclovir as the first therapy. At the time of recurrence, we used high-dose acyclovir, vidarabine, and high-dose methylprednisolone pulse therapy.

**Outcomes:** The patient's dysesthetic pain in the right upper limb improved following the first antiviral therapy. Two months later, he suffered a recurrence, but the second therapy significantly relieved his symptoms.

**Lessons:** VZV infection should be regarded as an important differential diagnosis of chronic myelitis. VZV DNA PCR should be performed even in the chronic phase of the condition to introduce the possibility of antiviral therapy as a treatment option.

**Abbreviations:** AIDS = acquired immunodeficiency syndrome, CSF = cerebrospinal fluid, Gd = gadolinium, HHS = hyperosmolar hyperglycemic syndrome, MO = medulla oblongata, mPSL = methylprednisolone, MRI = magnetic resonance imaging, NTM = nontuberculous mycobacteriosis, PCR = polymerase chain reaction, PSL = prednisolone, VZV = varicella-zoster virus, ZSH = zoster sine herpette.

**Keywords:** acyclovir, chronic myelitis, varicella-zoster virus DNA, vidarabine, zoster sine herpette

Editor: N/A.

This work was partially supported by JSPS KAKENHI [grant number, JP16K15476 and JP16K09664].

The authors have no conflicts of interest to disclose.

Department of Neurology, Division of Clinical Medicine, Faculty of Medicine, University of Tsukuba, Tsukuba, Ibaraki, Japan.

\* Correspondence: Yasushi Tomidokoro, Department of Neurology, Division of Clinical Medicine, Faculty of Medicine, University of Tsukuba, Tennodai 1-1-1, Tsukuba, Ibaraki, 305-8575, Japan (e-mail: tomidy01@md.tsukuba.ac.jp).

Copyright © 2019 the Author(s). Published by Wolters Kluwer Health, Inc. This is an open access article distributed under the terms of the Creative Commons Attribution-Non Commercial-No Derivatives License 4.0 (CCBY-NC-ND), where it is permissible to download and share the work provided it is properly cited. The work cannot be changed in any way or used commercially without permission from the journal.

Medicine (2019) 98:32(e16671)

Received: 13 January 2019 / Received in final form: 27 May 2019 / Accepted: 8 July 2019

<http://dx.doi.org/10.1097/MD.00000000000016671>

## 1. Introduction

The varicella-zoster virus (VZV) is a DNA virus of the herpesvirus family. Its primary infection causes chickenpox, after which the virus establishes a lifelong latency in cranial nerves and the dorsal root ganglia and can reactivate as herpes zoster.<sup>[1]</sup> Neurological complications of herpes zoster include vasculitis-induced cerebral infarction, meningoencephalitis, segmental sensory disturbance, facial-nerve palsy (Hunt syndrome), myelitis, and postherpetic neuralgia.<sup>[2]</sup> While the prevalence of these complications among healthy individuals ranges from 0.1% to 0.3%, it increases to 35% in immunocompromised patients.<sup>[3]</sup>

VZV can cause radicular pain without skin lesions (zoster sine herpette, ZSH), sensorimotor neuropathy, and facial nerve paralysis.<sup>[4]</sup> VZV myelitis often develops within the 3 weeks following the appearance of a skin rash. Diagnosis of the condition can be confirmed with polymerase chain reaction (PCR) detection of VZV DNA in the cerebrospinal fluid (CSF);

the rate of positive detection within 7 to 10 days after the appearance of a rash is 61.5% to 100% but decreases to 25% to 44.4% thereafter.<sup>[2,5,6]</sup> Concerning ZSH, the rate of positive detection is only 43% even within the 10 days following the appearance of a skin lesion.<sup>[6]</sup> The time after onset of VZV myelitis and the absence of skin lesions therefore comprise risk factors of false negatives of PCR detection of VZV DNA in the CSF. VZV DNA PCR is thought to be effective only in the acute phase of the infection, especially in the case of ZSH; however, obtaining sufficient data to even consider ZSH as a potential diagnosis is challenging.

We herein report a rare case of ZSH myelitis, diagnosed using PCR detection of VZV DNA in the CSF despite a lapse of 10 months from the onset of the condition, and discuss the treatment of recurrent VZV myelitis based on the present case and previous reports.

## 2. Case presentation

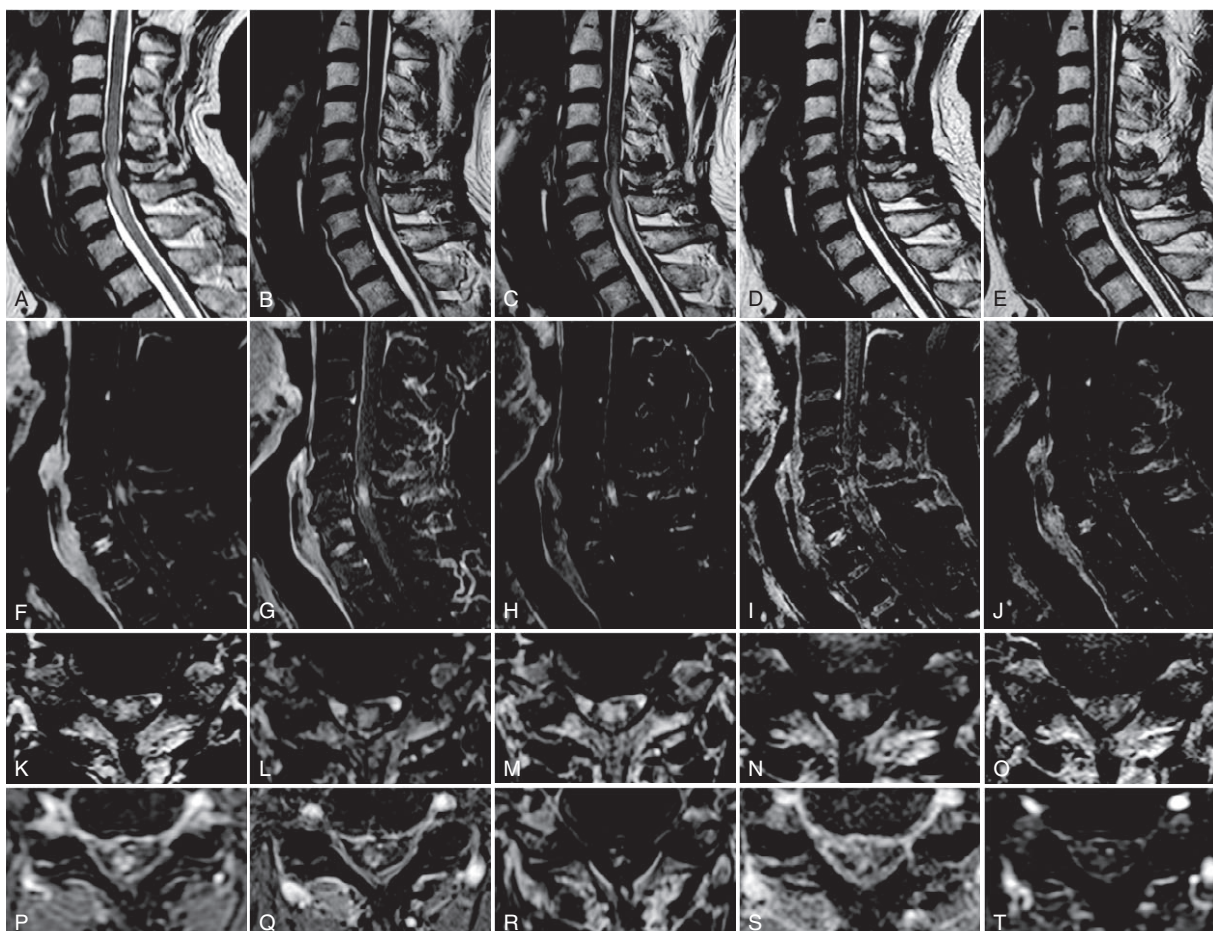
A 65-year-old Japanese man felt heaviness and a throbbing pain on the ulnar side of the right forearm. He consulted an orthopedist and received an X-ray examination of the forearm, which revealed no abnormality. Since his symptoms did not improve naturally, the patient visited another orthopedist 6 months later. Magnetic resonance imaging (MRI) of the cervical spine showed spinal canal stenosis and an abnormal signal of the spinal cord. The patient was diagnosed with cervical spondylosis and took nonsteroidal anti-inflammatory drugs, with little improvement. Concurrently, the patient developed a few skin lesions on the right ring finger as well as flares on the ulnar side of both palms with concomitant pain. He visited a dermatologist and was diagnosed with dyshidrotic eczema, for which topical corticosteroid was prescribed. One month later, he visited another orthopedist who administered a contrast cervical MRI. The examination revealed a cervical swelling at the C6/7 level, an increased T2-weighted signal intensity of the spinal cord at the C4–C7 level, and an enhancing lesion at C6, as well as a spinal canal stenosis at the C5/6–C6/7 level. He was suspected of having myelitis and was admitted to our hospital 10 months after the initial symptoms had appeared.

His past medical history included treatment for hypertension, *Helicobacter pylori* infection, and intraocular pressure elevation. The patient reported no allergies. Our physical examination revealed a body temperature of 36.2°C, blood pressure of 107/69 mm Hg, pulse rate of 73/min, respiration rate of 18/min, and peripheral oxygen saturation of 97% in room air. The general physical examination revealed several papules on the right ring finger and elevated painful erythema on the ulnar side of both palms, which again yielded a diagnosis of dyshidrotic eczema, made by our dermatologist. Ophthalmologic examination revealed no abnormalities, including uveitis and vitreous opacity. He was alert and conscious. Neurological examination revealed no remarkable findings in the cranial nervous system, no muscle weakness or atrophy in any limb, no pathological reflexes, mildly attenuated tendon reflexes in the upper extremities without laterality, exaggerated tendon reflexes in the lower limbs, and right-side dominance. The patient exhibited dysesthesia and paresthesia on the ulnar side of the right hand and mild hypalgesia on the dorsum of both hands.

The complete blood cell count values, and indices of coagulation and fibrinolytic-system functioning were normal. His hemoglobin A1c was 5.8%. Anti-VZV immunoglobulin M

(IgM) enzyme immunoassay (EIA) was 8.1 and anti-VZV immunoglobulin G (IgG) EIA was <2.0. His angiotensin converting enzyme level was 16.5 IU/L; soluble interleukin 2 receptor, 240 U/mL; and lysozyme, 4.4 µg/mL. All were within normal limits. Antinuclear, anti-Sjögren's-syndrome-related antigen A, anti-Sjögren's-syndrome-related antigen B, proteinase 3-anti-neutrophil cytoplasmic, and myeloperoxidase-anti-neutrophil cytoplasmic antibodies were not detected. The patient was also reported to be negative for anti-aquaporin 4 and anti-myelin oligodendrocyte glycoprotein antibodies. Hepatitis B surface antibody was positive, but PCR-detection of hepatitis B virus DNA was negative. Syphilis and human immunodeficiency virus (HIV) were negative. The CSF analysis showed the following: opening pressure of 105 mm H<sub>2</sub>O; 1 cell/µL (100% mononuclear); total protein, 68 mg/dL; glucose, 65 mg/dL (146 mg/dL in the serum); anti-VZV IgM and IgG EIA, <2.0; angiotensin converting enzyme, <1.0 U/mL; soluble interleukin 2 receptor, <50 U/mL; interleukin-6, 1.77 pg/mL; IgG index, 0.52; myelin basic protein, <31.3 pg/mL; and oligoclonal band, negative. Neither the cytology study nor the comprehensive microbiological analyses returned positive results. The type of human leukemia antigen was A31/A24, B62/B52. The electrocardiogram showed no atrioventricular blocks, and the chest X-ray revealed no abnormalities. Computed tomography (CT) showed neither malignancies nor lymphadenopathy, including hilum of lungs; however, nodules at the right segment 3 (S3) and a ground glass opacity at the ipsilateral S6 were noted. The sputum culture was positive for *Mycobacterium avium*. Neither the cranial nor the thoracolumbar MRI revealed abnormalities, whereas the contrast-enhanced cervical MRI showed disk bulging and thickening of the yellow ligaments at the C5/6–C6/7 level, which compressed the dural sac. A hyperintense lesion was observed in the right-dorsal area of the cervical spine at the C6 level on T2-weighted imaging (Fig. 1A and K), with heterogeneous contrast enhancement (Fig. 1F and P). Gallium-67 scintigraphy revealed no abnormal accumulations. No remarkable findings were gleaned from the nerve conduction studies, a visual evoked potential test, or a somatosensory evoked potential test.

We found no indication of sarcoidosis, Behçet disease, multiple sclerosis, or neuromyelitis optica spectrum disorder; we therefore tentatively diagnosed the patient with cryptogenic myelitis complicated with cervical spondylosis. High-dose methylprednisolone (mPSL) pulse therapy (1g/day, for 3 days) was administered with marginal improvement of dysesthesia in the right upper limb, and the patient was discharged. Two weeks later, his symptoms worsened again. The number of VZV DNA in the CSF drawn at the first hospitalization was subsequently found to be 490 copies/mL, and the patient was suspected of having VZV myelitis without skin lesions: ZSH myelitis. He was readmitted to our hospital and was treated with intravenous acyclovir (5 mg/kg/day) for 2 weeks. Six days after the commencement of the therapy, the frequency of dysesthetic pain decreased and the range of the pain declined (Fig. 2). Contrast-enhanced cervical MRI showed shrinkage of the spinal lesion and attenuation of the contrast enhancement (Fig. 1B, G, L, and Q). The patient was further treated with high-dose mPSL pulse therapy followed by oral prednisolone (PSL) (30 mg/day), which was followed by a slight worsening of the pain. PSL was ended gradually, and the patient received oral valaciclovir (300 mg/day) for 1 week and pregabalin (gradually increased up to 375 mg/day) while the intermittent pain around the little finger persisted. The patient only experienced slight dysesthetic pain on discharge, but



**Figure 1.** (A–E) Magnetic resonance images of the cervical spine. The first row shows the T2-weighted midsagittal images; the second, gadolinium-enhanced T1-weighted midsagittal images; the third, T2-weighted axial images at the C6/7 level; the fourth, gadolinium-enhanced T1-weighted axial images at the same level as the third. (A) On the first admission: high intensity lesion was at the C5–C7 level, with partial gadolinium enhancement. (B) After treatment with acyclovir (5 mg/kg/day, 14 days) and valacyclovir (3000 mg/day, 7 days): the cervical lesion was reduced and the gadolinium enhancement was attenuated. (C) On the third admission: the expansion of the cervical lesion and its enhancement were seen. (D) After treatment with acyclovir (30 mg/kg/day, 14 days): the cervical lesion was slightly reduced. (E) After treatment with vidarabine (15 mg/kg/day, 10 days): the gadolinium enhancement at the C6 level was weakened.

his symptoms worsened again 2 months later. Enlargement of the spinal lesion was clearly observed on contrast-enhanced cervical MRI (Fig. 1C, H, M, and R), and the patient was admitted again for treatment. VZV DNA in the CSF was not detected, but based on the clinical course, relapse of ZSH myelitis was strongly suspected. After the administration of 30 mg/kg of acyclovir for 2 weeks, a cervical MRI showed a reduction of the lesion with a remaining but reduced contrast enhancement at the C6 level (Fig. 1D, I, N, and S). We then administered 15 mg/kg of vidarabine for 10 days and high-dose mPSL pulse therapy. The patient reported that the dysesthetic pain in the right arm was reduced to about 10% to 20% of that at the time of hospitalization. Cervical MRI revealed attenuation of the contrast enhancement (Fig. 1E, J, O, and T). Following discharge, he continued to regularly visit our hospital; there was no worsening of the pain.

As this is a case report, obtaining of ethical approval was not necessary. The patient and his family provided written informed consent for the publication of his clinical data. The presented data are anonymized and the risk of identification is minimal.

### 3. Discussion

We herein report the case of a patient with VZV-associated chronic myelitis who developed dysesthetic pain on the right upper limb and whose diagnosis was ascertained using VZV DNA PCR of the CSF. Spinal MRI of patients with VZV myelitis is often reported to exhibit a low signal in T1-weighted images, a high signal in T2-weighted images, and gadolinium (Gd) enhancement. The contrast enhancement is considered to be an especially useful indicator of inflammation or necrosis of the spinal lesion.<sup>[4,7]</sup> Akin to previous reports, our patient was found to exhibit a cervical lesion with an abnormal signal and Gd enhancement; however, it was challenging to distinguish myelitis from cervical spondylosis because the spinal lesion was situated at the stenotic site of the spinal canal. Kang et al<sup>[8]</sup> previously reported a case of segmental zoster paresis, in which the patient suffered from muscle weakness in the left upper limb. The cervical MRI performed localized the spinal lesion to the same level as the spinal canal stenosis, rendering the diagnosis of myelitis difficult. In their case, CSF analysis was not performed because the patient did not provide consent.<sup>[8]</sup> In the present case,

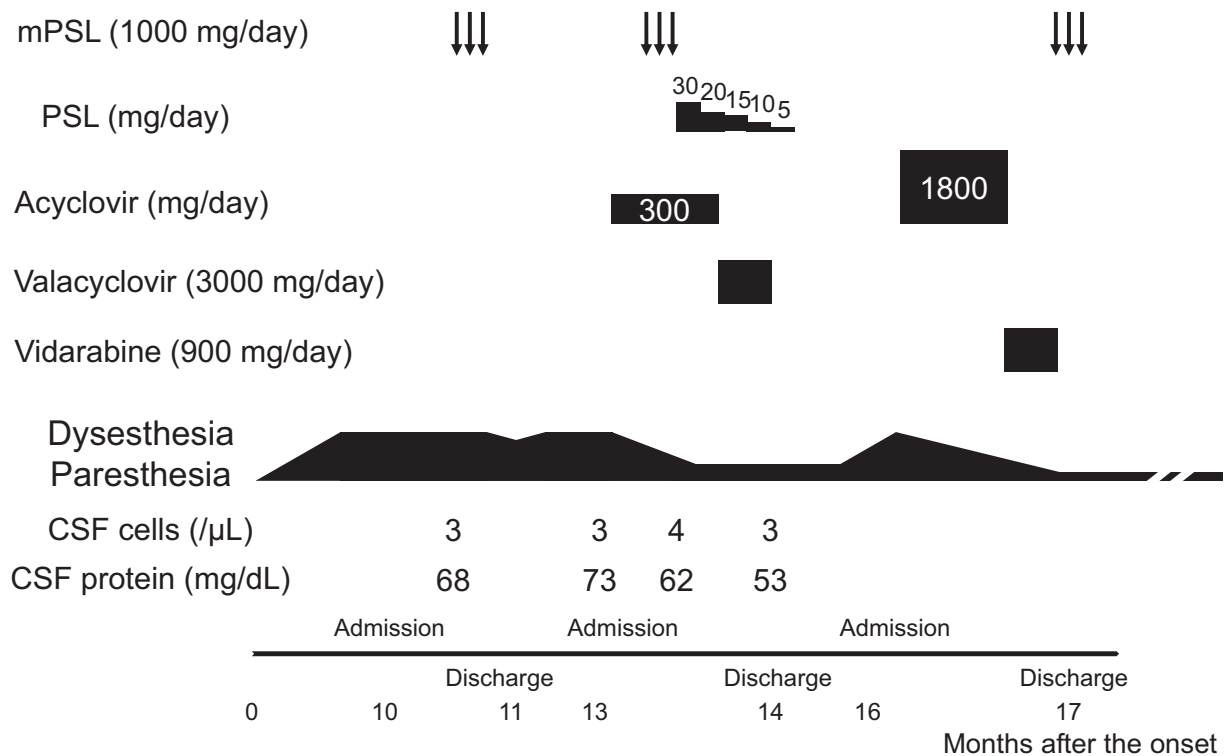


Figure 2. Clinical course. CSF = cerebrospinal fluid, mPSL = methylprednisolone, PSL = prednisolone.

administration of antiviral medicine dramatically improved the patient's clinical symptoms and reduced his cervical spinal lesion, suggesting that VZV-associated myelitis was the main cause of the dysesthetic pain in his arm; however, the possibility that cervical spondylosis partially contributed to his symptoms remains. Careful differentiation of viral myelitis and cervical spondylosis is required because the conditions require entirely different treatment strategies.

Neurological complications of VZV infection are often associated with immunodeficient conditions; malignant lymphoma, leukemia, metastatic tumor, HIV infection, renal failure, and systemic lupus erythematosus have been identified as the contributory diseases.<sup>[9]</sup> Patients with these diseases often exhibit

ZSH, VZV-associated neurologic symptoms without rash, and the consequent symptoms: sensory and/or motor neuropathies, facial nerve paralyses, and/or persistent radicular pain.<sup>[10]</sup> On the other hand, ZSH without immunodeficiency, as was exhibited in our patient, has also been reported.<sup>[10,11]</sup> Our systemic analyses revealed neither HIV infection nor malignancy, and although chest CT and sputum culture revealed that our patient had nontuberculous mycobacteriosis, this finding did not indicate severe immunodeficiency.

We compared the present case with prior reports of ZSH myelitis (Table 1).<sup>[11–17]</sup> In our case, the proximity of the spinal lesion to the posterior funiculus likely accounts for the patient not having experienced muscle weakness in the extremities. The

Table 1

Comparison of the present findings with those of previous studies on zoster sine herpete myelitis.

References	Age	Sex	Underlying disease	Period from onset to treatment	Movement disorder	MRI level	CSF		Treatment	Outcome
							Cell (/μL)	Protein (mg/dL)		
Heller et al 1990 <sup>[11]</sup>	31	M	None	23 days	Paraplegia	T12	23	136	A, S	0
Chrétien et al 1993 <sup>[12]</sup>	30	M	AIDS	1 month	None	C3–7	210	2380	C	2
Gray et al 1994 <sup>[13]</sup>	42	M	AIDS	3 days	Paraplegia	C4–7	76	High	G	2
Meylan et al 1995 <sup>[14]</sup>	35	M	AIDS	3 weeks	Paraplegia	T9–10	32	684	U	2
Manian et al 1995 <sup>[15]</sup>	41	M	AIDS	2 months	Tetraplegia	MO upper C	20	Normal	A	1
Inukai et al 2010 <sup>[16]</sup>	55	F	None	1 month	None	C2	1	19	A, VA, S	0
Hung et al 2012 <sup>[17]</sup>	77	M	HHS	Acute	Paraplegia	None	U	U	None	0
Present case	65	M	NTM	13 months	None	C5–7	1	68	A, VA, S	0

0 = good outcome, 1 = poor outcome, 2 = death, A = acyclovir, AIDS = acquired immunodeficiency syndrome, C = anti-cytomegalovirus drug, C = cervical, CSF = cerebrospinal fluid, F = female, G = ganciclovir, HHS = hyperosmolar hyperglycemic syndrome, M = male, MRI = magnetic resonance imaging, NTM = nontuberculous mycobacteriosis, S = steroid, T = thoracic, MO = medulla oblongata, U = unknown, VA = valacyclovir.

present case was characteristic of the mild and chronic course of myelitis with a longer period from onset to treatment, while majority of the cases were acute or subacute course of the disease, and often lethal. The CSF findings were mild in our case, with only slight elevation of proteins without pleocytosis, making the consideration of VZV myelitis as a differential diagnosis more difficult in our case. In contrast, the majority of the other cases demonstrated pleocytosis and elevation of proteins, a more typical CSF presentation of VZV myelitis.<sup>[18]</sup> Although detection of VZV DNA in the CSF is useful for the diagnosis of VZV myelitis,<sup>[2]</sup> the detection rate of VZV DNA reportedly declines with time after the onset.<sup>[5,6]</sup> Hence, the detection of VZV DNA in the CSF in the present chronic case was surprising. Moreover, the absence of characteristic skin lesions is another risk factor for the failure to detect VZV DNA.<sup>[6]</sup> The possibility of contamination was not likely because, in contrast to the first round of mPSL pulse therapy, the administration of acyclovir and valaciclovir significantly improved the patient's clinical symptoms and reduced his cervical lesion. Interestingly, the clinical picture in our case was almost identical to the 2 milestone cases of ZSH reported by Gildeen et al that were the first 2 cases of ZSH demonstrating VZV DNA in the CSF, providing virological evidence of ZSH to establish ZSH as the clinical variant of VZV infection.<sup>[10]</sup> VZV DNA was detected in the CSF 5 and 8 months after the onset of radicular pain, with a chronic disease course, no pleocytosis and no/mild elevation of proteins in the CSF.<sup>[10]</sup> Thus, VZV DNA PCR of the CSF remains useful even in cases of chronic myelitis. Although the detection of anti-VZV IgG antibody in the CSF is reported to be superior to VZV DNA PCR of the CSF for the diagnosis of VZV vasculopathy, recurrent myelopathy, and brainstem encephalitis produced by VZV,<sup>[18,19]</sup> cases such as ours indicate that both VZV DNA PCR and anti-VZV IgG antibody in the CSF must be tested to exclude chronic VZV myelitis.<sup>[18]</sup>

Administration of acyclovir can effectively treat cases of VZV myelitis without severe immunodeficiency.<sup>[8,13,14]</sup> On the other hand, there have been several reports concerning recurrent VZV myelitis, for which there is no established treatment strategy<sup>[7,18,20]</sup>; acyclovir has mainly been used, while valaciclovir and famciclovir have been proposed as alternative candidates for treatment.<sup>[9,19,20]</sup> In the present case, we first treated the patient with 15 mg/kg of intravenous acyclovir for 2 weeks and 3 g of oral valaciclovir for 1 week, but he suffered a recurrence 2 months after the therapy. We then administered 30 mg/kg of acyclovir, the dosage used to treat VZV encephalitis, for 2 weeks and 15 mg/kg of vidarabine for 10 days; this strategy has hitherto forestalled recurrence. Therefore, a sufficient dosage of acyclovir and addition of vidarabine may be effective for the treatment of recurrent VZV myelitis. The use of steroids in addition to antiviral drugs is also reportedly effective for the improvement of clinical symptoms associated with VZV infection.<sup>[10,15]</sup> In our case, high-dose mPSL therapy evinced the limited effect of the slight relief of the patient's dysesthetic pain, possibly due to reduction of the spinal edema. Oral corticosteroids did not improve his condition; it is therefore doubtful that continuous administration of steroids improves prognosis.

#### 4. Conclusion

Diagnosis of ZSH myelitis was made possible in the present case via the detection of VZV DNA in the CSF despite the relatively

long period between the onset and diagnosis. In addition, antiviral drugs significantly relieved the patient's symptoms and reduced the cervical spinal lesion. A diagnosis of VZV infection should be considered even in cases of chronic myelitis.

#### Acknowledgments

The authors appreciate Editage for English proofreading.

#### Author contributions

**Conceptualization:** Yasushi Tomidokoro.

**Funding acquisition:** Yasushi Tomidokoro, Akira Tamaoka.

**Investigation:** Zenshi Miyake, Yasushi Tomidokoro, Seitaro Nohara.

**Project administration:** Yasushi Tomidokoro.

**Software:** Yasushi Tomidokoro.

**Supervision:** Akira Tamaoka.

**Validation:** Yasushi Tomidokoro.

**Writing – original draft:** Zenshi Miyake.

**Writing – review & editing:** Yasushi Tomidokoro.

#### References

- [1] Pergam SA, Limaye AP. Varicella zoster virus (VZV). *Am J Transplant* 2009;9(Suppl 4):S108–15.
- [2] Gildeen DH, Kleinschmidt-DeMasters BK, LaGuardia JJ, et al. Neurologic complications of the reactivation of varicella-zoster virus. *N Engl J Med* 2000;342:635–45.
- [3] Bkanchardiere AD, Rozenberg F, Caumes E, et al. Neurological complications of varicella-zoster virus infection in adults with human immunodeficiency virus infection. *Scand J Dis* 2000;32:263–9.
- [4] Gildeen DH, Beinlich BR, Rubinstien EM, et al. Varicella-zoster virus myelitis: an expanding spectrum. *Neurology* 1994;44:1818–23.
- [5] Gregoire SM, van Pesch V, Goffette S, et al. Polymerase chain reaction analysis and oligoclonal antibody in the cerebrospinal fluid from 34 patients with varicella-zoster virus infection of the nervous system. *J Neurol Neurosurg Psychiatry* 2006;77:938–42.
- [6] Echevarria JM, Casas I, Tenorio A, et al. Detection of varicella-zoster virus-specific DNA sequences in cerebrospinal fluid from patients with acute aseptic meningitis and no cutaneous lesions. *J Med Virol* 1994;43:331–5.
- [7] Hirai T, Korogi Y, Hamatake S, et al. Case report: Varicella-zoster virus myelitis: serial MR findings. *Br J Radiol* 1996;69:1187–90.
- [8] Kang SH, Song HK, Jang Y. Zoster-associated segmental paresis in a patient with cervical spinal stenosis. *J Int Med Res* 2013;41:907–13.
- [9] Gildeen DH. Varicella zoster virus and central nervous system syndromes. *Herpes* 2004;11(Suppl 2):89A–94A.
- [10] Gildeen DH, Wright RR, Schneck SA, et al. Zoster sine herpete, a clinical variant. *Ann Neurol* 1994;35:530–3.
- [11] Heller HM, Carnevale NT, Steigbigel RT. Varicella zoster virus transverse myelitis without cutaneous rash. *Am J Med* 1990;88:550–1.
- [12] Chrétien F, Gray F, Lescs MC, et al. Acute varicella-zoster virus ventriculitis and meningo-myelo-radiculitis in acquired immunodeficiency syndrome. *Acta Neuropathol* 1993;86:659–65.
- [13] Gray F, Belec L, Lescs MC, et al. Varicella-zoster virus infection of the central nervous system in the acquired immune deficiency syndrome. *Brain* 1994;117:987–99.
- [14] Meylan PR, Miklossy J, Iten A, et al. Myelitis due to varicella-zoster virus in an immunocompromised patient without a cutaneous rash. *Clin Infect Dis* 1995;20:206–8.
- [15] Manian FA, Kindred M, Fulling KH. Chronic varicella-zoster virus myelitis without cutaneous eruption in a patient with AIDS: report of a fatal case. *Clin Infect Dis* 1995;21:986–8.
- [16] Inukai A, Katayama T, Kenjo M, et al. A patient with myelitis of varicella-zoster without skin lesions: diagnostic value of virus antibody index in CSF. *Rinsho Shinkeigaku* 2010;50:634–40.

- [17] Hung CH, Chang KH, Kuo HC, et al. Features of varicella-zoster virus myelitis and dependence on immune status. *J Neurol Sci* 2012;318:19–24.
- [18] Gildea D, Nagel MA, Cohrs RJ, et al. The variegated neurological manifestations of varicella zoster virus infection. *Curr Neurol Neurosci Rep* 2013;13:374.
- [19] Haug A, Mahalingam R, Cohrs RJ, et al. Recurrent polymorphonuclear pleocytosis with increased red blood cells caused by varicella zoster virus infection of the central nervous system: case report and review of the literature. *J Neurol Sci* 2010;292:85–8.
- [20] Baik JS, Kim WC, Heo JH, et al. Recurrent herpes zoster myelitis. *J Korean Sci* 1997;12:360–3.