


CASE REPORT

Mexiletine infusion challenge test for neonatal long QT syndrome with 2:1 atrioventricular block

Hajime Okuwaki MD¹ | Yoshiaki Kato MD, PhD^{1,2}  | Lisheng Lin MD, PhD¹ |
Yoshihiro Nozaki MD, PhD¹ | Miho Takahashi-Igari MD¹ | Hitoshi Horigome MD, PhD¹

¹Department of Child Health, Faculty of Medicine, University of Tsukuba, Tsukuba, Japan

²Division of Pediatric Cardiology, National Cerebral and Cardiovascular Center, Suita, Japan

Correspondence

Yoshiaki Kato, Division of Pediatric Cardiology, National Cerebral and Cardiovascular Center, 5-7-1 Fujishiro-Dai, Suita, Osaka 565-8565, Japan.
Email: kato.yoshiaki@ncvc.go.jp

Abstract

For applying a genotype-based treatment in neonatal long QT syndrome (LQTS), early detection of the genotype becomes an important issue. We report a case of a neonate with LQTS type 3 that presented with 2:1 atrioventricular block and underwent a mexiletine infusion challenge test, and achieved shortening of the QTc and 1:1 atrioventricular conduction. The mexiletine infusion challenge test was helpful to make an early detection of the genotype of the LQTS and predicted the drug efficacy in a neonatal patient.

KEYWORDS

atrioventricular block, long QT syndrome, mexiletine, neonate

1 | INTRODUCTION

Long QT syndrome (LQTS) causes sudden cardiac death due to ventricular arrhythmias such as Torsades de Pointes (TdP) or ventricular fibrillation (VF). Functional 2:1 atrioventricular block (AVB), one of the malignant forms of arrhythmias in LQTS, is most frequently observed in neonates with LQTS type 2 or 3.¹ In LQTS type 3 (LQT3), a gain-of-function mutation is observed in the *SCN5A* gene encoding the α -subunit of the cardiac voltage-dependent sodium channel. Mexiletine, a sodium channel blocker, is considered to be effective for patients with LQT3.² Intravenous mexiletine for arrhythmias is commercially available and is covered by the health insurance system in Japan. We report a neonatal LQT3 case that underwent a mexiletine infusion challenge test for the diagnosis and prediction of its efficacy.

2 | CASE REPORT

A female infant was delivered at a gestational age of 37 weeks with a birth weight of 3,068 g. The results of fetal nonstress test and fetal

echocardiogram were normal. On the second day after birth, the patient presented with transient bradycardia (70 bpm). There were no abnormalities in echocardiographic evaluation. The electrocardiogram on day 7 showed a prolongation of the QTc (QTcB (QT correction with Bazett formula) 560 ms, and QTcF (QT correction with Friedericia formula) 541 ms), 2:1 AVB (RR interval, 810 ms), and late-onset type of T waves (Figure 1). No ventricular tachycardia was observed even with bradycardia. At an age of 20 days, a mexiletine infusion challenge test was performed. Mexiletine (2 mg/kg) was infused intravenously for 10 minutes, and the 12-lead ECG was continuously recorded from before the infusion until 2 hours after the infusion. Changes in the ECG parameters (RR and QT intervals) were analyzed in lead V5. Shortening of the QTc (QTcB by 49 ms, and QTcF by 45 ms) without any arrhythmic events was observed 10 minutes after the infusion, and 1:1 atrioventricular conduction was achieved 120 minutes after the infusion (Figure 2). One day after the infusion challenge test, oral administration of mexiletine was initiated (6 mg/kg/day). Mexiletine was gradually increased to 15 mg/kg/day in three divided doses. During the follow-up, a 12-lead ECG and Holter monitoring were repeatedly

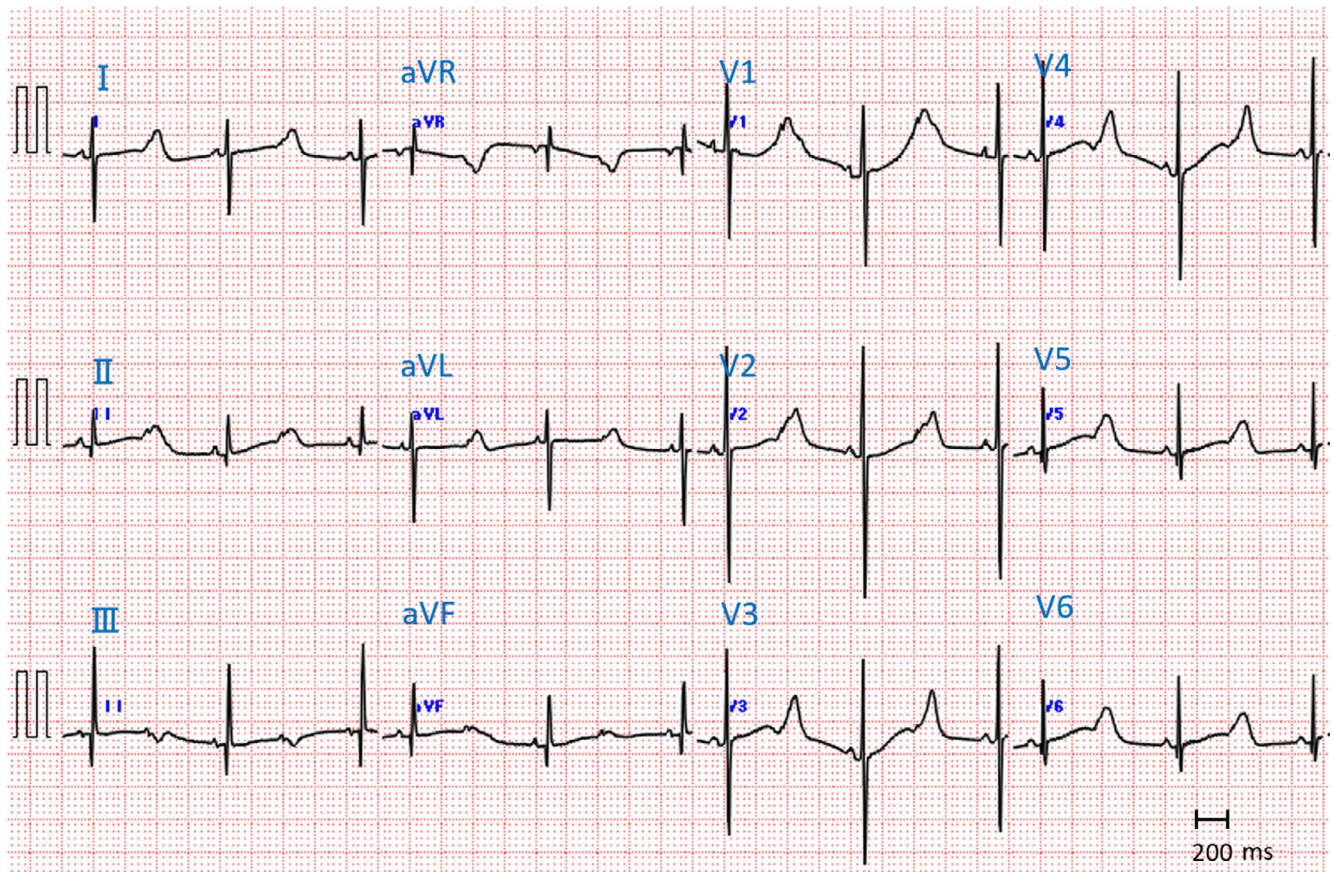


FIGURE 1 Twelve-lead electrocardiogram on day 7 shows 2:1 AVB, prolongation of the QT interval (QT of 502 ms, QTcB (QT correction with Bazett formula) 560 ms, and QTcF (QT correction with Friedericia formula) 541 ms) and late-onset type T waves

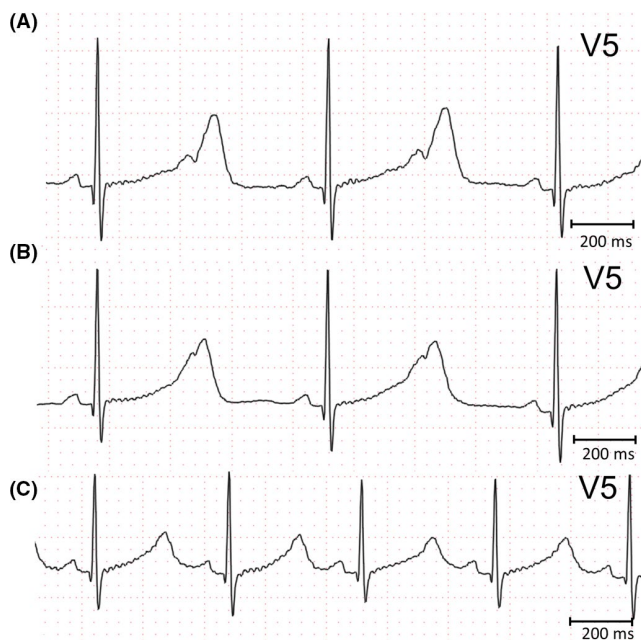


FIGURE 2 A, Before the infusion, RR 750 ms, QT 464 ms, QTcB 536 ms, and QTcF 511 ms. B, Ten minutes after the infusion, RR 766 ms, QT 426 ms, QTcB 487 ms, and QTcF 466 ms. C, Two hours after the infusion, RR 454 ms, QT 322 ms, QTcB 478 ms, and QTcF 419 ms

recorded. The QTc remained in the normal range and 1:1 atrio-ventricular conduction was maintained under the oral mexiletine therapy as of 15 months (Figure 3). No ventricular tachycardia has been observed.

Genetic testing revealed an *SCN5A* gene mutation (Val1763Met), which is a pathogenic mutation of LQT3.³ No mutations in the *SCN5A* gene were found in her parents or brother.

3 | DISCUSSION

For an effective and safe genotype-based treatment choice, an early diagnosis is especially important in patients with lethal arrhythmias in LQTS. Mexiletine has been shown to be effective in preventing TdP and VF in LQT3.² The use of the lidocaine infusion test for an early diagnosis has been reported.⁴ Since an oral mexiletine administration is generally chosen as the maintenance therapy for LQT3, a mexiletine infusion challenge test for a diagnosis and the prediction of the efficacy would be reasonable. Although there have been reports of mexiletine challenge tests in older children and adults,^{5,6} to the best of our knowledge, this case is the first report of an intravenous mexiletine challenge test in a neonate. According to Schwartz⁵, half of the daily dose of oral mexiletine should be administered

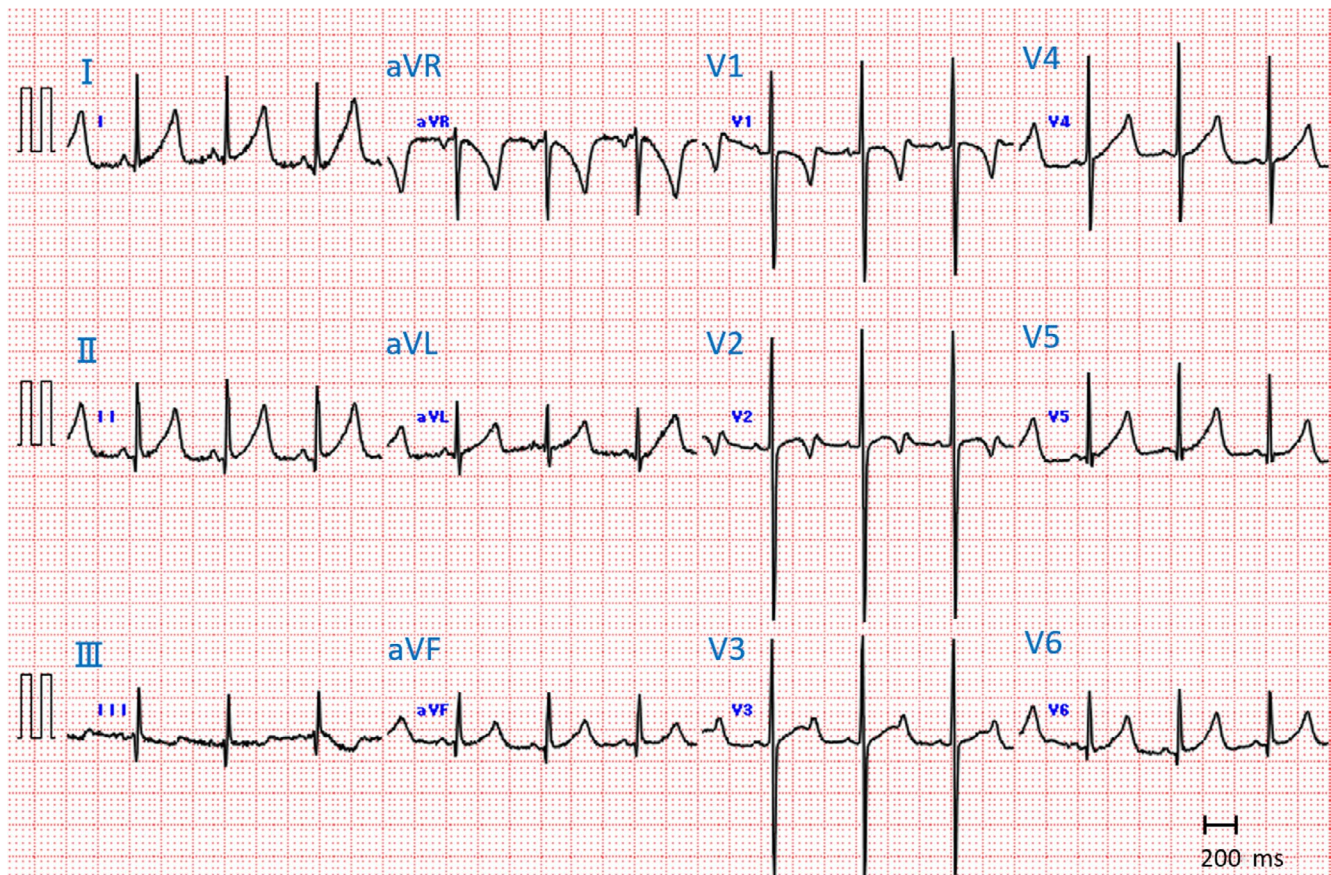


FIGURE 3 The QTc remains within normal range and 1:1 atrioventricular conduction is maintained as of 15 months

and the ECG should be followed for 2 hours. If the QTcB shortens by more than 40 ms and there are no arrhythmic events, mexiletine is judged to be effective. In the present case, we considered that the oral administration of mexiletine could be efficacious because the QTc shortened and 1:1 atrioventricular conduction was restored without any ventricular arrhythmias 2 hours after the test, and therefore, the patient underwent oral mexiletine therapy.

Because mexiletine has minimal side effects involving prolongation of the QT interval, and also has the effect of reducing the dispersion of the repolarization and prevents TdP, the mexiletine challenge test can be performed safely with a low risk of pro-arrhythmic events in LQTS patients.⁶ Mexiletine has the potential of shortening the QT interval in any type of LQTS by inhibiting the late sodium current. Theoretically, mexiletine could also be effective in many LQT2 neonates with 2:1 atrioventricular block at some level, and how to distinguish them might become a problem. Although the optimal cutoff point of the degree of shortening of the QT interval for differentiating LQT3 from the other types of LQTS in neonates is still not clear, the degree of the shortening of the QT interval might be greater in LQT3 than LQT2. While there are some limitations, a mexiletine infusion challenge test in neonates may be useful for the detection of LQT3.

4 | CONCLUSION

The mexiletine infusion challenge test was effective for the prediction of the drug efficacy and for an early diagnosis in a neonate with a malignant form of LQT3.

CONFLICT OF INTEREST

The authors declare no conflict of interests for this article.

ORCID

Yoshiaki Kato  <https://orcid.org/0000-0002-9123-6363>

REFERENCES

1. Horigome H, Nagashima M, Sumitomo N, et al. Clinical characteristics and genetic background of congenital long-QT syndrome diagnosed in fetal, neonatal, and infantile life: a nationwide questionnaire survey in Japan. *Circ Arrhythm Electrophysiol*. 2010;3(1):10–7.
2. Mazzanti A, Maragna R, Faragli A, et al. Gene-specific therapy with mexiletine reduces arrhythmic events in patients with long QT syndrome type 3. *J Am Coll Cardiol*. 2016;67(9):1053–8.
3. Chang CC, Acharfi S, Wu MH, et al. A novel SCN5A mutation manifests as a malignant form of long QT syndrome with perinatal onset of tachycardia/bradycardia. *Cardiovasc Res*. 2004;64(2):268–78.

4. Anderson HN, Bos JM, Kapplinger JD, Meskill JM, Ye D, Ackerman MJ. Lidocaine attenuation testing: An in vivo investigation of putative LQT3-associated variants in the SCN5A-encoded sodium channel. *Heart Rhythm*. 2017;14(8):1173–9.
5. Schwartz PJ, Spazzolini C, Crotti L. All LQT3 patients need an ICD: true or false? *Heart Rhythm*. 2009;6(1):113–20.
6. Funasako M, Aiba T, Ishibashi K, et al. Pronounced shortening of QT interval with mexiletine infusion test in patients with type 3 congenital long QT syndrome. *Circ J*. 2016;80(2):340–5.

How to cite this article: Okuwaki H, Kato Y, Lin L, Nozaki Y, Takahashi-Igari M, Horigome H. Mexiletine infusion challenge test for neonatal long QT syndrome with 2:1 atrioventricular block. *J Arrhythmia*. 2019;35:685–688.
<https://doi.org/10.1002/joa3.12209>