

Title: Abnormal Saccadic Intrusions with Alzheimer's Disease in Darkness

Running title: Pathological Eye Movements with AD

Kiyotaka Nakamagoe,^{a*} MD, PhD; Shiori Yamada^a; Rio Kawakamia;
Tadachika Koganezawa,^b PhD; and Akira Tamaoka,^a MD, PhD

^a Department of Neurology, Division of Clinical Medicine, Faculty of Medicine, University of Tsukuba, Tsukuba, Ibaraki, Japan

^b Department of Physiology, Division of Biomedical Science, Faculty of Medicine, University of Tsukuba, Tsukuba, Ibaraki, Japan

*Corresponding author: Kiyotaka Nakamagoe (K.N.)

Department of Neurology, Division of Clinical Medicine, Faculty of Medicine, University of Tsukuba, Tsukuba, Ibaraki 305-8575, Japan

Tel./Fax: +81-29-853-3224

E-mail: Nakamagoek@md.tsukuba.ac.jp

Orcid.org/0000-0003-4025-5780

Key words: Alzheimer's disease; eye movements; saccadic intrusion; square-wave jerks; visual fixation; higher-order function; inferior parietal lobule; frontal eye field

Abstract

[Background] Classified as saccadic intrusions, square-wave jerks (SWJs) have been observed during visual fixation (VF) in Alzheimer's disease (AD). However, the pathological significance of this phenomenon remains unclear.

[Objective] The present study analyzed the characteristics of SWJs in patients with AD with their eyes open in the dark without VF.

[Methods] Fifteen patients with AD and 15 healthy age- and sex-matched controls were investigated and compared. Saccadic intrusions with and without VF were detected as SWJs and measured using an electronystagmogram.

[Results] No significant difference in frequency of SWJs was observed between Control and AD groups with VF, but significantly more SWJs were observed in the AD group than in the Control group in the absence of VF ($p < 0.01$). In the Control group, the frequency of SWJs was significantly higher with VF as compared to without VF. Conversely, the frequency in the AD group was significantly higher without VF. Furthermore, a direct proportional relationship was observed between the frequency of SWJs and higher-order function ($R > 0.55$) in the AD group.

[Conclusion] SWJs without VF may have pathological significance in AD. In healthy individuals, SWJs are generated by VF and suppressed without VF. Conversely, in AD, SWJs are generated rather than suppressed in the absence of VF. These pathognomonic SWJs without VF also appear to be correlated with higher-order dysfunction, reflecting AD-related cortical damage. These findings suggest that pathological SWJs without VF observed in AD derive from cortical damage and may constitute an important marker of higher-order function.

INTRODUCTION

There have been several reports on relationship of Alzheimer's disease with abnormal ocular movements and disorders of eyeball, retina, optic nerve, and pupil [1-10]. Most of these reports were related to the diagnosis or biomarkers of Alzheimer's disease [1-10]. Furthermore, there was a recent report from a very large population regarding the relevance of eye and retinal diseases, such as glaucoma, diabetic retinopathy, and cataracts, to Alzheimer's disease [11].

Various neurofunctional tests and imaging studies have shown that damage to the inferior parietal lobule (IPL) occurs from the early stages of Alzheimer's disease (AD). In early AD, perfusion and metabolism are impaired in the IPL but are maintained in the occipital lobe and cerebellum [12–14]. Amyloid positron emission tomography (PET) in patients with AD shows marked amyloid deposition in the parietal lobe but no deposition in the occipital lobe or cerebellum [14].

The area of the parietal lobe posterior to the primary somatosensory area, which itself is posterior to the central sulcus, represents the parietal association area. This area is horizontally divided by the intraparietal sulcus into the superior parietal lobule and the IPL. The IPL is composed of Brodmann Areas 39 (the angular gyrus) and 40 (the supramarginal gyrus) and plays an important role in controlling eye movement and vestibular function [15–19]. In patients with AD, IPL damage leads to abnormal vestibular function [1]. Various studies have reported abnormal eye movements associated with AD, including the impairment of smooth pursuit eye movements [1] and saccadic eye movements [2, 3], as well as impaired vestibular function [20].

The IPL is known to play an important role in controlling the generation of saccadic eye movements in coordination with the frontal eye field (FEF) in the prefrontal cortex [15, 16, 21]. Damage to the neural mechanisms controlling saccadic eye movements may lead to the occurrence of a type of square-wave jerks (SWJs) [22–25] classified as saccadic intrusions that have been reported in conjunction with AD [3, 26, 27]. However, recent studies have reported that SWJs in AD are greatly affected by age and are of limited pathological significance [3]. On the other hands, there were reports to using SWJs for evaluating for other disorders, except AD [28, 29].

Cerebral deterioration has been suggested to be linked to the mechanisms underlying SWJs in AD [22]. Therefore, we propose that damage to the IPL and prefrontal cortex, including the FEF, is important to the mechanisms leading to SWJs. If this is indeed the case, damage to the IPL and FEF could be predicted

based on testing eye movements, providing a tool for simple and early detection of AD onset.

The present study investigated the characteristics of SWJs occurring in AD. The relationship between SWJs without visual fixation (VF) and higher-order dysfunction in AD was also investigated.

MATERIALS AND METHODS

Subjects

Fifteen patients with AD (6 men, 9 women; mean age, 71.6±3.7 years) visiting the University of Tsukuba Hospital Neurology Outpatient Department between January 2012 and February 2018 (AD-a group) were compared to 15 age- and sex-matched healthy controls (6 men, 9 women; mean age, 71.6±3.7 years; Control group). Normal higher-order function in the healthy controls was confirmed by a medical interview and neurologic examination. Both Mini-Mental State Examination (MMSE) [30] and Frontal Assessment Battery at Bedside (FAB) [31] were performed in the healthy controls and those diagnosed with AD. MMSE scores reflect cortical function, such as temporal lobe or parietal lobe function; on the other hand, FAB scores reflect damage to the frontal lobe [30, 31]. Table 1 shows the characteristics of each group. No significant difference in mean age was observed between the AD-a and Control groups (Mann-Whitney U test, $p=1.0$; Table 1). To analyze the relationships between abnormal eye movement parameters and Mini-Mental State Examination (MMSE) and Frontal Assessment Battery at Bedside (FAB) scores in the AD group, 22 patients with AD who had previously been confirmed as showing SWJs without VF (10 men, 12 women; mean age, 78.4±7.1 years; mean MMSE score, 20.6±6.8; mean FAB score, 11.3±4.7) who had previously visited the University of Tsukuba Hospital Neurology Outpatient Department were also investigated (AD-b group; Table 2). Patients in the AD-b group included patients in the AD-a group.

Diagnoses of probable AD were confirmed using neurological examinations, MMSE scores, brain magnetic resonance imaging, cerebral blood flow single photon emission computed tomography, and AD diagnostic guidelines based on clinical course [32]. The mean MMSE score in the AD-a group was 21.5±5.7.

Healthy controls who volunteered to participate were interviewed and examined. Inclusion criteria comprised an MMSE score ≥ 24 and the absence of neurological abnormalities (such as cerebellar ataxia) and sensory disturbances (such as limb muscle weakness, extrapyramidal symptoms, and deep sensory disturbance) upon neurological examination. The mean MMSE score in the Control group was 29.0±1.0. Informed consent was obtained from all participants in accordance with the regulations of the University

of Tsukuba Hospital Ethics Committee.

Eye movement tests

Electrodes were fitted horizontally and vertically to the eyelids of participants, then eye movement original waveform (time constant, 3 s) and velocity waveform (time constant, 0.03 s) were recorded in both directions using an electronystagmogram and a data acquisition and analysis device (sampling frequency, 1 kHz; PowerLab; AD Instruments, Castle Hill, Australia).

For the purposes of the present study, SWJs were defined as saccadic intrusions with both an intersaccadic interval ≤ 400 ms and a square form such as Fig.1 before the occurrence of return saccade when either visually fixated on a red laser light in the midline (with VF) or when looking straight ahead with eyes open in the dark (without VF) [33]. For testing without VF, participants were fitted with goggles equipped with an infrared camera (First, Tokyo, Japan) and visually monitored regarding whether the eyes were open or closed. The following parameters of SWJs with and without VF were analyzed: amplitude, intersaccadic interval, and frequency of occurrence (Fig. 1). Patients in whom SWJs did not occur were excluded from the comparative analysis.

RESULTS

Typical SWJs

Figure 2 shows representative SWJs in typical examples of a healthy control and a patient with AD. The frequency of SWJs was clearly higher in the AD group than in the Control group, particularly with eyes open in the dark (without VF) (Fig. 2B,D). In the Control group, the frequency of SWJs was lower without VF than with VF (Fig. 2A,B). The opposite pattern was observed in the AD group, with more SWJs occurring without VF than with VF (Fig. 2C,D).

Comparison of characteristics of SWJs between healthy controls and patients with AD

Table 1 shows the results of a comparative analysis between the Control and AD-a groups. With VF, no significant difference was observed in the frequency of SWJs between groups ($p=0.51$); however, the amplitude was significantly higher in the AD-a group ($p=0.02$). Conversely, without VF, the frequency of occurrence of SWJs was significantly higher in the AD-a group ($p<0.001$). In addition, significant

differences were observed between the groups with regard to amplitude ($p=0.003$) and intersaccadic interval ($p=0.013$). As compared to healthy individuals, in AD, the amplitude was lower and the intersaccadic interval was higher.

Comparison of SWJ characteristics with and without visual fixation in healthy controls and patients with AD

To analyze changes in the parameters of SWJs under differential conditions, such as with or without VF, we analyzed 9 of 15 AD patients and 13 of 15 control subjects who had SWJs with and without VF. On the other hand, 6 of 15 AD patients had no SWJs with VF, and 2 of 15 control subjects had no SWJs without VF. These subjects with no SWJs were excluded from comparative analysis.

Table 3 shows the results of analyzing changes in the parameters of SWJs with and without VF in the Control and AD-a groups. In the Control group, the frequency of SWJs decreased significantly ($p<0.001$), the amplitude increased significantly ($p<0.001$), and the intersaccadic interval shortened significantly ($p=0.03$) without VF as compared to with VF. Conversely, in the AD group, the frequency of SWJs increased significantly without as compared to with VF ($p=0.015$).

Correlation of SWJ frequency without visual fixation and higher-order function in patients with AD

A directly proportional relationship was observed between the frequency of SWJs without VF and MMSE and FAB scores in the AD-b group ($R=0.56$ and $R=0.62$, respectively; Fig. 3). Figure 3 reveals the higher frequency of SWJs and the higher MMSE and FAB scores in the test without VF.

DISCUSSION

SWJs without VF in AD

SWJs typically occur during VF with intersaccadic intervals of 150–200 ms [25]. Based on a report by Abadi et al., the present study defined SWJs as saccadic intrusions with intersaccadic interval ≤ 400 ms (Fig. 1) [33]. Whether saccadic intrusions occurring without VF can be labeled as SWJs remains contentious; however, as shown in the example in Figure 2D, saccadic intrusions resembling SWJs with VF were observed without VF in the present study. Among healthy controls, the frequency of SWJs was lower with eyes open in the dark (without VF) as compared to with VF. Conversely, in patients with AD, SWJs

frequently occurred without VF. Saccadic intrusions without VF were, thus, labeled as SWJs, and the characteristics of this phenomenon were investigated. To the best of our knowledge, no other studies to date have reported SWJs without VF. However, as particular conditions are required to investigate this phenomenon, SWJs with eyes open in the dark (without VF) in AD may have been previously overlooked. Unlike the pattern observed in healthy controls, the frequency of SWJs without VF observed in AD increased, suggesting some degree of pathological significance.

Comparison of present findings and previous reports of SWJs with VF

SWJs have been reported in association with degenerative diseases, specifically multiple-system degeneration and progressive supranuclear palsy, which involves cerebellar and brainstem lesions, and cerebral deterioration in AD [22, 23, 26, 34]. However, SWJs are also known to occur at low frequency in healthy individuals [35, 36]. In consideration of the effects of aging, the frequency of occurrence is used to determine whether SWJs are pathological. A higher frequency indicates greater pathological significance. According to previous studies, the mean frequency of SWJs in healthy young (mean age, 14 years), middle-aged (mean age, 32 years), and old (mean age, 71 years) individuals is 3, 4.7, and 27 times/min, respectively [35, 36]. Furthermore, a lower frequency was reported in association with cerebral deterioration (27 ± 17 times/min) than with cerebellar disorders (43 ± 24 times/min) [22].

Thus, at ~ 16 times/min, the highest frequency of SWJs in the AD group in the present study cannot be described as pathological during VF. Furthermore, the present study found no significant difference in the frequency of SWJs with VF between the AD and Control groups, and, as in previous studies, no pathological frequency could be confirmed [3, 34].

Mechanism underlying SWJs in AD

The IPL contributes to controlling and suppressing saccadic eye movements in coordination with the FEF. The superior colliculus mediates IPL and FEF control of the neuron groups associated with saccadic eye movements generated by the brainstem [15, 16, 21, 37]. IPL- or FEF-related dysfunction of the superior colliculus in AD may, thus, be linked to abnormal saccadic eye movements, such as SWJs. In addition to damage to the IPL, PET and other studies have demonstrated that damage to the prefrontal cortex, including the FEF, also occurs from the early stages of AD [38].

Figure 4 shows a theoretical mechanism of SWJ generation in AD primarily due to damage to the IPL and FEF. In a healthy state, VF is enabled by the inhibition of burst neuron activity through the continuous activation of omnipause neurons (OPNs). OPNs also simultaneously suppress abnormal eye movements, allowing for the maintenance of VF (Fig. 4A). As damage to the IPL and FEF progresses in AD, cerebral cortical inhibitory regulation of the superior colliculus weakens, and OPN activity decreases. The resulting increase in burst neuron activity and abnormal firing allows abnormal eye movements in the form of SWJs, preventing normal VF (Fig. 4B).

Mechanism of increased frequency of SWJs without VF in AD

Neuronal activity in the FEF and adjacent areas increases with VF [39–42]. Conversely, when VF is prevented with eyes open in the dark, FEF neuronal activity maintained through VF decreases. This likely further decreases the activity of the superior colliculus neurons, which are regulated by the FEF, facilitating abnormal burst neuron firing and contributing to the increased frequency of SWJs (Fig. 4C).

Correlation between abnormal SWJs and higher-order function in AD

The present findings indicated that SWJs without VF derive from AD-related cortical damage associated with saccadic eye movements. Another unexpected and intriguing finding was that the frequency of SWJs without VF in patients with AD decreased proportionally to the progression of higher order dysfunction measured by MMSE and FAB.

Previous studies have reported a correlation between MMSE scores and the extent of cortical injury in areas such as the IPL and prefrontal cortex, including the FEF, in patients with AD [43]. Furthermore, the extent of prefrontal cortex dysfunction in AD correlated with FAB scores [38]. While the results of MMSE and FAB appear linked to AD-related cortical injury in areas such as the IPL and FEF, these areas are related to saccadic eye movements, and progressive damage leads primarily to symptoms of severe abnormal saccadic eye movement (saccade). Thus, the occurrence of SWJs may have been masked, explaining the inverse correlation with AD progression.

Limitations

This study is limited by a very small number of subjects. No tau or amyloid PET imaging or cerebrospinal

fluid biomarker investigations were performed on patients with AD in the present study. Furthermore, some of the present patients with AD were receiving oral dementia drugs in the form of anticholinesterases or N-methyl-D-aspartic acid receptor antagonists during the study period. No studies to date have investigated the relationship between dementia drugs and the occurrence of SWJs, and the effects of the drugs on the occurrence of SWJs are unclear.

Based on the results of the present study, further longitudinal study is required regarding the correlation between the occurrence of SWJs without VF and tau and amyloid PET imaging findings in patients with AD at the stage of mild cognitive impairment (MCI).

Specifically, the extent of damage to the IPL and FEF needs to be investigated in AD at the MCI stage and the corresponding frequency of SWJs without VF. The occurrence of SWJs without VF could reflect functional cortical damage earlier than can be identified with PET. Confirmation from PET-based imaging that SWJs without VF reflect MCI-related lesions would suggest that the detection of SWJs without VF could be used as a simpler, more cost-effective tool for the early diagnosis of AD as compared to PET.

CONCLUSION

In summary, SWJs without visual fixation were observed in patients with AD in the present study. Different patterns of frequency between healthy individuals and patients with AD under different conditions suggest that these SWJs have pathological significance. The detection of SWJs without visual fixation may be clinically applicable to the diagnosis of AD at an early stage of cortical damage to the IPL and FEF.

ACKNOWLEDGEMENTS

This work was supported by JSPS KAKENHI Grant number JP 26460901.

The authors report no conflicts of interest.

REFERENCES

- [1] Zaccara G, Gangemi PF, Muscas GC, Paganini M, Pallanti S, Parigi A, et al. Smooth-pursuit eye movements: alterations in Alzheimer's disease. *J Neurol Sci* 112: 81-9 (1992).
- [2] Fletcher WA, Sharpe JA. Saccadic eye movement dysfunction in Alzheimer's disease. *Ann Neurol* 20: 464-71 (1986).
- [3] Shakespeare TJ, Kaski D, Yong KX, Paterson RW, Slattery CF, Ryan NS, et al. Abnormalities of fixation, saccade and pursuit in posterior cortical atrophy. *Brain* 138: 1976-91 (2015).
- [4] Moschos MM, Markopoulos I, Chatziralli I, Rouvas A, Papageorgiou SG, Ladas I, et al. Structural and functional impairment of the retina and optic nerve in Alzheimer's disease. *Curr Alzheimer Res* 9:782-8 (2012)
- [5] Frost S, Kanagasingam Y, Sohrabi H, Bourgeat P, Villemagne V, Rowe CC, et al. Pupil response biomarkers for early detection and monitoring of Alzheimer's disease. Frost S, et al. *Curr Alzheimer Res* 10:931-9 (2013)
- [6] Shen Y, Liu L, Cheng Y, Feng W, Shi Z, Zhu Y, et al. Retinal nerve fiber layer thickness is associated with episodic memory deficit in mild cognitive impairment patients. *Curr Alzheimer Res* 11:259-66 (2014)
- [7] Frost S, Guymer R, Aung KZ, Macaulay SL, Sohrabi HR, Bourgeat P, et al. Alzheimer's Disease and the Early Signs of Age-Related Macular Degeneration. *Curr Alzheimer Res* 13:1259-66 (2016).
- [8] Reed BT, Behar-Cohen F, Krantic S. Seeing Early Signs of Alzheimer's Disease Through the Lens of the Eye. *Curr Alzheimer Res* 14:6-17 (2017).
- [9] Shariflou S, Georgevsky D, Mansour H, Rezaeian M, Hosseini N, Gani F, et al. Diagnostic and Prognostic Potential of Retinal Biomarkers in Early On-Set Alzheimer's Disease. *Curr Alzheimer Res* 14:1000-7 (2017)
- [10] Ukalovic K, Cao S, Lee S, Tang Q, Beg MF, Sarunic MV, et al. Drusen in the Peripheral Retina of the Alzheimer's Eye. *Curr Alzheimer Res* 15:743-50 (2018).
- [11] Lee CS, Larson EB, Gibbons LE, Lee AY, McCurry SM, Bowen JD, et al. Associations between recent and established ophthalmic conditions and risk of Alzheimer's disease. *Alzheimers Dement* 15:34-41 (2019).
- [12] Hirao K, Ohnishi T, Hirata Y, Yamashita F, Mori T, Moriguchi Y, et al. The prediction of rapid conversion to Alzheimer's disease in mild cognitive impairment using regional cerebral blood flow SPECT. *Neuroimage* 28: 1014-21 (2005).

- [13] Matsuda H. Role of neuroimaging in Alzheimer's disease, with emphasis on brain perfusion SPECT. *J Nucl Med* 48: 1289-1300 (2007).
- [14] Matsuda H, Imabayashi E. Molecular neuroimaging in Alzheimer's disease. *Neuroimaging Clin N Am* 22: 57-65 (2012).
- [15] Schiller PH, True SD, Conway JL. Deficits in eye movements following frontal eye-field and superior colliculus ablations. *J Neurophysiol* 44: 1175-89 (1980).
- [16] Schiller PH, Sandell JH, Maunsell JH. The effect of frontal eye field and superior colliculus lesions on saccadic latencies in the rhesus monkey. *J Neurophysiol* 57: 1033-49 (1987).
- [17] Faugier-Grimaud S, Ventre J. Anatomic connections of inferior parietal cortex (area 7) with subcortical structures related to vestibulo-ocular function in a monkey (*Macaca fascicularis*). *J Comp Neurol* 280: 1-14 (1989).
- [18] Grüsser OJ, Pause M, Schreiter U. Localization and responses of neurones in the parieto-insular vestibular cortex of awake monkeys (*Macaca fascicularis*). *J Physiol* 430: 537-57 (1990).
- [19] Grüsser OJ, Pause M, Schreiter U. Vestibular neurones in the parieto-insular cortex of monkeys (*Macaca fascicularis*): visual and neck receptor responses. *J Physiol* 430: 559-83 (1990).
- [20] Nakamagoe K, Fujimiya S, Koganezawa T, Kadono K, Shimizu K, Fujizuka N, et al. Vestibular Function Impairment in Alzheimer's Disease. *J Alzheimer's Dis* 47: 185-96 (2015).
- [21] Schiller PH. The effect of superior colliculus ablation on saccades elicited by cortical stimulation. *Brain Res* 122: 154-6 (1977).
- [22] Sharpe JA, Herishanu YO, White OB. Cerebral square wave jerks. *Neurology* 32: 57-62 (1982).
- [23] Rascol O, Sabatini U, Simonetta-Moreau M, Montastruc JL, Rascol A, Clanet M. Square wave jerks in parkinsonian syndromes. *J Neurol Neurosurg Psychiatry* 54: 599-602 (1991).
- [24] Nakamagoe K, Fujizuka N, Koganezawa T, Shimizu K, Takiguchi S, Horaguchi T, et al. Residual central nervous system damage due to organoarsenic poisoning. *Neurotoxicol Teratol* 37: 33-38 (2013).
- [25] Leigh RJ and Zee DS. Diagnosis of nystagmus and saccadic intrusion. Chapter 11; Saccadic intrusions and oscillations. *The Neurology of Eye Movements*. 5th ed. Oxford University Press, Oxford, UK. pp 716-726 (2015).
- [26] Jones A, Friedland RP, Koss B, Stark L, Thompkins-Ober BA. Saccadic intrusions in Alzheimer-type dementia. *J Neurol* 229: 189-94 (1983).

- [27] Schewe HJ, Uebelhack R, Vohs K. Abnormality in saccadic eye movement in dementia. *Eur Psychiatry* 14: 52–3 (1999).
- [28] Tokuda S, Obinata G, Palmer E, Chaparro A. Estimation of mental workload using saccadic eye movements in a free-viewing task. *Conf Proc IEEE Eng Med Biol Soc* 2011:4523-9 (2011).
- [29] Biswas P, Prabhakar G. Detecting drivers' cognitive load from saccadic intrusion. *Transp Res Part F: Traffic Psychol Behav* 54:63-78 (2018).
- [30] Cockrell JR, Folstein MF. Mini-Mental State Examination (MMSE). *Psychopharmacol Bull* 24, 689-92 (1988).
- [31] Dubois B, Slachevsky A, Litvan I, Pillon B. The FAB: a Frontal Assessment Battery at bedside. *Neurology* 55: 1621-6 (2000).
- [32] McKhann GM, Knopman DS, Chertkow H, Hyman BT, Jack CR Jr, Kawas CH, et al. The diagnosis of dementia due to Alzheimer's disease: recommendations from the National Institute on Aging-Alzheimer's Association workgroups on diagnostic guidelines for Alzheimer's disease. *Alzheimer's Dement* 7: 263-9 (2011).
- [33] Abadi RV, Gowen E. Characteristics of saccadic intrusions. *Vision Res* 44: 2675-90 (2004).
- [34] Kapoula Z, Yang Q, Otero-Millan J, Xiao S, Macknik SL, Lang A, et al. Distinctive features of microsaccades in Alzheimer's disease and in mild cognitive impairment. *Age (Dordr)* 36: 535-43 (2014).
- [35] Herishanu YO, Sharpe JA. Normal square wave jerks. *Invest Ophthalmol Vis Sci* 20: 268–72 (1981).
- [36] Salman MS, Sharpe JA, Eizenman M, Lillakas L, To T, Westall C, et al. Saccadic adaptation in children. *J Child Neurol* 21: 1025-31 (2006).
- [37] Komatsu H, Suzuki H. Projections from the functional subdivisions of the frontal eye field to the superior colliculus in the monkey. *Brain Res* 327: 324-7 (1985).
- [38] Lee JH, Byun MS, Sohn BK, Choe YM, Yi D, Han JY, et al. Functional Neuroanatomical Correlates of The Frontal Assessment Battery Performance in Alzheimer Disease: A FDG-PET Study. *J Geriatr Psychiatry Neurol* 28: 184-92 (2015).
- [39] Suzuki H, Azuma M. Prefrontal neuronal activity during gazing at a light spot in the monkey. *Brain Res* 126: 497-508 (1977).
- [40] Suzuki H, Azuma M, Yumiya H. Stimulus and behavioral factors contributing to the activation of monkey prefrontal neurons during gazing. *Jpn J Physiol* 29: 471-89 (1979).

- [41] Barbas H, Mesulam MM. Organization of afferent input to subdivisions of area 8 in the rhesus monkey. *J Comp Neurol* 200: 407-31 (1981).
- [42] Ungerleider LG, Desimone R. Cortical connections of visual area MT in the macaque. *J Comp Neurol* 248: 190-222 (1986).
- [43] Nagahama Y, Nabatame H, Okina T, Yamauchi H, Narita M, Fujimoto N, et al. Cerebral correlates of the progression rate of the cognitive decline in probable Alzheimer's disease. *Eur Neurol* 50: 1-9 (2003).
- [44] Highstein SM, Baker R. Excitatory termination of abducens internuclear neurons on medial rectus motoneurons: relationship to syndrome of internuclear ophthalmoplegia. *J Neurophysiol* 41: 1647-61 (1978).
- [45] Hikosaka O, Igusa Y, Nakao S, Shimazu H. Direct inhibitory synaptic linkage of pontomedullary reticular burst neurons with abducens motoneurons in the cat. *Exp Brain Res* 33: 337-52 (1978).
- [46] Igusa Y, Sasaki S, Shimazu H. Excitatory premotor burst neurons in the cat pontine reticular formation related to the quick phase of vestibular nystagmus. *Brain Res* 182: 451-6 (1980).
- [47] Sasaki S, Shimazu H. Reticulovestibular organization participating in generation of horizontal fast eye movement. *Ann N Y Acad Sci* 374: 130-43 (1981).
- [48] Scudder CA, Kaneko CS, Fuchs AF. The brainstem burst generator for saccadic eye movements: a modern synthesis. *Exp Brain Res* 142: 439-62 (2002).
- [49] Yoshida K, McCrea R, Berthoz A, Vidal PP. Morphological and physiological characteristics of inhibitory burst neurons controlling horizontal rapid eye movements in the alert cat. *J Neurophysiol* 48: 761-84 (1982).
- [50] Yoshida K, Iwamoto Y, Chimoto S, Shimazu H. Saccade-related inhibitory input to pontine omnipause neurons: an intracellular study in alert cats. *J Neurophysiol* 82: 1198-208 (1999).
- [51] Yoshida K, Iwamoto Y, Chimoto S, Shimazu H. Disynaptic inhibition of omnipause neurons following electrical stimulation of the superior colliculus in alert cats. *J Neurophysiol* 85: 2639-42 (2001).

Figure Legends

Figure 1. Schematic diagram of SWJs and relationships among parameters

Schematic diagram of SWJs analyzed in the present study. Investigated parameters comprised amplitude, frequency of occurrence, and intersaccadic interval.

Figure 2. Example electronystagmograms showing SWJs in typical examples of a healthy control and a patient with AD

Figures A and B show electronystagmograms of a healthy 77-year-old woman recorded with and without (i.e., eyes open in the dark) visual fixation (VS), respectively. Figures C and D show electronystagmograms of a 77-year-old woman with AD with and without (i.e., eyes open in the dark) VS, respectively. The top half of each figure shows horizontal eye movements, while the bottom half shows horizontal eye movement velocity. Arrowheads indicate SWJs.

In the Control group, the frequency of SWJs was higher (A) with VS than (B) without VS. In the AD group, the opposite pattern was observed, with higher frequency of SWJs (D) without VS than (C) with VS.

Figure 3. Correlation between the frequency of SWJs without visual fixation and MMSE and FAB scores

The frequency of SWJs was directly proportional to MMSE and FAB scores ($R=0.56$, $p=0.007$ and $R=0.62$, $p=0.002$, respectively).

Figure 4. Theoretical mechanism of square-wave jerk generation in AD

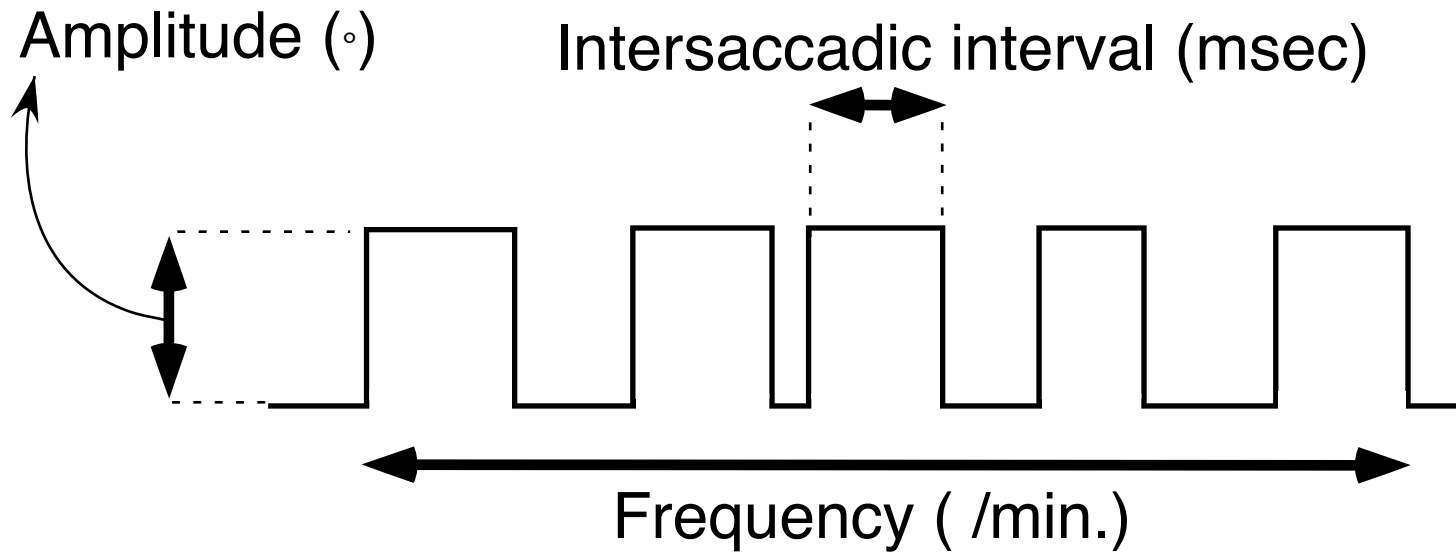
Diagram of the neuronal circuit for saccade generation by the brainstem developed based on previous studies [15, 16, 21, 37, 44–51]. In the absence of saccade commands from the superior colliculus, no excitatory or inhibitory burst neuron activity is present, and these neurons are in a resting state, enabling visual fixation. Meanwhile, the continuous activation of omnipause neurons, another important structural element in saccade generation, inhibits burst neuron activity, maintaining visual fixation and suppressing abnormal eye movements (A).

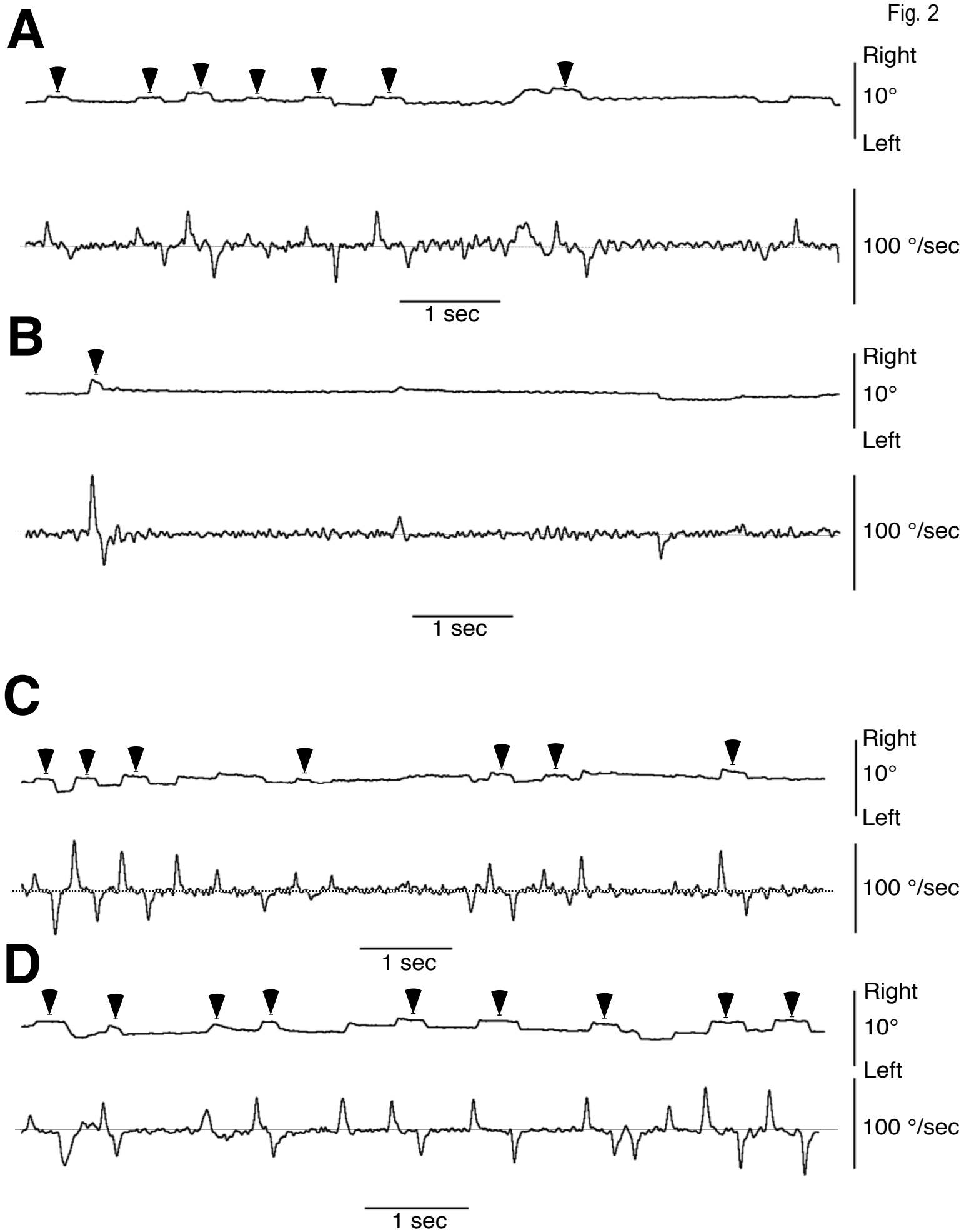
In AD, damage to the IPL and FEF weakens the cerebral cortical inhibitory regulation of the superior colliculus, decreasing omnipause neuron activity. The resulting increase in burst neuron activity generates abnormal square-wave nystagmus in the form of SWJs (B).

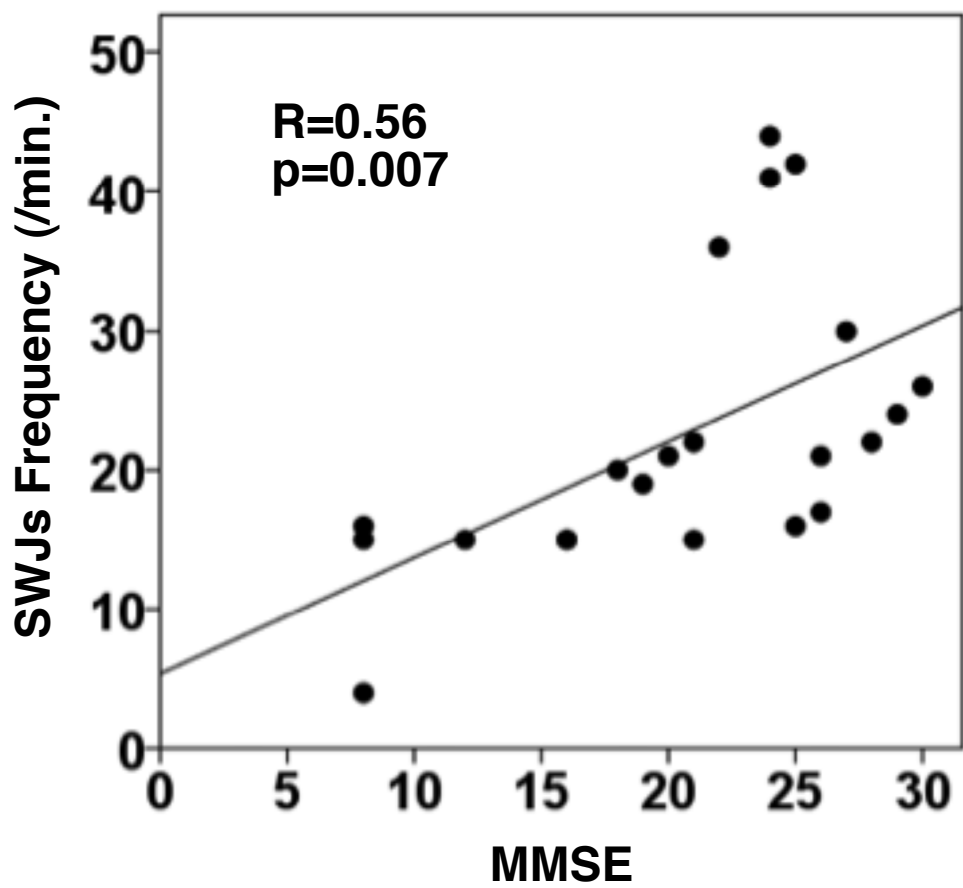
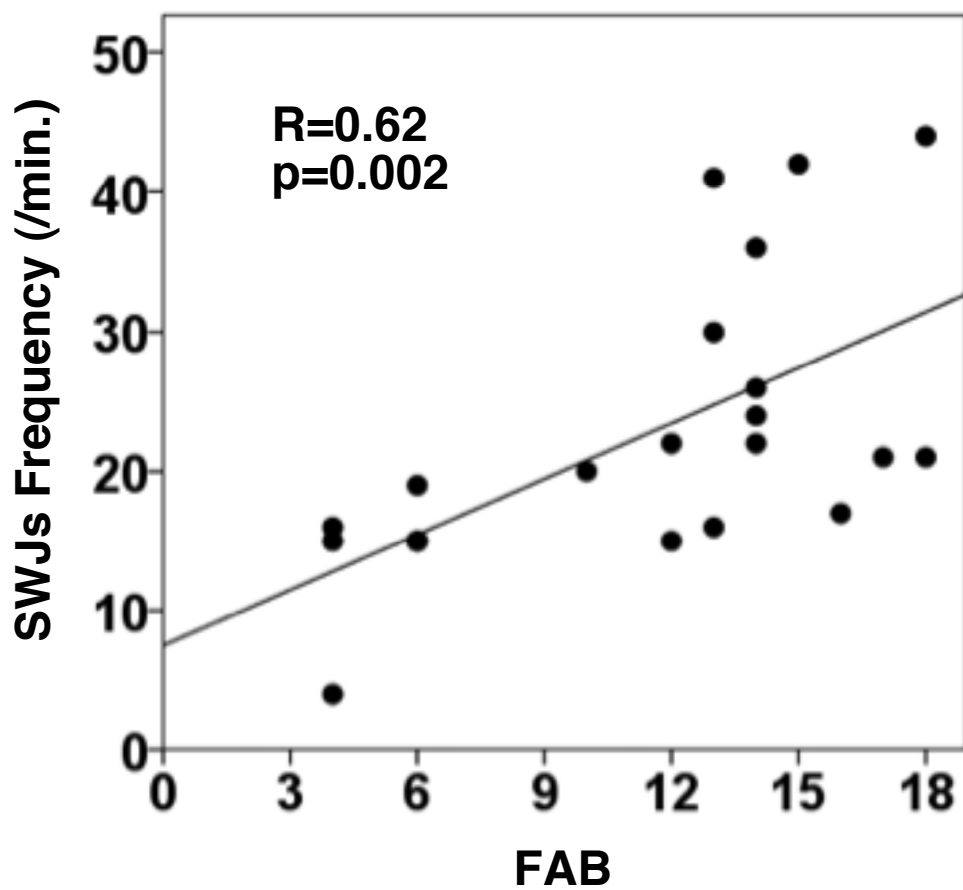
Activity of the FEFs is maintained by visual fixation (VS) and is, therefore, decreased by preventing VS with eyes open in the dark. This further decreases the activity of superior colliculus visual fixation neurons, promoting abnormal activation of the burst neurons and increasing the frequency of SWJs (C).

IPL: inferior parietal lobe; FEF: frontal eye field; OPN: omnipause neuron; EBN: excitatory burst neuron; IBN: inhibitory burst neuron; SC: superior colliculus. White circle (○): excitatory neuron; black circle (●): inhibitory neuron. The size of the lines and arrows indicating input and of the plus and minus signs shows the strength of inhibition and excitation, respectively. The firing rate frequency reflects the amount of neuronal activity.

Square-wave jerks (SWJs)





A**B**

Normal

A

Visual fixation

+

FEF

IPL

SC

Firing activity

Saccade generator

EBN

OPN

Firing activity

No activity

IBN

No activity

Midline

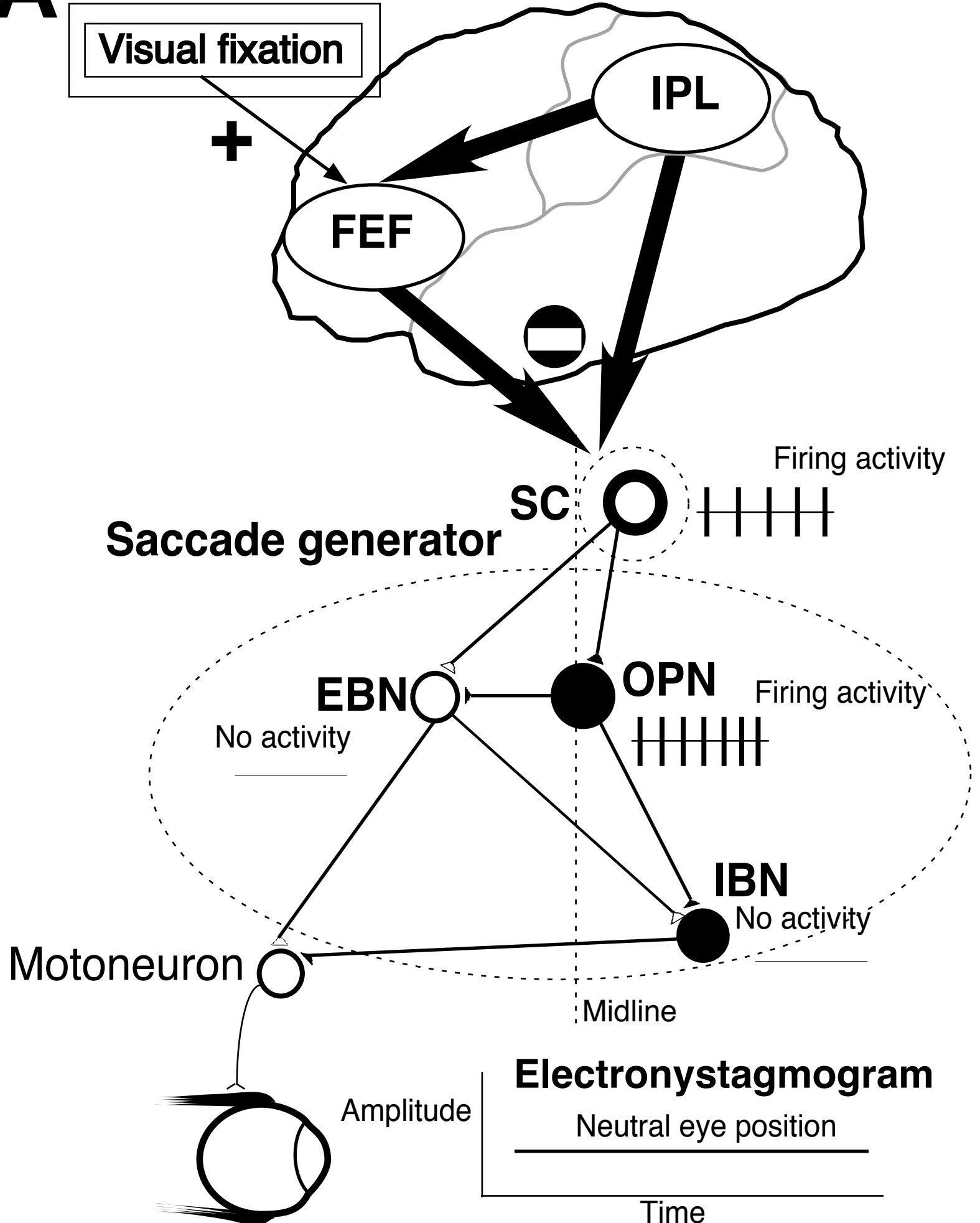
Motoneuron

Electronystagmogram

Amplitude

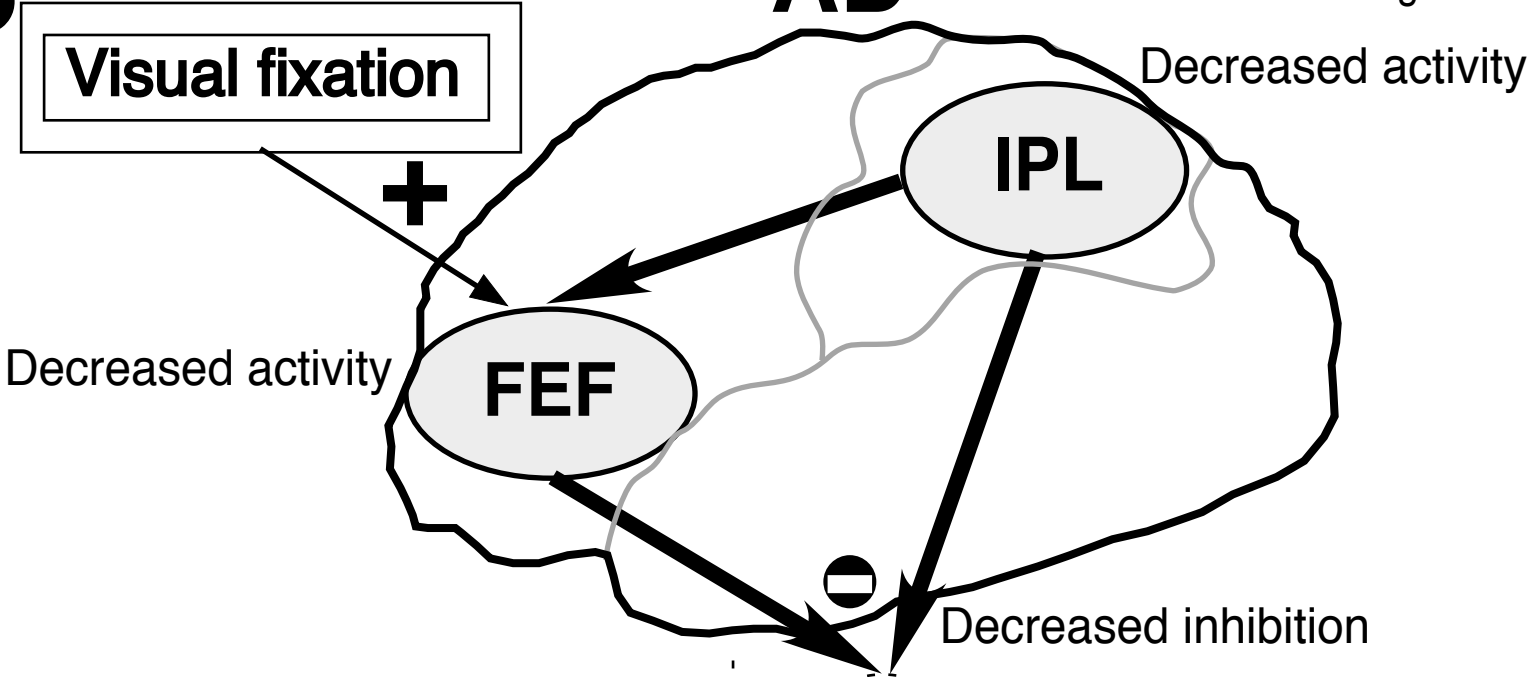
Neutral eye position

Time

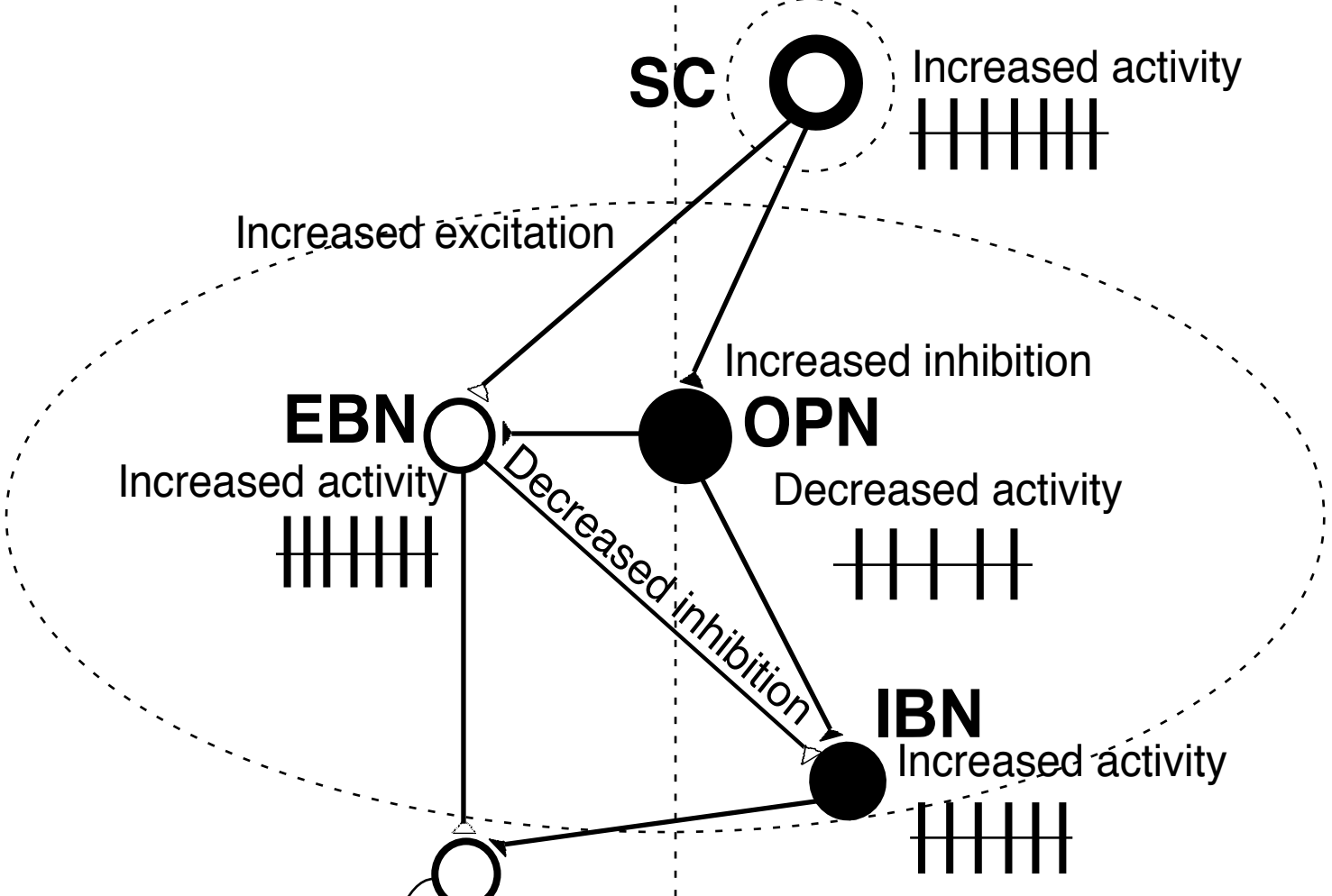


B

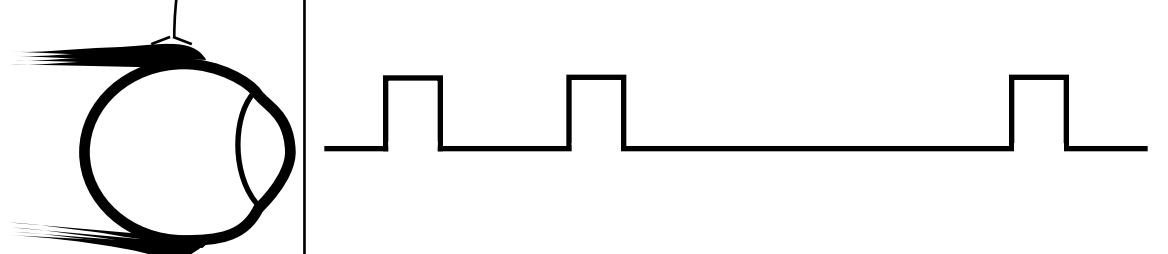
AD



SC



Square-wave jerks with visual fixation



C

