



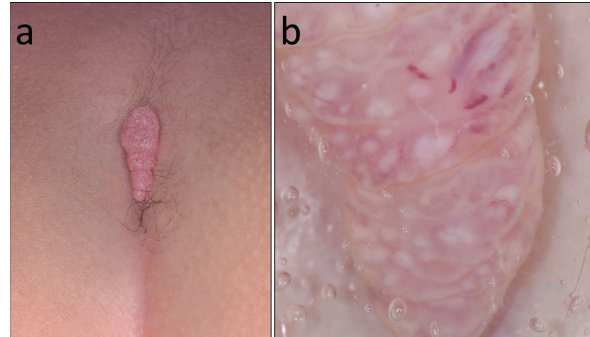
## Coccygeal Nodule in an Infant: A Quiz

Kazumasa OYA, Yosuke ISHITSUKA and Manabu FUJIMOTO

Department of Dermatology, Faculty of Medicine, University of Tsukuba, 1-1-1 Tennodai, Tsukuba, Ibaraki 305-8575, Japan. E-mail: yosuke.ishitsuka@md.tsukuba.ac.jp

An otherwise-healthy, 15-month-old girl was referred to our clinic with a nodule in the coccygeal region that had been noticed one month after birth and had gradually enlarged with no associated symptoms. The nodule was solitary, linear-shaped, red-coloured, with a papillomatous appearance, 15×4×5 mm in size (Fig. 1a). Detailed visual examination and dermoscopy revealed aggregated pearly-white, oval-shaped, amorphous structures occasionally surrounded by telangiectasia in an oedematous stroma (Fig. 1b). Laboratory tests revealed no signs of sexually transmitted diseases, including hepatitis B, syphilis or HIV. No similar lesions were found in her guardians.

*What is your diagnosis?* See next page for answer.



**Fig. 1.** (a) Solitary, linear-shaped, red-coloured protrusion with a papillomatous appearance 15×4×5 mm in size in the coccygeal region. (b) Dermoscopy revealed aggregation of pearly-white, oval-shaped amorphous structures occasionally surrounded by telangiectasia in an oedematous stroma.

## ANSWERS TO QUIZ

## Coccygeal Nodule in an Infant: A Commentary

Acta Derm Venereol 2018; 98: 824–825.

**Diagnosis: Molluscum contagiosum**

Although the initial clinical differential diagnosis included an epidermal naevus, a haemangioma or a condyloma acuminatum, establishing a conclusive diagnosis was difficult. The lesion was excised for treatment and diagnostic purposes. Histopathological examination revealed various sizes of endophytic epithelial hyperplastic lesions that were arranged in a linear fashion with prominent dermal oedema and vasodilation (Fig. 2a). The lobules were composed of central craters containing large cells with eosinophilic cytoplasmic inclusions (Fig. 2b), leading to the diagnosis of molluscum contagiosum.

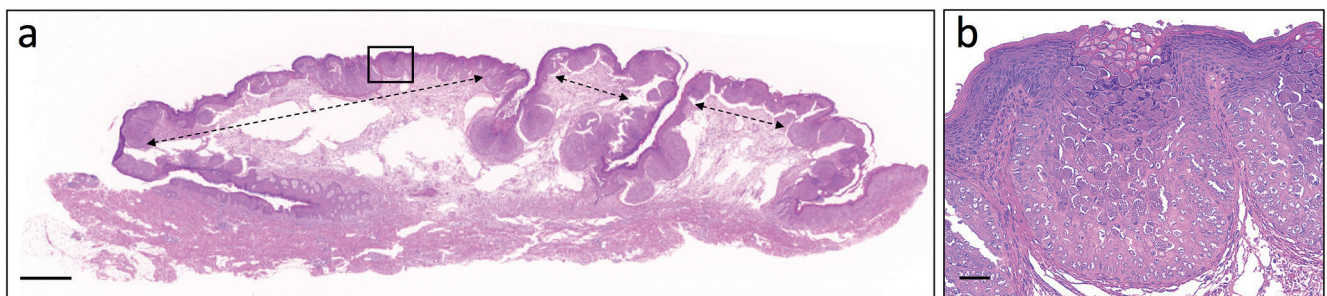
Molluscum contagiosum, a common benign skin infection that primarily affects children and young adults, is caused by molluscum contagiosum virus, a large, double-stranded virus that belongs to the Poxviridae and is exclusively pathogenic to humans. An epidemiological study revealed that the most commonly affected sites were the lower limbs, and the importance of skin-to-skin contact for the contracting the virus has also been suggested (1, 2). Infantile cases are relatively rare because of presumed transmitted immunity from maternal antibodies (2), but some cases have been sporadically reported as birth canal infection (3–5) and documented as congenital (3, 4). However, the nodule in the current patient was noticed one month after birth, thus it is possible that the virus was contracted thorough other modes of transmission, such as contaminated fomites or latent infection on the guardians' hands, which can be a cause of direct transmission during procedures, such as changing nappies, although palms and soles are as rarely affected as mucous membranes (6, 7).

Despite the well-recognized appearance of multiple, dome-shaped papules with central umbilication (2), the present case showed reddish, coccygeal solitary protrusion, and posed a diagnostic challenge. We assume that

the departure from the typical gross findings was caused by continual pressure or friction on to the area, which led to enhanced inflammatory response suggested by dermal oedema and vasodilation. Retrospectively, the surgery could have been avoided and less-invasive measures, including curettage or a wait-and-see approach, should have been taken instead. In fact, dermoscopy had given us important clues to the diagnosis; multiple pearly-white amorphous structures corresponded to the molluscum bodies that were located in the centre of endophytic epithelial lobules, and surrounding blood vessels have been described previously as a “crown of vessels” (8) or “red corona” (9). In conclusion, dermoscopy can be a powerful diagnostic modality in this potentially self-limiting (1) viral skin disease with unusual appearance and location.

## REFERENCES

- Olsen JR, Gallacher J, Finlay AY, Piguet V, Francis NA. Time to resolution and effect on quality of life of molluscum contagiosum in children in the UK: a prospective community cohort study. *Lancet Infect Dis* 2015; 15: 190–195.
- Braue A, Ross G, Varigos G, Kelly H. Epidemiology and impact of childhood molluscum contagiosum: a case series and critical review of the literature. *Pediatr Dermatol* 2005; 22: 287–294.
- Connell CO, Oranje A, Van Gysel D, Silverberg NB. Congenital molluscum contagiosum: report of four cases and review of the literature. *Pediatr Dermatol* 2008; 25: 553–556.
- Ujite H, Aoyagi S, Hirata Y, Osawa R, Shimizu H. Linear congenital molluscum contagiosum on the coccygeal region. *Pediatr Dermatol* 2013; 30: e83–84.
- Mandel MJ, Lewis RJ. Molluscum contagiosum of the newborn. *Br J Dermatol* 1971; 84: 370–372.
- Gottlieb SL, Myskowski PL. Molluscum contagiosum. *Int J Dermatol* 1994; 33: 453–461.
- Hanson D, Diven DG. Molluscum contagiosum. *Dermatol Online J* 2003; 9: 2.
- Zaballos P, Ara M, Puig S, Malveyh J. Dermoscopy of molluscum contagiosum: a useful tool for clinical diagnosis in adulthood. *J Eur Acad Dermatol Venereol* 2006; 20: 482–483.
- Micali G, Lacarrubba F. Possible applications of videodermatoscopy beyond pigmented lesions. *Int J Dermatol* 2003; 42: 430–433.



**Fig. 2.** Various sizes of endophytic epithelial hyperplasia arranged in a linear fashion (*double-headed dashed arrows*) with prominent papillary dermal oedema and vasodilation. (haematoxylin and eosin staining (H&E), bar=1 mm). (b) High-power magnification of the inset in (a). The epithelial lobules were composed of central craters containing large cells with eosinophilic cytoplasmic inclusions. (b) (H&E, bar=50 µm).