

Fig.1: VP shunt前(左)後(右)のCT

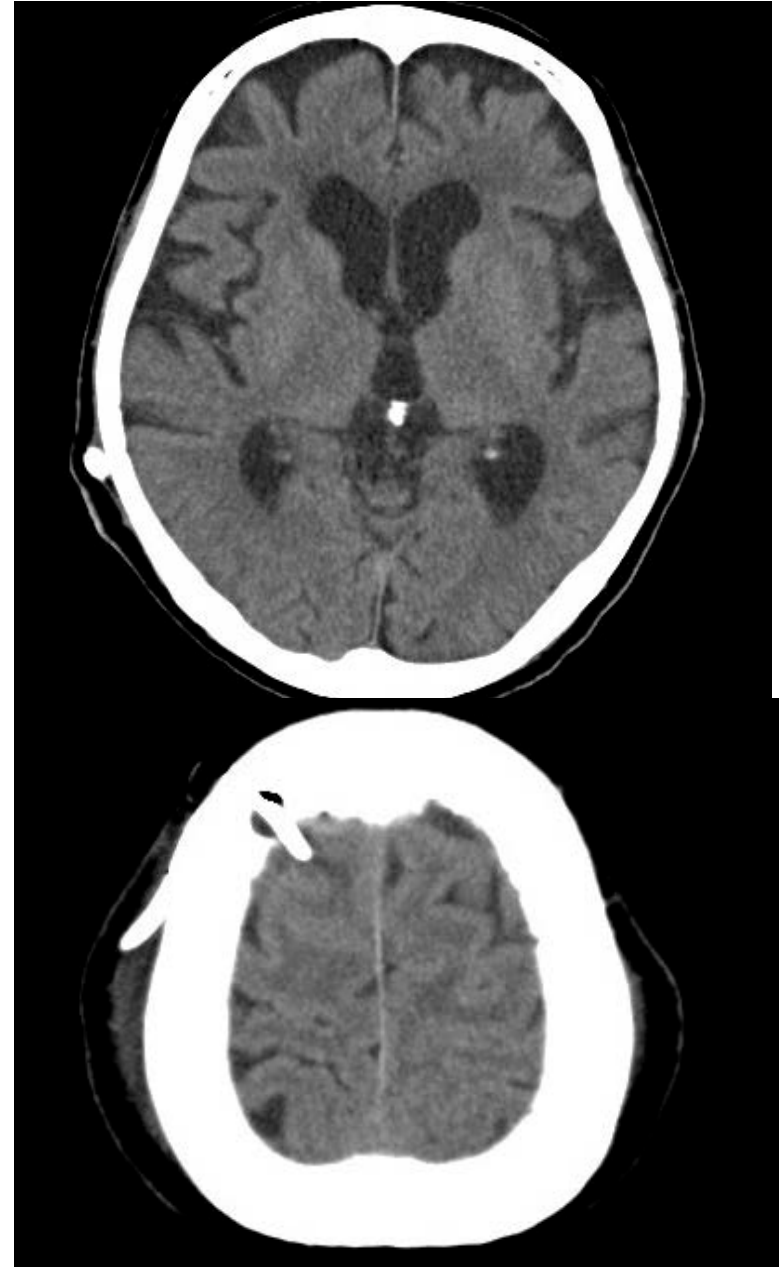
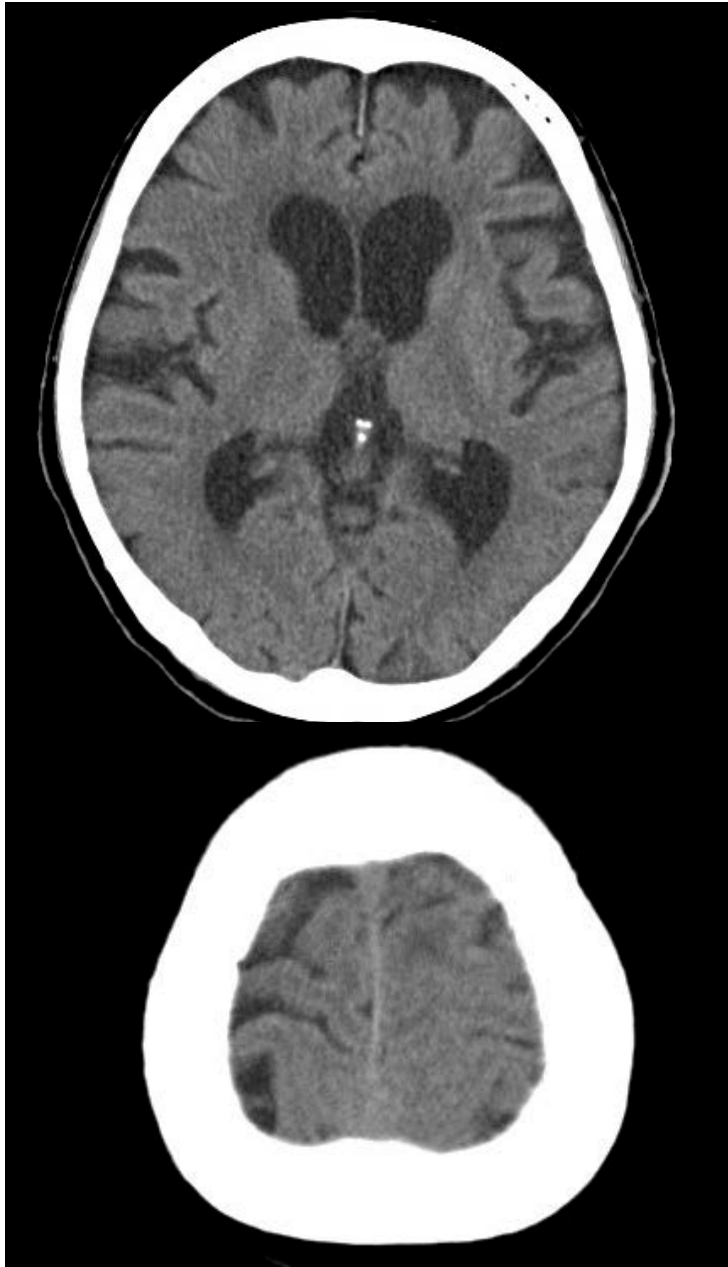
Fig.2: MRI(FLAIR, 左)とMRA(右)

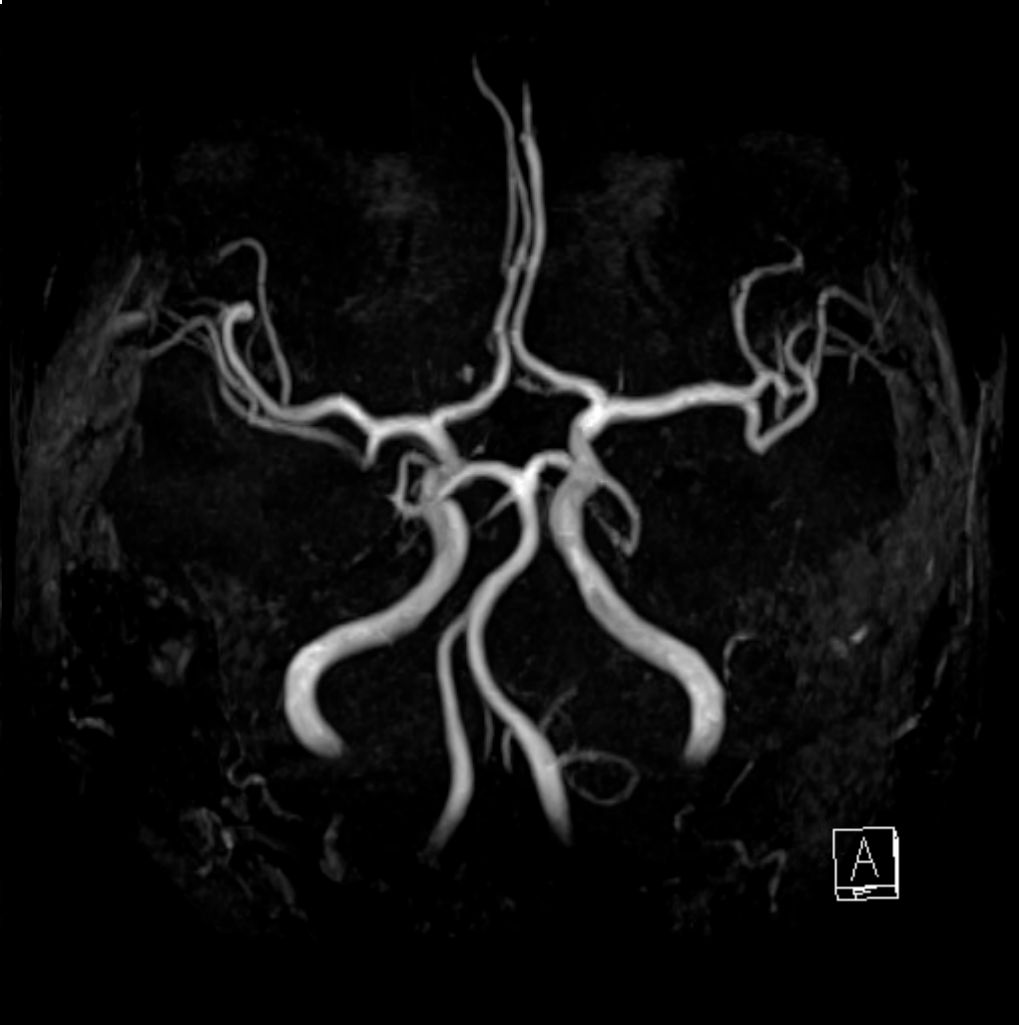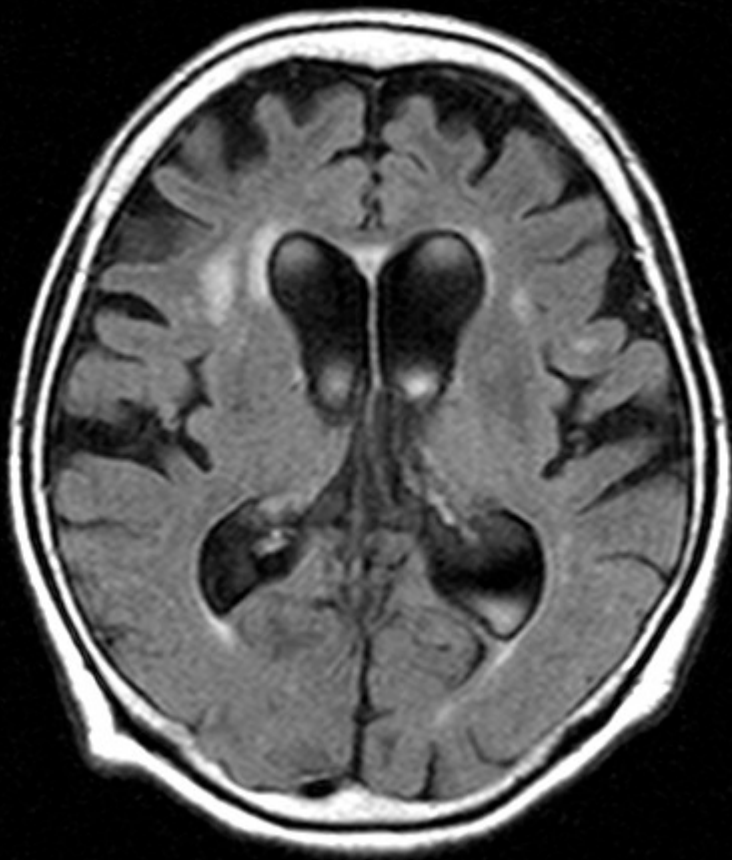


Fig.3: RI cisternography  
(6,24,48hours) 正面像(左)側面像(右)

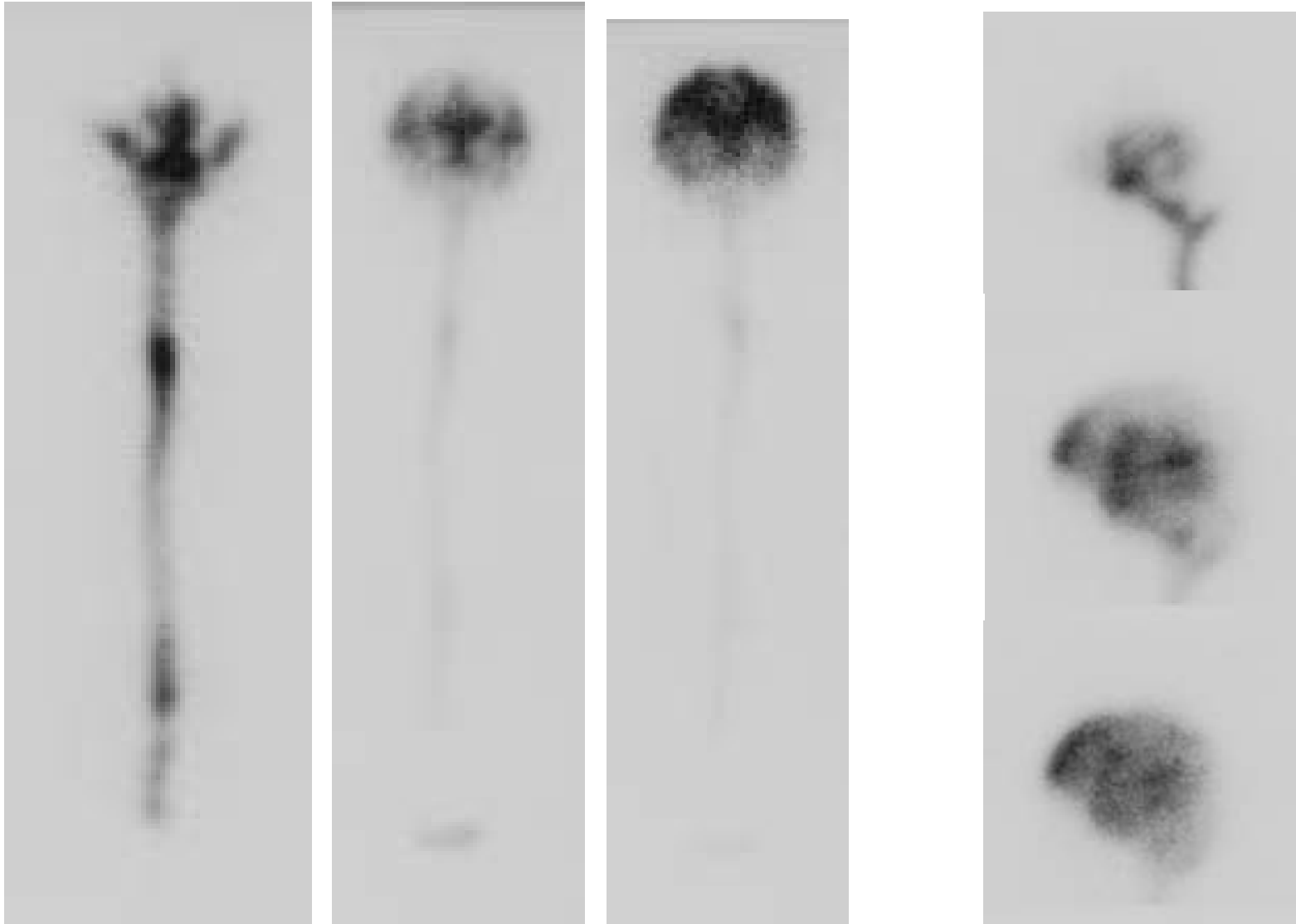


Fig.4: 術前CT

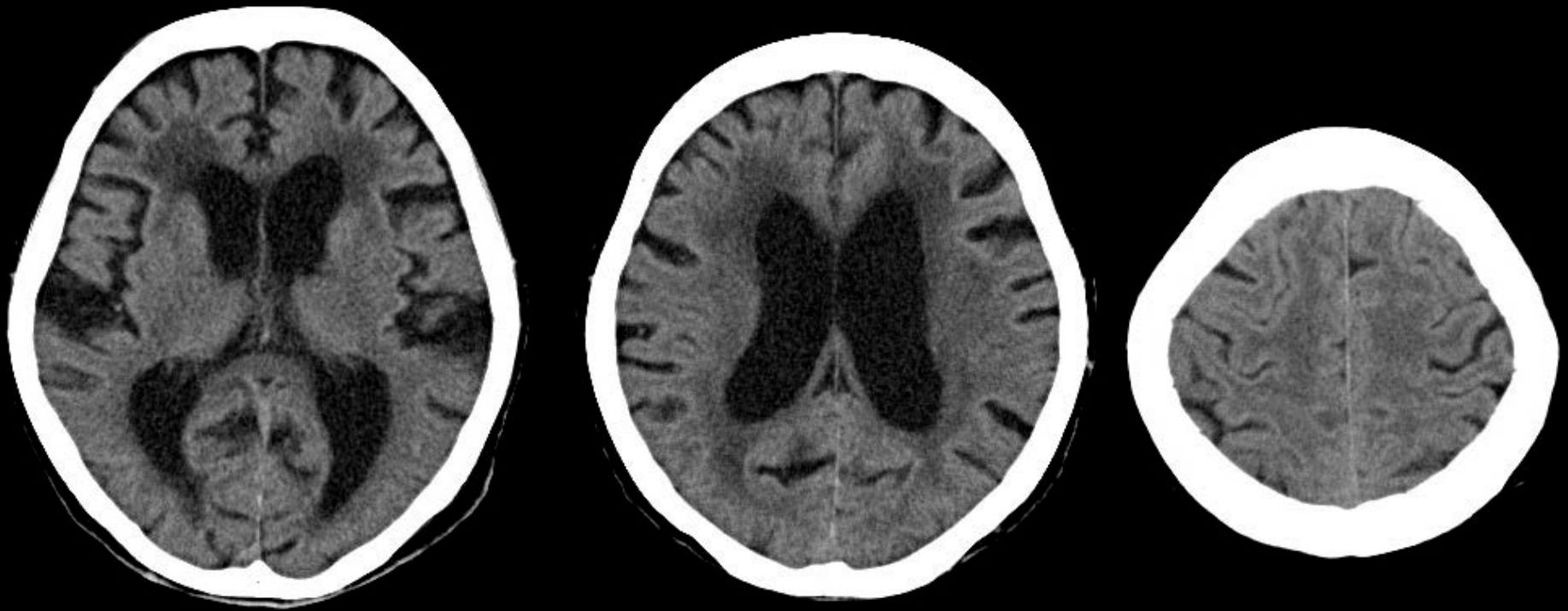


Fig.5:術前SPECT;血流増加(左)と減少(右)

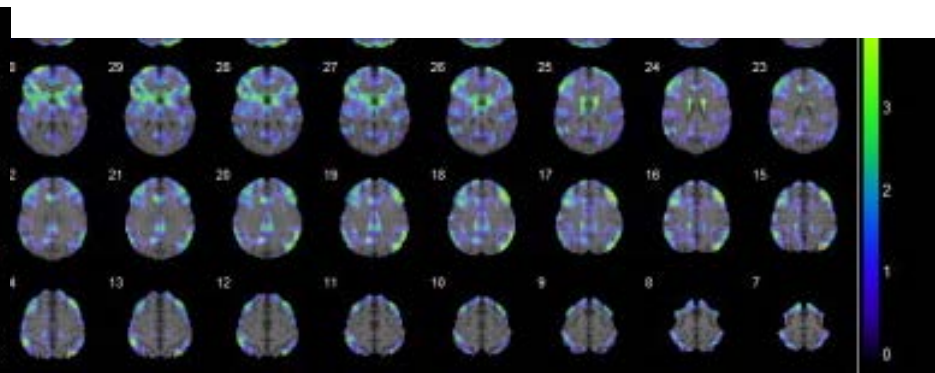
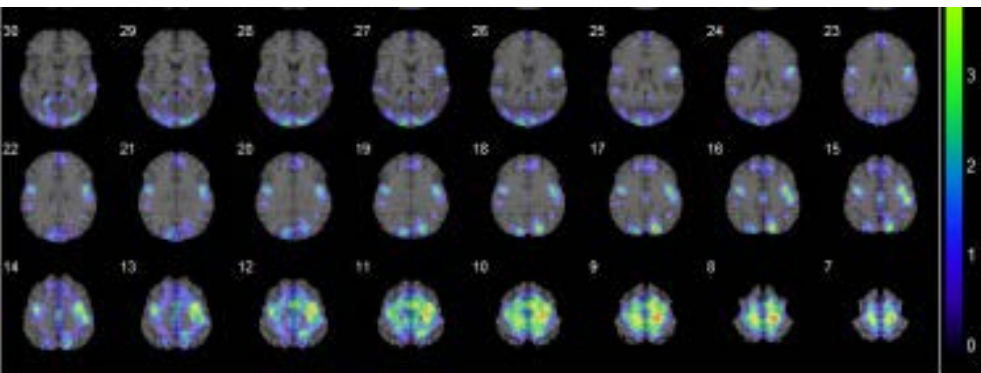
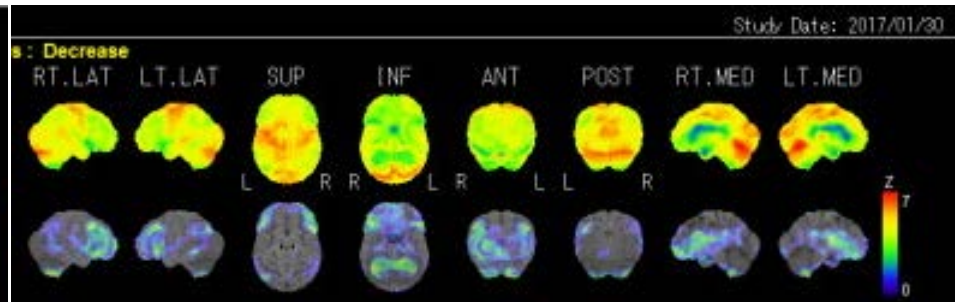
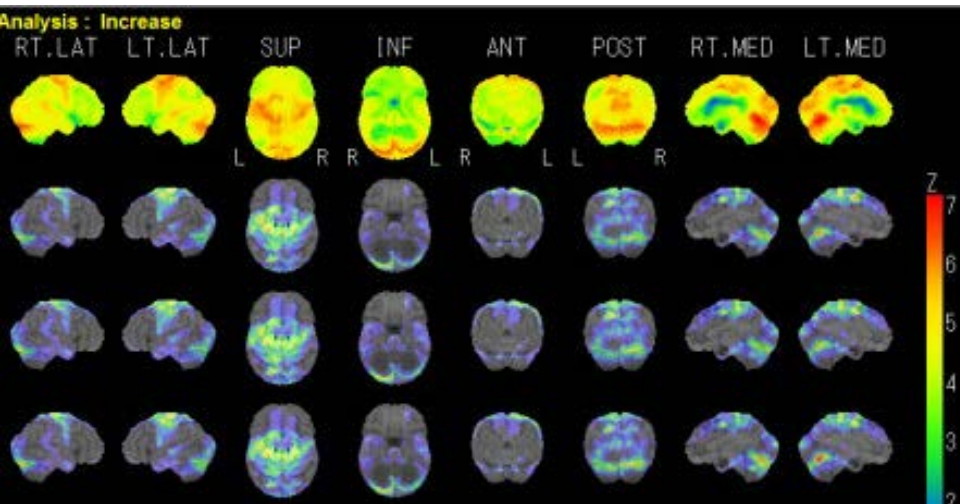


Fig.6: 術後CT

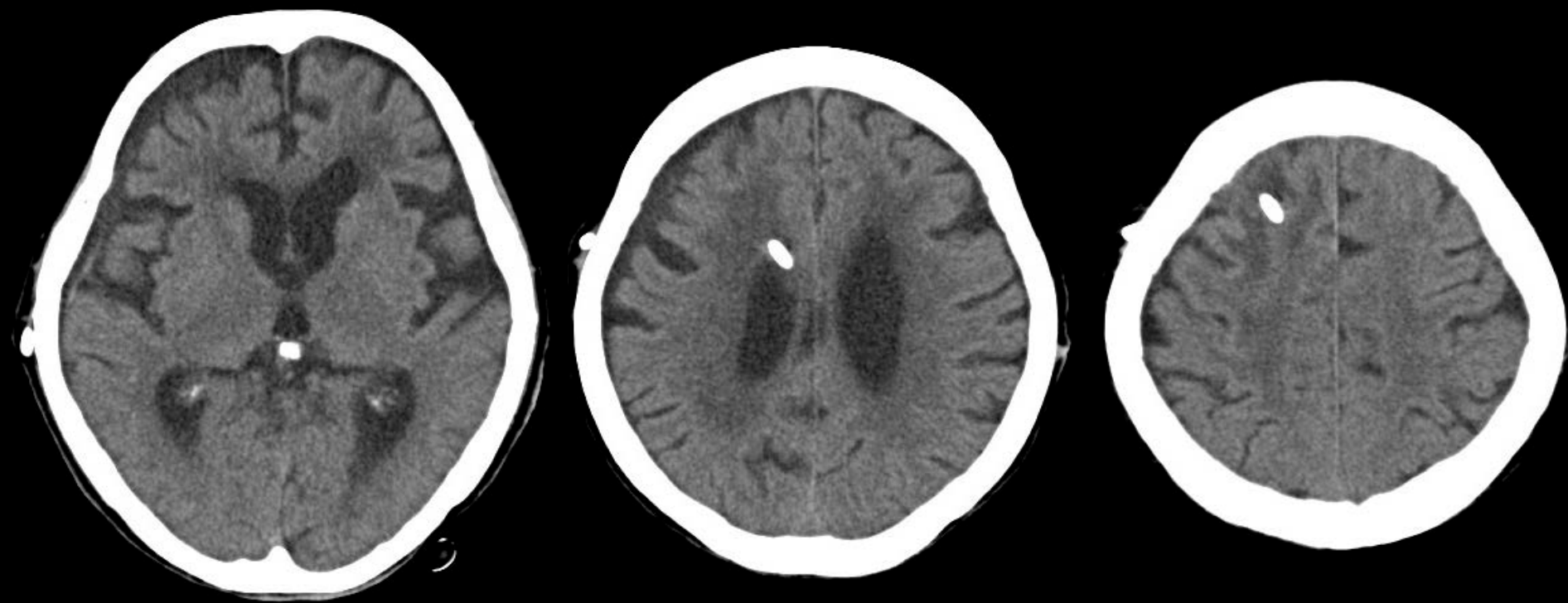




Fig.7: 術後SPECT;血流増加(左)と減少(右)

