

Case Report

Radiological diagnosis of gas gangrene in a fetus at term



Kanako Abe ^{a,*}, Hiromi Hamada ^a, Yutaka Fujiki ^b, Moe Iiba ^a, Yuri Tenjimbayashi ^a, Hiroyuki Yoshikawa ^a

^a Department of Obstetrics and Gynecology, Faculty of Medicine, University of Tsukuba, Tsukuba, Ibaraki, Japan

^b Department of Obstetrics and Gynecology, Mito Saiseikai General Hospital, Mito, Ibaraki, Japan

ARTICLE INFO

Article history:

Accepted 27 November 2014

Keywords:

anaerobe
computed tomography scan
fetus
gas gangrene
term pregnancy

ABSTRACT

Objective: To report a case of gas gangrene in a fetus at term, which was diagnosed by antenatal computed tomography (CT) imaging.

Case Report: A 23-year-old primiparous woman, who did not undergo any prenatal health checks until term, developed hypertension, proteinuria, and clouding of consciousness, and experienced intrauterine fetal death. A single, mature fetus with voluminous gas bubbles was observed on CT, which was consistent with a diagnosis of fetal gas gangrene. Following the induction of labor, a dead, malodorous infant was delivered, along with foul-smelling and frothy amniotic fluid. The patient's condition deteriorated, and intensive care support was required to treat the patient for septic shock and disseminated intravascular coagulation during the postpartum period. She died on the 2nd postpartum day.

Conclusion: Fetal gas gangrene is a very rare and potentially lethal event in pregnant women. To our knowledge, this is the first report on the antenatal diagnosis of fetal gas gangrene in a term pregnancy through CT. CT was useful for evaluating the extent of emphysematous change in the fetal and maternal organs.

Copyright © 2016, Taiwan Association of Obstetrics & Gynecology. Published by Elsevier Taiwan LLC. This is an open access article under the CC BY-NC-ND license (<http://creativecommons.org/licenses/by-nc-nd/4.0/>).

Introduction

The complication of gas gangrene during pregnancy is a very rare, unexpected, and potentially lethal event in the modern clinical setting. Two-thirds of these cases are reported after pregnancy terminations, whereas the remaining cases are reported in conjunction with term deliveries or puerperium [1,2]. Cases of fetal gas gangrene at term are rare because of the advances in the diagnosis, prophylaxis, and treatment of intra-amniotic infections [1–8]. Therefore, such cases are seldom encountered in Japan and in other developed countries. Following a PubMed search of the studies published in English between 1942 and 2014, we identified only 10 cases of fetal gas gangrene, which occurred during term pregnancies [1–8]; in particular, no cases have been reported within the past two decades. Thus, because of the rarity of this condition, a strategy for diagnosing and treating fetal gas gangrene has not yet been established in modern obstetrics. In this report, we

describe a case of gas gangrene in a fetus at term in a psychologically ill woman who did not seek antenatal care, and also demonstrate the usefulness of diagnosing fetal gas gangrene by computed tomography (CT) imaging.

Case Report

The patient was a 23-year-old primiparous Japanese woman with depression and panic disorder who had not undergone any prenatal health checks until term, which was when her psychiatrist referred her to an obstetrician. She was found to have hypertension (158/101 mmHg), proteinuria (semiquantitative proteinuria: 300 mg/dL), marked weight gain (45 kg), and a temporarily depressed level of consciousness; therefore, she was transferred to a perinatal medical center. Brownish discharge had appeared 1 week prior to presentation, and lower abdominal pain with foul discharge started 3 days before presentation.

On admission to the perinatal medical center, the membrane covering the fetal head and vaginal bleeding were not observed. Her cervix was dilated to 5 cm, and she experienced continuous abdominal pain and had a distended abdomen. An ultrasound examination only detected the fetal cranial bone and the placenta;

* Corresponding author. Department of Obstetrics and Gynecology, Faculty of Medicine, University of Tsukuba, 1-1-1 Tennodai, Tsukuba, Ibaraki, Japan.

E-mail address: abekana@md.tsukuba.ac.jp (K. Abe).

however, an anteroposterior radiograph showed a single, mature fetus in the cephalic presentation, with the presence of intrauterine gas (Figure 1A). Because of the poor quality of findings from the ultrasound examination and the presence of intrauterine gas on the anteroposterior radiograph, a CT scan was indicated to evaluate the condition of the maternal uterus and to determine whether the gas was present in the amniotic fluid cavity, placenta, and fetus. The CT scan revealed gas bubbles in the skull, chest, abdomen, and soft tissues of the fetus, which appeared in particularly large quantities in the amniotic cavity and the fetal bowel; however, gas was not present in the placenta or uterine muscle tissue (Figure 1B). These CT findings were consistent with a diagnosis of gas gangrene in a mature fetus.

At the time of diagnosis, an intravenous infusion of oxytocin was administered as labor had not yet begun. Ampicillin–sulbactam (3 g every 6 hours), clindamycin (1200 mg every 8 hours), and immunoglobulin were also administered intravenously. Thrombomodulin-alpha, antithrombin III, and fresh frozen plasma were administered to treat the patient's disseminated intravascular coagulation. Eight hours after admission, dilatation was complete; however, the progression of parturition was very slow. Seven hours after full dilatation, the patient became very ill, and demonstrated dyspnea and thrombocytopenia (platelet count: 4000 cells/mm³). Therefore, she was transferred by air ambulance to the University of Tsukuba Hospital.

Upon admission to the hospital, the woman was febrile, tachycardic, tachypneic, and hypertensive. In addition, swelling of the cranial skin of the fetus and crepitus were noted, and crowning of the fetus was observed. After platelet transfusion, the augmentation of labor by oxytocin was restarted. Within 1 hour, a dead, malodorous, macerated female infant (weight: 2940 g) was delivered along with foul-smelling and frothy amniotic fluid and gas. Subsequently, atonic bleeding developed. Hence, bimanual compression of the uterus was required, and uterotonic agents were administered. The stillborn infant showed prominent abdominal distension, reddish-brown discoloration of the abdominal skin, and a green facial hue. An anteroposterior radiograph of the infant was obtained immediately after delivery, which revealed a large volume of gas in the thoracic cavity, abdominal cavity, and bowel as well as subcutaneous gas bubbles throughout the

extremities and trunk (Figure 1C). An autopsy of the infant revealed the presence of emphysematous change that extended into the fetal liver and kidneys.

A bacterial culture of the maternal blood was performed at the perinatal medical center, which indicated positive results for *Prevotella bivia*. Furthermore, anaerobic bacteria, including *Bacteroides capillosus* and *Anaerococcus prevotii*, were identified from a bacterial culture of the infant's oral cavity.

The patient required intensive care support, including mechanical ventilation, volume resuscitation, and vasopressor support. In addition, antibiotics and blood transfusions were required to control septic shock and to treat the disseminated intravascular coagulation that developed during the postpartum period. Moreover, eclampsia developed on the day after delivery. However, the patient's condition subsequently deteriorated, and she died on the 2nd postpartum day.

Discussion

In this case, we observed that the anaerobic bacterial infection that occurred in the patient caused fetal gas gangrene and maternal septic shock. The premature rupture of membranes; fetal death; and prolonged, obstructed labor appear to have predisposed the mother to the development of gas gangrene [1,2]. We believe that the premature rupture of the membranes induced the intra-amniotic infection, which consequently resulted in fetal gas gangrene and intrauterine fetal death. The infection also led to maternal septic shock and puerperal death. Although the direct cause of the maternal death may have been septic shock, the pathology of the complicating preeclampsia/eclampsia may have affected her general condition, thus making her intensive care more challenging, particularly in terms of stabilizing her hemodynamics.

To our knowledge, this is the first report of a patient with fetal gas gangrene who underwent a prenatal CT scan; previous cases of this condition have been reported, but CT scanning was not widely used at that time. In the present case, the CT scans demonstrated the extent of emphysematous changes caused by the gas-forming bacteria. The CT scans also indicated that emphysema was disseminated throughout the fetal body. However, the placenta and

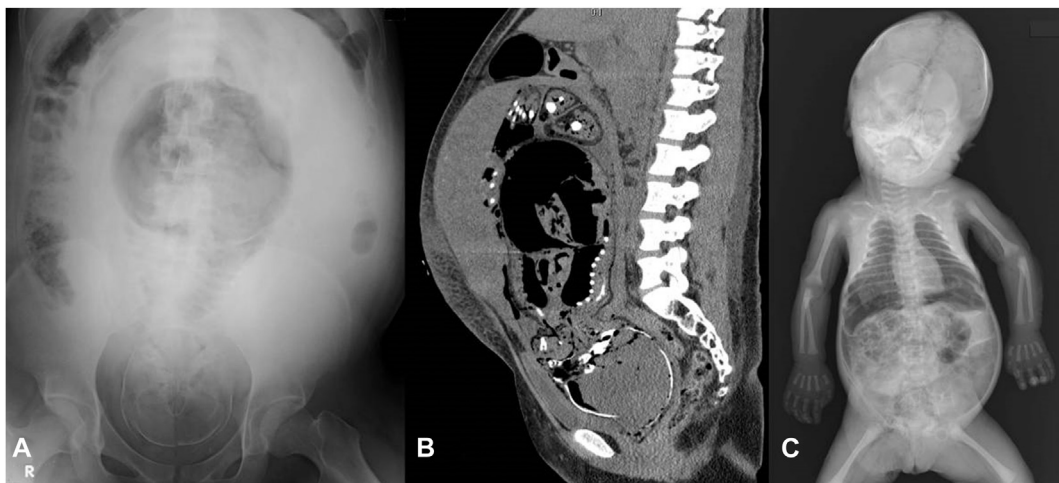


Figure 1. (A) An anteroposterior radiograph showing a mature single fetus with cephalic presentation. A uterine wall shadow and a volume of gas in the uterine cavity are observed. The Spalding's sign is positive. (B) A sagittal view of the noncontrast computed tomography scan of the patient's pelvis and abdomen. There are abundant gas bubbles in the subdural space of the fetus' skull as well as in the thorax, extremely dilated gastrointestinal tract, mesenteric and portal veins, and soft tissues. The amniotic cavity is occupied by large amounts of gas and a small amount of fluid. The placenta is attached to the anterior wall of the uterus, and the uterine muscle tissues do not show emphysematous changes. Although the maternal gastrointestinal tract is paralytic, there is no finding indicating active infiltration of the maternal peritoneal cavity such as intraperitoneal free air. (C) An anteroposterior radiograph of the stillborn infant immediately postdelivery. A volume of gas is observed in the thoracic cavity, abdominal cavity, and bowel, and there is subcutaneous gas throughout the extremities and the trunk.

maternal uterine muscle were intact prior to the induction of labor. These CT findings were consistent with the fetal and maternal autopsy findings. Previous reports have described cases of emphysematous uteruses, in which the induction of labor failed and/or uterine rupture occurred, leading to subsequent laparotomy and hysterectomy of the collapsed uterus [6–8]. Treatment for these types of cases includes early diagnosis and early elimination of the nidus of infection to prevent the infection from spreading to the maternal uterus. If the uterus was involved, a laparotomy and hysterectomy would be recommended alternatives to the induction of labor. Thus, CT is a reliable and valuable diagnostic tool that is easily available for even severe cases. In cases such as the present case, the use of CT ensures the prompt, early, and appropriate treatment of the mother.

Infections of the uterus occur in four stages [8]. In the first stage, the infection is confined to the dead fetal tissue, and gas begins to form. Thereafter, the infection spreads to the endometrium, without causing systemic symptoms. In the third stage, the myometrium is damaged, and the infection spreads to the adjacent muscle tissue, with the formation of gas; in this stage, the infection may also spread to the peritoneal cavity. Finally, in the fourth stage, the infection is established in the maternal tissue, with the release of exotoxins that may cause rapid hemolysis. At this stage, the kidneys, liver, and other viscera may also be involved. In the present case, when the patient was admitted to the perinatal medical center, the infection was confined to the dead fetal tissue and may have involved only the endometrium and not the myometrium. After the induction of labor, disseminated intravascular coagulation and septic shock developed, probably due to the increased intrauterine pressure, which was caused by the labor and facilitated the entry of exotoxins into the maternal circulation. Moreover, the increased intrauterine pressure may have caused the transtubal spread of the infection to the peritoneal cavity; the autopsy of the mother revealed severe panperitonitis.

When the patient was admitted to our facility, we chose to induce vaginal delivery in an attempt to eliminate the source of infection (i.e., the dead baby). We avoided a cesarean delivery, because the baby was dead and the general condition of the mother was good initially. However, we cannot conclude which delivery method would have been best for increasing the likelihood of preserving the mother's life in the present case, wherein the fetus

had gas gangrene and the maternal uterine muscle was intact. A cesarean hysterectomy or single cesarean section may have been alternatives to the induction of labor, which may have prevented the subsequent maternal panperitonitis.

In conclusion, this report describes a very rare case of gas gangrene in a fetus at term, which was diagnosed by CT. Diagnosis by CT is a reliable and valuable method to evaluate the extent of emphysematous changes by the gas-forming bacteria that can easily be performed even in severe cases. Based on the CT findings, we preferred the induction of labor to cesarean delivery in the present case; however, we cannot conclude that this is the best delivery method. Therefore, further reports are needed to establish the best treatment for fetal gas gangrene, considering the advances in the field of obstetrics.

Conflicts of interest

The authors have no conflicts of interest relevant to this article.

Acknowledgments

We would like to thank Dr Yumiko Oishi Tanaka, a radiologist in the Department of Radiology, and Drs Naoe Itoguchi and Masato Sugano, pathologists in the Department of Pathology, for their help with this case report.

References

- [1] Ragan WD. Gas gangrene complicating term pregnancy. *Obstet Gynecol* 1960;15:332–9.
- [2] Jones DH. Gas gangrene complicating pregnancy. *J Obstet Gynaecol Br Commonw* 1965;72:785–90.
- [3] Kemp FH, Stallworthy JA. A case of intra-uterine infection of the foetus by gas-gangrene organisms. *Br Med J* 1942;2:94–5.
- [4] Thornhill PE. Gas bacillus infection primary in the unborn fetus, with report of a case spontaneously occurring at term, the mother surviving. *Am J Obstet Gynecol* 1946;52:858–60.
- [5] Arendt J. Fetal gas-bacillus infection. *Med Radiogr* 1951;27:87–8.
- [6] De Lima GR, Delascio D. Gas gangrene of pregnant uterus. *Obstet Gynecol* 1966;27:280–3.
- [7] Kolawole ME, Akande EO. Pyogaseous infection in pregnancy. *Br Med J* 1971;3:620–1.
- [8] Habeebullah S, Bupathy A, Rajaram P. Two cases of gas gangrene complicating uterine rupture and fetal death at term. *Asia Oceania J Obstet Gynaecol* 1994;20:191–4.