

Ten-year results of 55 dysplasia hips of hip offset and leg length reconstruction in total hip arthroplasty with cementless tapered stems having a high offset option designed for dysplastic femur

Tomofumi Nishino¹ , Hajime Mishima¹, Haruo Kawamura²,
Tomohiro Yoshizawa¹, Shumpei Miyakawa¹ and
Masashi Yamazaki¹

Abstract

Purpose: In developmental dysplasia of the hip (DDH), the centers of hip rotation move in the superior and lateral direction. In total hip arthroplasty for such cases, movement of the center of hip rotation is in the inferior and medial direction. It causes an increase in leg length and a decrease in acetabular offset. We therefore evaluated the change of hip offset and leg length before and after surgery with two stems having a high offset option. **Patients and Methods:** The preoperative diagnosis was secondary osteoarthritis due to DDH excluded Crowe IV. A stem selection was decided based on preoperative two-dimensional templating. Total 55 hips in 50 patients were followed up for minimum 10 years. Pre- and postoperative clinical evaluations were performed using a hip joint function scoring system. Radiographic evaluations were used for offset and leg length measurements and other associated factors. **Results:** Both stems showed excellent clinical results. A high offset option was used in 60% of all cases. No postoperative dislocations were observed. The biological fixation was stable in all cases. The hip offset was restored without excessive leg lengthening in most cases. **Conclusion:** Anatomical consistency could be maintained by using a stem which matched geometry of the proximal part and had offset option. These cementless tapered stems having a high offset option are suitable for Crowe I to III hip dysplasia if two-dimensional X-ray templates fit the shape of the proximal femurs. They were associated with excellent clinical results and biological fixation. The offset option may be useful to adjust leg length and offset in DDH patients.

Keywords

dysplastic femur, hip offset, leg length, offset option

Date received: 12 February 2019; Received revised 4 February 2020; accepted: 8 February 2020

Introduction

Total hip arthroplasty (THA) in patients with developmental dysplasia of the hip (DDH) is technically demanding. The anatomical abnormalities that are present depend on the severity of the dysplasia.¹ Moreover, patients with DDH are smaller than the usual population.² Anatomical abnormalities of the acetabulum include acetabular dysplasia (shallow acetabulum) and formation of a false acetabulum in the dislocated position. In cases with a false acetabulum, the true

¹ Department of Orthopaedic Surgery, Faculty of Medicine, University of Tsukuba, Tsukuba, Japan

² Department of Orthopaedic Surgery, University of Tsukuba Hospital, Tsukuba, Japan

Corresponding author:

Tomofumi Nishino, Department of Orthopaedic Surgery, Faculty of Medicine, University of Tsukuba, 1-1-1 Tennodai, Tsukuba, Ibaraki 305-8575, Japan.

Email: nishino@md.tsukuba.ac.jp



Creative Commons Non Commercial CC BY-NC: This article is distributed under the terms of the Creative Commons Attribution-NonCommercial 4.0 License (<https://creativecommons.org/licenses/by-nc/4.0/>) which permits non-commercial use, reproduction and distribution of the work without further permission provided the original work is attributed as specified on the SAGE and Open Access pages (<https://us.sagepub.com/en-us/nam/open-access-at-sage>).

acetabulum is extremely small. Biomechanically, the forces through the hip joint are lowest when the cup is placed in the original acetabulum.³ In most DDH cases, the center of hip rotation moves in the superior and lateral direction. Movement of the center of hip rotation in the inferior and medial direction causes an increase in leg length and a decrease in acetabular offset. The limb is lengthened by lowering the acetabulum back to or closer to its anatomical position or by inserting a femoral component that is longer than the length of femoral bone that is removed.⁴ However, simultaneous limb lengthening of both the acetabular and femoral sides might not be possible because of soft tissue tension. The restoration of the hip center of rotation also accompanies a reduction of horizontal acetabular offset in most DDH cases. Without compensation of horizontal offset by the femoral side, the reduction of horizontal acetabular offset can cause impingement of the proximal femur or femoral (stem) neck against the pelvis and potentially lead to dislocation. We therefore evaluated the change of hip offset and leg length before and after surgery with two stems having a high offset option.

Materials and methods

To fit the shorter average stature of Asians compared with Caucasians, a stem from a company was modified. The Asian version of the modified stem, named as stem A, in which the stem length is 15 mm shorter than the original stem in all sizes. However, the shape of these standard stems does not always match the morphological characteristics of some DDH cases. To accommodate the morphology of the femurs of Asian DDH patients, stem B with reduced flare as compared to the stem A was developed. Both stems are made of a titanium alloy (Ti-6Al-4V) and have a 3-degree tapered shape in the coronal and sagittal planes. The proximal part of the stems was subjected to porous coating (pore size, 200 μm) with titanium beads. The middle to the distal portions of the stems were processed by grit blasting ($R_a = 4.32 \mu\text{m}$). At that location, ribs were processed to create linear anterior and posterior surface shapes to ensure rotational stability. The tip was polished and bullet-shaped. The neck-shaft angle (131 degrees) and neck length (i.e. the amount of horizontal and vertical offset) were equal to those of the original stem. Two offsets, standard or high, may be selected without changing the leg length. The stem B has a reduced flare to accommodate the metaphyseal morphology of DDH patients. The proximal shape was designed based on computed tomography (CT) data from patients with DDH.⁵ Due to the altered geometry, the mechanical strength of stem B is lower than that of stem A. The extent of proximal porous coating is shortened to produce the required mechanical strength. The size of stem B ranged from #7 to #12, whereas stem A ranged from #8 to #16. Theoretically, narrow medial-lateral width due to reduced flare is disadvantageous for rotational stability. Moreover, a decreased area

of porous coating is also disadvantageous for initial press-fit fixation and subsequent biological fixation, but it may be advantageous in reducing femoral stress shielding.

A 26-mm-diameter cobalt-chromium femoral head or zirconia femoral head was used during the study period. For the acetabular side, two kinds of hemispherical cups and a highly cross-linked polyethylene liner were used for all cases.

A total of 55 primary THAs were performed in patients with secondary osteoarthritis due to DDH during a 2-year period starting in January 2006. The stem B was inserted in 21 hips in 17 patients. The stem A was inserted in 34 hips in 33 patients. All cases were followed for at least 10 years. Cases of Crowe group IV dislocation,⁶ proximal femoral shortening osteotomy, and previous valgus femoral osteotomy were excluded from the study. Use of the stem A or stem B was decided based on preoperative templating using plain anteroposterior radiographs, and we made a statement that both sets of implants were available just in case. The offset option was also considered based on preoperative templating and intraoperative soft tissue balance tests.⁷ Morphological evaluation of the hip was conducted using preoperative images from plain anteroposterior radiographs of the pelvis and both hips. According to the Dorr classification,⁸ the femurs were classified as type A (champagne flute shape), B (funnel shape), or C (cylindrical shape). The cortical index⁹ was defined as the proportion of the width of the femur occupied by cortical bone at 10 cm below the lesser trochanter. The canal flare index was defined as the ratio of the diameter of the femoral canal at the isthmus in the anteroposterior view to the diameter of the medullary canal 2 cm above the lesser trochanter.¹⁰ The femoral neck-shaft angle (the angle formed by the line connecting the femoral axis and femoral head center) was also measured. The degree of subluxation was classified using the Crowe classification.⁶

Detailed patient demographics are shown in Table 1. Significant differences between cases using each stem were found in patient age, bilateral involvement, body mass index, and Crowe classification.

In all cases, surgery was performed by the senior author using a posterolateral approach. The femurs were prepared with a hand-driven reamer and a broach. All stems were inserted using press-fit technique. Partial weight bearing was started after surgery, and the load was increased stepwise to reach full weight-bearing within 2–4 weeks.

Informed consent was obtained from all patients, who approved the use and publication of their data. This retrospective study was approved by our institution's ethics review board.

Pre- and postoperative clinical evaluations were performed using the Japanese Orthopaedic Association standard scoring system for the evaluation of hip joint function (JOA Hip Score).¹¹ The score was based on a total of 100 points, composed of 40 points for pain, 20 points for range of motion, 20 points for the ability to walk, and 20 points for activities of daily living. Clinically, the postoperative course was followed at 3 and 6 months after surgery, and

Table 1. Patient demographics.

	All	Stem A	Stem B	p-Value
Number of follow-up cases	55 hips in 50 patients	34 hips in 33 patients	21 hips in 17 patients	
Mean follow-up period (range) (months)	131 (120–142)	130 (120–142)	132 (120–142)	
Number of men:women	9:46	7:27	2:19	0.28 ^a
Mean age (range) (years)	57 (42–82)	58 (42–82)	52 (43–59)	<0.01 ^b
Affected side: right:left	24:31	16:18	8:13	0.71 ^a
Bilateral affected: yes:no	30:25	15:19	15:6	<0.05 ^a
Mean height (range) (cm)	153 (137–170)	154 (137–170)	151 (145–156)	0.09 ^b
Mean body weight (range) (kg)	55 (39–86)	58 (44–86)	50 (39–68)	<0.01 ^b
Mean BMI (range) (kg/m ²)	23.5 (16.4–34.2)	24.5 (18.1–34.2)	21.9 (16.4–30.4)	<0.05 ^b
Preoperative mean JOA Hip Score (range)	48 (27–83)	47 (30–79)	49 (27–83)	0.48 ^b
Dorr type; A:B:C	8:42:5	6:23:5	2:19:0	0.1 ^b
Cortical index (range)	0.53 (0.40–0.66)	0.52 (0.40–0.64)	0.55 (0.46–0.66)	0.086 ^a
Thickness of medial and lateral cortices below 10 cm of LT	12.0 (8.3–17.1)	12.6 (8.3–17.1)	10.9 (8.7–14.7)	<0.01 ^a
Diameter of femoral shaft at the same level	25.3 (21.0–31.2)	26.0 (21.7–31.2)	24.1 (21.0–27.1)	<0.05 ^a
Canal flare index (range)	3.95 (2.53–7.27)	3.89 (2.53–7.27)	4.06 (2.99–4.86)	0.059 ^a
Diameter of medullary canal above 2 cm of LT	42.0 (34.6–53.1)	43.3 (35.0–53.1)	40.0 (34.6–49.1)	<0.01 ^a
Diameter of medullary canal at isthmus of femur	10.9 (7.3–15.1)	11.6 (7.3–15.1)	9.9 (8.7–13.5)	<0.01 ^a
Neck-shaft angle (range) (degree)	142 (120–178)	141 (120–178)	144 (128–157)	0.11 ^a
Crowe's classification; Group I:II:III	27:21:7	23:9:2	4:12:5	<0.01 ^a

JOA: Japanese Orthopaedic Association; LT: lesser trochanter; BMI: body mass index.

^aStatistical difference by χ^2 test.

^bStatistical difference by Mann–Whitney *U* test.

then once every 6 months. The scores at the time of the latest follow-up were compared with those before surgery. Major postoperative complications such as dislocation, deep infection, and periprosthetic fracture were investigated. The stem size and usage of the standard or high offset neck option were studied in both groups.

Anteroposterior radiographs, as well as axial and oblique images, of the hip joints were taken immediately after surgery and at each clinical visit. Radiographic evaluations were conducted retrospectively by two of the authors. When the interobserver evaluations were substantially different, reevaluation and matching of the results were necessary. The status of biological fixation of the femoral stem was assessed using the criteria of Engh et al.¹² Stem subsidence was measured and a migration ≥ 2 mm was defined as subsidence. Alignment of the stem was evaluated using anteroposterior radiographs of the bilateral hip joints taken immediately after surgery. Varus and valgus stem insertion was defined as the presence of an inclination $\geq 3^\circ$ compared to the femoral axis or the presence of contact between the stem tip and the medial or lateral inner cortex. All cases other than those meeting the above criteria were considered to be neutral stem insertion. Bone reactions such as the presence or absence of spot welds and cortical hypertrophy in each zone around the stem were evaluated according to the Gruen classification of zones.¹³ The degree of stress shielding and mode of biologic fixation were defined according to Engh's criteria.^{12,14}

The methods for radiographic offset and leg length measurements have been previously described by Dastane

et al.¹⁵ Briefly, the femoral offset was measured as the distance between the center of rotation of the femoral head and the proximal femoral shaft axis. The acetabular offset was measured as the distance between the center of rotation and a vertical line through the ipsilateral teardrop. Hip offset was calculated as the sum of femoral offset and acetabular offset. Radiographic leg length difference was measured as the difference between the hips in the distance between the trans-teardrop line and the most prominent aspect of the lesser trochanter. Preoperative femoral neck anteversion and postoperative prosthetic neck anteversion (stem anteversion) were measured using CT. Anteversion was the angle created by a cross section that includes the femoral neck axis and a line drawn between the medial and the lateral epicondyles of the distal femur, as described by Murphy et al.¹⁶

Clinical, radiographic, and surgical factors were evaluated using the χ^2 test, Mann–Whitney *U* test, Wilcoxon signed-rank test, or *t*-test, as appropriate. All statistical analyses were performed using Statcel 3 software (OMS, Saitama, Japan). The significance level was set at $\alpha = 0.05$.

Ethical approval

This retrospective study was approved by our institution's ethics review board (H26-104).

Results

The JOA Hip Score improved significantly from 48 (range, 27–83) points preoperatively to 94 (range, 77–100) points at the time of the final follow-up ($p < 0.01$). Major

Table 2. Amount of change in offset and leg length.

Parameter	Amount of change (mm, mean \pm SD)
Acetabular offset	-14.5 ± 8.5
Femoral offset	11.5 ± 9.3
Hip offset	-3.0 ± 8.7
Leg length	15.8 ± 7.8

postoperative complications such as dislocation and deep infection were not seen. However, two periprosthetic fractures were observed, one at 7 and one at 11 years after surgery. Both were classified as Vancouver type B1¹⁷; one was treated conservatively and the other was treated surgically with cerclage wiring. The median stem size in the stem B and stem A was 10 and 11, respectively. The high offset options were used in 33 of 55 hips, 13 case in the stem B and 20 hips in the stem A. All stems had stable fixation with bone ingrowth. Stem subsidence was detected in three hips. The amount of subsidence was 2 mm in two cases and 1 mm in one case, and occurred by 6 months after surgery and did not progress further than that. Stem alignment was neutral in 43 hips, valgus in 5 hips, and varus in 7 hips. Spot welds were observed in 0, 20, 33, 0, 29, 29, 0 hips in the Gruen zones 1 to 7, respectively. Most spot welds were observed at the middle to distal portion of the stems. Cortical hypertrophy was observed in 3 hips in the Gruen zones 3 and in 9 hips in the Gruen zone 5. The severity of stress shielding was classified as none in 0 hips, first degree in 11 hips, second degree in 24 hips, third degree in 14 hips, and fourth degree in 6 hips. Results of radiographic offset and leg length measurements are shown in Table 2 and Figure 1. The leg lengths increased, although there were few changes in hip offset. In fact, the reduction in acetabular offset obtained by placing the cups in the original position was balanced by the increase in femoral offset using a high offset option. Furthermore, no significant difference was seen between the standard and high offset in the groups. To compare difference to the opposite side in each radiological parameter between before and after surgery, the hip offset and the leg length approached near zero (Table 3). The average neck anteversion: 18.6 (range -11.9 to 52.6) degree change in the average stem anteversion: 25.2 (range -0.4 to 38.5) degree. As a result, the average proximal femoral anteversion increased 6.6 degree before and after the surgery. However, variation was seen in the increase and decrease by a case.

Discussion

We found that with a follow-up period ≥ 10 years, all stems achieved good outcomes both clinically and radiographically. Although there was a concern that the stem B might be less stable than the standard stem because of its narrower proximal geometry, the initial stability and subsequent biological fixation of the stem B was equal to that of the stem

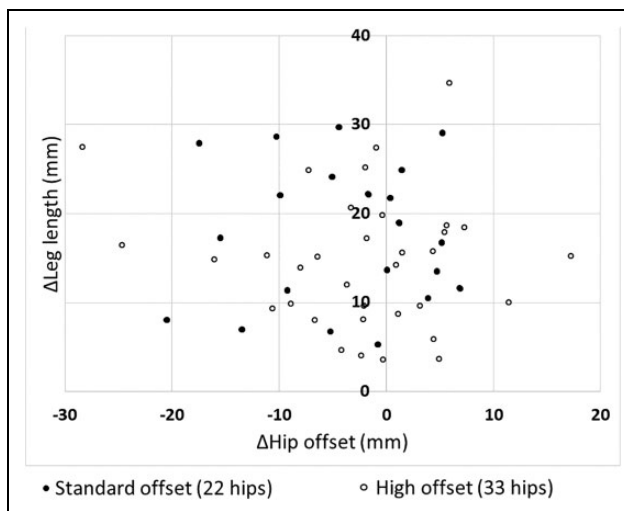


Figure 1. Distribution of the change in leg length and hip offset. Amount of change in leg length and hip offset between before and after surgery in each patient in the groups was plotted. Black plots indicate cases using a standard offset stem, and white plots indicate cases using a high offset stem.

Table 3. A comparison in offset and leg length to the opposite side.

Parameter	Amount of difference to the opposite side (mm, mean \pm SD)	
	Presurgery	Postsurgery
Acetabular offset	-11.5 ± 9.2	2.8 ± 7.6
Femoral offset	8.5 ± 11.8	-3.0 ± 11.7
Hip offset	-3.2 ± 10.3	-0.6 ± 8.8
Leg length	13.8 ± 15.4	-2.0 ± 13.6

A. According to Jingushi et al., the etiology of hip osteoarthritis in Japan was found to be acetabular dysplasia in most patients.¹⁸ We used the stem A and stem B for relatively mild DDH cases in this series. However, if the patients' backgrounds were compared between the two groups, the severity of hip dysplasia was more severe in the group with the stem B. In cases of DDH, femoral implant selection was determined by the severity of dislocation and morphologic deformity, such as excessive femoral neck anteversion or a narrow canal diameter.

In the past, cemented stems specifically designed for DDH were developed, but low survival rate was a serious problem.^{19–21} Recently, cementless modular stems have been frequently used for cases of femoral shortening osteotomy.^{22,23} Modular stems are also used to adjust neck version, neck length, and offset. However, modular stems have problems specific to their structure, such as breakage of the modular junction, and these have not yet been completely resolved. Also, cementless monoblock stems were developed for DDH patients. Although these stems have had favorable clinical results^{24,25} and a high survival rate, the high offset neck option was not commonly used until

recently.^{24,25} In the present study, the amount in anteversion between before and after surgery increased. To examine the individual changes in detail, postoperative implant neck anteversion was variable. It was considered as a result that the surgeon tried to insert stems with 15 to 30 degrees anteversion which considered optimal anteversion then. Intentional adjustment of stem rotation may be easier for surgeons using these stems. The stem B was selected for use based on two-dimensional preoperative templating using plain anteroposterior radiographs. Therefore, the stem size used the stem B may be smaller than that used the stem A. A high offset stem was used in 60%. In THA for that dysplasia case, to place the acetabular component in the original position is essential biomechanically. The center of the hip rotation moves back in the inferior and medial direction. As a result, acetabular offset decrease. If hip offset couldn't maintain, dislocation is concerned. So, to gain femoral offset, large sized stem is inserted and then excessive lengthening is also concerned. We named this as "offset dilemma" in THA. The use of a high offset stem may help prevent postoperative dislocation and excessive lengthening, and no dislocations occurred in the present study. Therefore, the clinical results represented by JOA Hip Score were excellent.

Regarding bone reaction around the stem, our previous experience with the original stem suggested that osteogenic reactions such as spot welds and cortical hypertrophy were frequently observed at the distal stem portion, which corresponded to Gruen zones 3 and 5. In this study, cortical hypertrophy was also frequently observed at Gruen zones 3 and 5, and spot welds were observed at Gruen zones 2, 3, 5, and 6. These findings suggest that the stems were biologically fixed in the middle to distal portion of the stems. As has been emphasized thus far, the phenomenon of distal fixation might come from the surface processing issue.²⁶ Gruen zones 3 and 5, where bone reactions frequently occurred, were exactly where the surface processing changed from grid blasting to polishing.

Stress shielding is bone resorption that occurs during bone remodeling that is caused by decreased stress transfer to the proximal femur, and it has a complex pathophysiology that is affected by multiple factors. In cases where the original stem was used, we found a significantly higher degree of stress shielding in patients using a larger stem compared to body height. In the present study, two-third hips were graded in mild stress shielding. Preoperative two-dimensional templating may be one of the reasons for this. Even if there was a size mismatch, stress shielding did not occur because of matching of the shape of the proximal portion.

In conclusion, these cementless tapered stems having a high offset option are suitable for patients with DDH if two-dimensional X-ray templates fit the shape of the proximal femurs. They were associated with excellent clinical results and biological fixation. The dual-offset option may be useful to adjust leg length and offset in DDH patients.

Acknowledgment

The authors thank Peter Mittwede, MD, PhD, from Edanz Group (www.edanzediting.com/ac) for editing a draft of this manuscript.


Declaration of conflicting interests

The author(s) declared no potential conflicts of interest with respect to the research, authorship, and/or publication of this article.

Funding

The author(s) received no financial support for the research, authorship, and/or publication of this article.

ORCID iD

Tomofumi Nishino  <https://orcid.org/0000-0002-6755-4900>

References

1. Sugano N, Noble PC, Kamaric E, et al. The morphology of the femur in developmental dysplasia of the hip. *J Bone Joint Surg Br Vol* 1998; 80: 711–719.
2. Noble PC, Kamaric E, Sugano N, et al. Three-dimensional shape of the dysplastic femur: implications for THR. *Clin Orthop Relat Res* 2003; 417: 27–40.
3. Johnston RC, Brand RA, and Crowninshield RD. Reconstruction of the hip. A mathematical approach to determine optimum geometric relationships. *J Bone Joint Surg Am Vol* 1979; 61: 639–652.
4. Jaroszynski G, Woodgate IG, Saleh KJ, et al. Total hip replacement for the dislocated hip. *Instr Course Lect* 2001; 50: 307–316.
5. Miyamoto T, Tomita M, Koseki H, et al. Morphology of the femoral neck in Japanese persons: analysis using CT data. *Acta Med Nagasaki*. 2014; 58: 119–124. <http://hdl.handle.net/10069/34223> (accessed March 2014).
6. Crowe JF, Mani VJ, and Ranawat CS. Total hip replacement in congenital dislocation and dysplasia of the hip. *J Bone Joint Surg Am Vol* 1979; 61: 15–23.
7. Charles MN, Bourne RB, Davey JR, et al. Soft-tissue balancing of the hip: the role of femoral offset restoration. *Instr Course Lect* 2005; 54: 131–141.
8. Dorr LD, Faugere MC, Mackel AM, et al. Structural and cellular assessment of bone quality of proximal femur. *Bone* 1993; 14: 231–242.
9. Barnett E and Nordin BE. The radiological diagnosis of osteoporosis: a new approach. *Clin Radiol* 1960; 11: 166–174.
10. Noble PC, Alexander JW, Lindahl LJ, et al. The anatomic basis of femoral component design. *Clin Orthop Relat Res* 1988; 235: 148–165.
11. Kuribayashi M, Takahashi KA, Fujioka M, et al. Reliability and validity of the Japanese Orthopaedic Association hip score. *J Orthop Sci* 2010; 15: 452–458.
12. Engh CA, Massin P, and Suthers KE. Roentgenographic assessment of the biologic fixation of porous-surfaced femoral components. *Clin Orthop Relat Res* 1990; 257: 107–128.

13. Gruen TA, McNeice GM, and Amstutz HC. "Modes of failure" of cemented stem-type femoral components: a radiographic analysis of loosening. *Clin Orthop Relat Res* 1979; 141: 17–27.
14. Engh CA, Bobyn JD, and Glassman AH. Porous-coated hip replacement. The factors governing bone ingrowth, stress shielding, and clinical results. *J Bone Joint Surg Br* 1987; 69: 45–55.
15. Dastane M, Dorr LD, Tarwala R, et al. Hip offset in total hip arthroplasty: quantitative measurement with navigation. *Clin Orthop Relat Res* 2011; 469: 429–436.
16. Murphy SB, Simon SR, Kijewski PK, et al. Femoral anteversion. *J Bone Joint Surg Am Vol* 1987; 69: 1169–1176.
17. Duncan CP and Masri BA. Fractures of the femur after hip replacement. *Instr Course Lect* 1995; 44: 293–304.
18. Jingushi S, Ohfuji S, Sofue M, et al. Multiinstitutional epidemiological study regarding osteoarthritis of the hip in Japan. *J Orthop Sci* 2010; 15: 626–631.
19. Digas G, Georgiades G, Lampropoulou-Adamidou K, et al. The twenty-year survivorship of two CDH stems with different design features. *Eur J Orthop Surg Traumatol* 2013; 23: 901–906.
20. Garvin KL, Bowen MK, Salvati EA, et al. Long-term results of total hip arthroplasty in congenital dislocation and dysplasia of the hip. A follow-up note. *J Bone Joint Surg Am Vol* 1991; 73: 1348–1354.
21. Woolson ST and Harris WH. Complex total hip replacement for dysplastic or hypoplastic hips using miniature or micro-miniature components. *J Bone Joint Surg Am Vol* 1983; 65: 1099–1108.
22. Benazzo FM, Piovani L, Combi A, et al. MODULUS stem for developmental hip dysplasia: long-term follow-up. *J Arthroplasty* 2015; 30: 1747–1751.
23. Claramunt RT, Marques F, Leon A, et al. Total hip replacement with an uncemented Wagner cone stem for patients with congenital hip dysplasia. *Int Orthop* 2011; 35: 1767–1770.
24. Nakamura Y, Nakata Y, Akita M, et al. Original cementless femoral stem for dysplastic hip: clinical results of HPF stem. *J Arthroplasty* 2007; 22: 553–559.
25. Tsukada S and Wakui M. A case series of total hip arthroplasty using cementless hip stem customized for patients of a specific race: 10- to 15-year results. *J Arthroplasty* 2016; 31: 190–193.
26. Nishino T, Mishima H, Kawamura H, et al. Follow-up results of 10-12 years after total hip arthroplasty using cementless tapered stem—frequency of severe stress shielding with synergy stem in Japanese patients. *J Arthroplasty* 2013; 28: 1736–1740.