

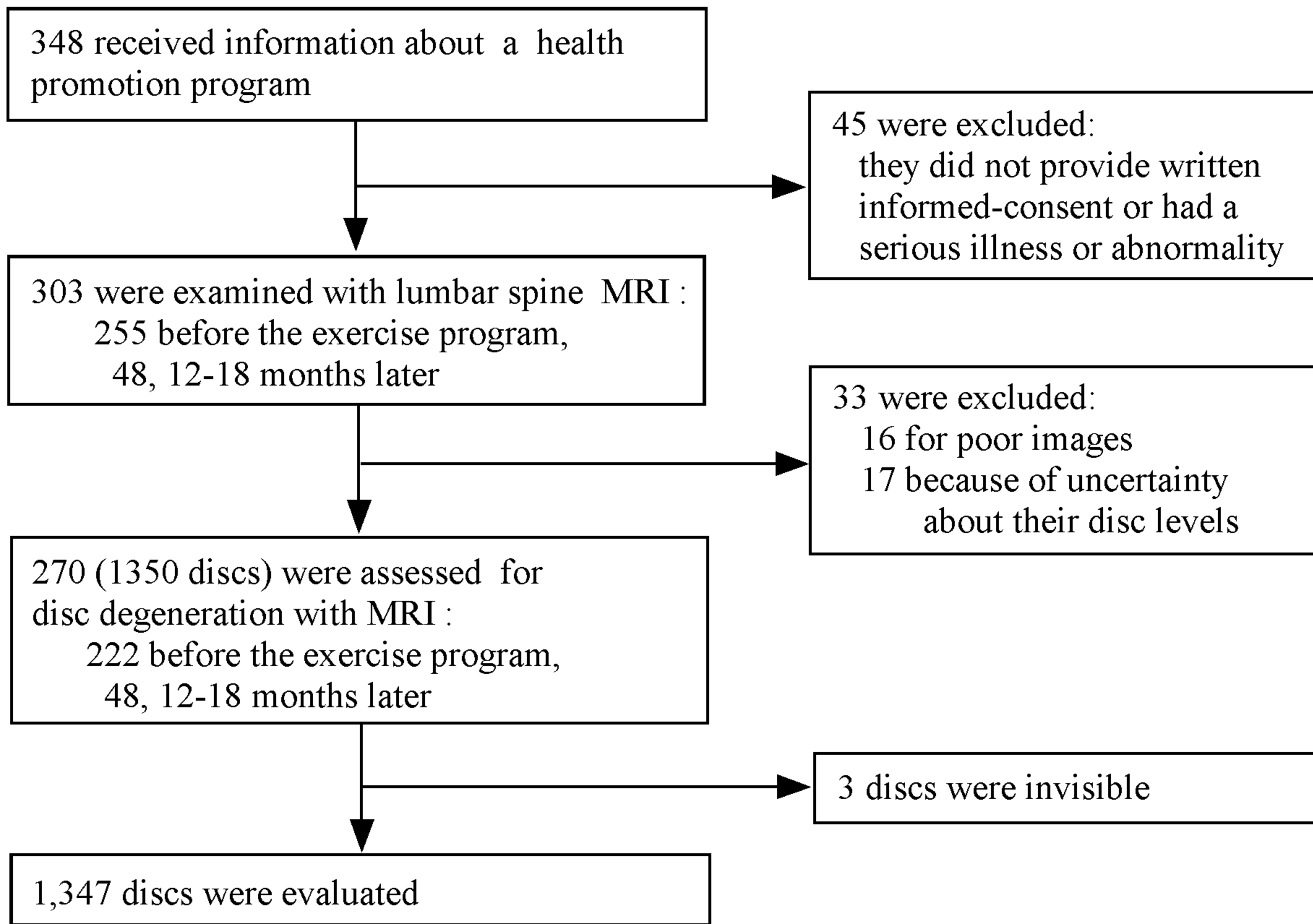Figure 1. Study profile.

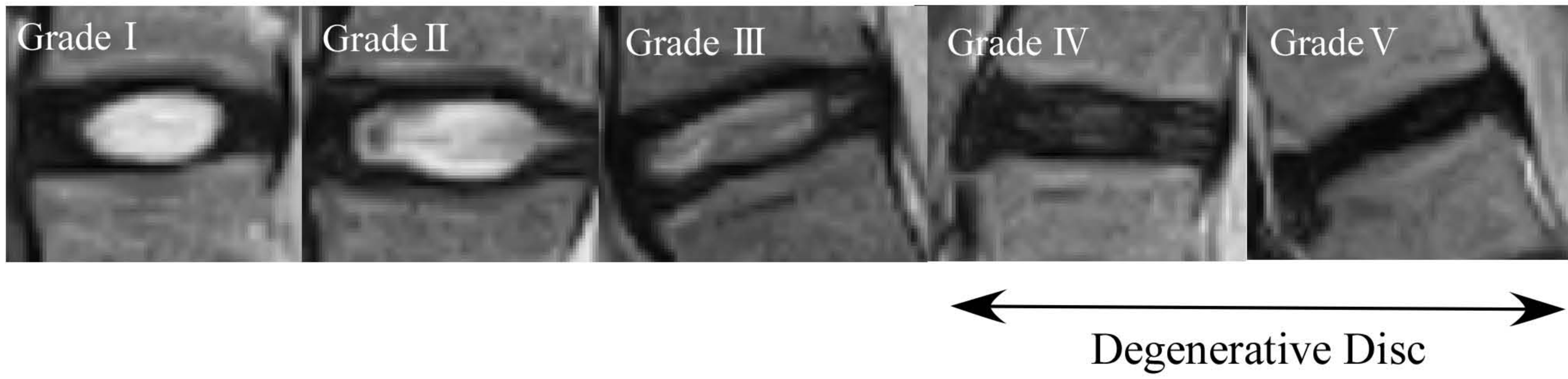


Figure 2.

Midsagittal view on T2 density-weighted images of discs graded according to a modified Pfirrmann's classification. The detail of the classification is described in Table 1. Grades IV and V were considered degenerated.