

Reconstruction using a vertical “ sagging cheek ” advancement flap for defects following full-thickness excision of non-melanoma skin cancer in the elderly: a case series

著者 (英)	Yasuko Niijima, Yosuke ISHITSUKA, Sae Inoue, Hiroshi Maruyama, Yoshiyuki Nakamura, Yasuhiro FUJISAWA, Manabu Fujimoto
journal or publication title	European Journal of Dermatology
volume	29
number	6
page range	654-656
year	2019-11
権利	(C) John Libbey Eurotext, 2019
URL	http://hdl.handle.net/2241/00161149

doi: 10.1684/ejd.2019.3659

1 Nonmelanoma skin cancer (NMSC) has become a major health concern,
2 particularly with the growing aging population in society. The number of surgically
3 treated squamous cell carcinoma (SCC) cases are comparable to basal cell carcinoma
4 (BCC) cases [1]. The preauricular area is the common primary site of SCCs in close
5 association with chronic ultraviolet damage [2]. Although primary closure is a better
6 solution in almost every circumstance, relatively large facial defects often pose a dilemma,
7 especially in oldest-old patients. A skin graft is a useful and standardized surgical
8 procedure, but it has obvious drawbacks. Distant donor site and specialized fixation
9 dressing can complicate the operative procedure itself. It sometimes requires frequent
10 visits or postoperative care under hospitalization, the latter of which enhances the risk of
11 delirium in the oldest-old [3]. For some patients, suboptimal color/texture match can be
12 a social/psychological burden because the cosmetic appearance profoundly affects the
13 quality of life, even life expectancy is limited [4, 5]. Here we present a case series of
14 NMSCs in which surgical defects were reconstructed with a vertical advancement flap
15 that efficiently utilizes “sagging cheek”, which has not been rarely described to date. This
16 simple surgical procedure can be performed under ambulatory settings and yields a rapid
17 recovery and superior cosmetic outcome (Fig. 1 c, d).

18 Operations were performed on 9 cases of NMSC (1 BCC and 8 SCCs) that

1 required repairing procedures other than primary closure from 2017 to 2018 by
2 dermatologists who have undergone basic training for several years (YI, HM, SI and
3 YN) in an ambulatory setting using local anesthesia (Fig. 1f). Mean patient age was 89
4 (83–96) years with a male: female ratio of 2:1. Tumors were excised with standard lateral
5 margin (4–6 mm) [2] on the plane of the superficial musculoaponeurotic system (SMAS),
6 resulting in a mean primary defect of 30.5 (22–36) mm in the largest diameter. Mean
7 operation time was 62.2 (45–75) minutes. The flap design differs from a conventional
8 design (Fig. 1a) in that parallel lines were vertically drawn from the lateral borders with
9 a length 1.0–1.5 times as long as the vertical diameter of defects (Fig. 1b), and the
10 Burow’s triangles were excised depending on tissue redundancy.

11 As the difference between the conventional design denotes, our method makes
12 sense with respect to the traction vector applied on the cheek (Fig. 1a, b). In the field of
13 aesthetic surgery, recent refinement in rhytidectomy has yielded a simple but effective
14 technique termed the minimal access cranial suspension lift [6]. This procedure takes
15 advantage of the vertical vector as with our design and avoids horizontal traction, while
16 traditional rhytidectomy comprises horizontal traction similarly to the conventional
17 design and results in re-draping in an oblique direction [6]. Moreover, due to the higher
18 flap stretchability, a relatively smaller area of undermining was necessary compared with

1 the conventional method, which could avoid postoperative bleeding complications.
2 Although there might still be controversy regarding vertically lined parallel scars, our
3 procedure follows the guiding principles; surgical margins are hidden within the natural
4 borders of the cheek unit, and the vertical lines are along relaxed skin tension lines [7].
5 In fact, skin laxity minimized postoperative scar formation, resulting in superior cosmetic
6 acceptability as long as performed on oldest-old patients (Fig. 1c–e).

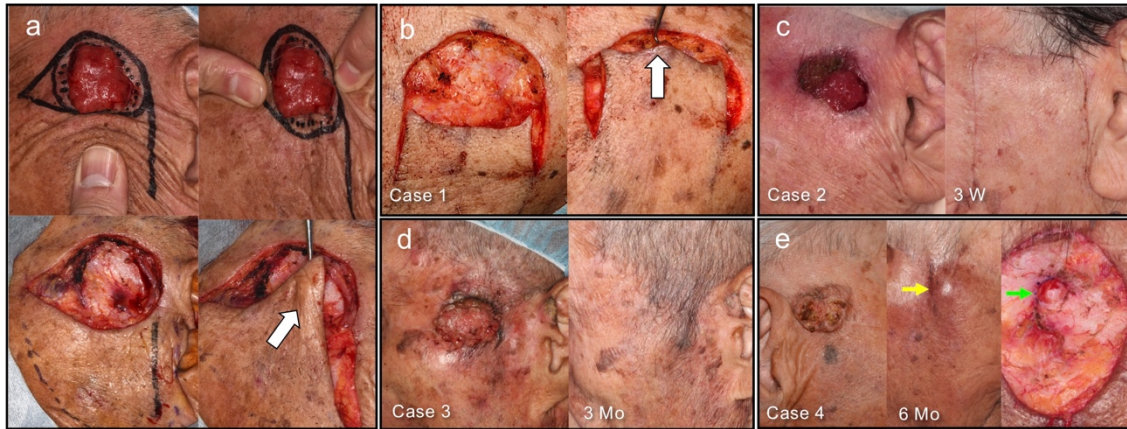
7 Since NMSC is a generally nonfatal condition, there is an ongoing debate on
8 whether short life expectancy should be taken into account in treatment decision making
9 [5]. However, it should be noted that the periauricular area confers an independent high-
10 risk factor of SCC [2]. Therefore, invasiveness of procedures should not be determined
11 by patients' age on a one-size-fits-all basis [5], and complete disease control should
12 always be sought [2]. Indeed, we have experienced the cases of local recurrence or lymph
13 node metastasis after the operation; the former (Fig. 1e, case 4) was manageable with
14 extended resection followed by chemoradiotherapy using fluorouracil plus cisplatin up to
15 30 months' follow up (Fig. 1e), and the latter remains in complete remission for 10 months
16 after cervical lymph node dissection (case 7). Therefore, as long as once meticulous
17 preoperative consideration and close observation are completed, our simple and efficient
18 method could be an attractive reconstructive option.

1 **Financial support: None**

2 **Conflict of Interest: None**

3 **References**

- 4 1. Rogers HW, Weinstock MA, Feldman SR, Coldiron BM. Incidence Estimate of
5 Nonmelanoma Skin Cancer (Keratinocyte Carcinomas) in the U.S. Population, 2012.
6 *JAMA Dermatol.* 2015; 151(10): 1081-6. 2015/05/01. doi:
7 10.1001/jamadermatol.2015.1187
- 8 2. Work G, Invited R, Kim JYS, *et al.* Guidelines of care for the management of cutaneous
9 squamous cell carcinoma. *J Am Acad Dermatol.* 2018; 78(3): 560-78. 2018/01/15. doi:
10 10.1016/j.jaad.2017.10.007
- 11 3. Inouye SK, Westendorp RG, Saczynski JS. Delirium in elderly people. *Lancet.* 2014;
12 383(9920): 911-22. 2013/09/03. doi: 10.1016/S0140-6736(13)60688-1
- 13 4. Imadojemu S, Sarwer DB, Percec I, *et al.* Influence of surgical and minimally invasive
14 facial cosmetic procedures on psychosocial outcomes: a systematic review. *JAMA*
15 *Dermatol.* 2013; 149(11): 1325-33. 2013/09/27. doi: 10.1001/jamadermatol.2013.6812
- 16 5. Linos E, Chren MM, Stijacic Cenzer I, Covinsky KE. Skin Cancer in U.S. Elderly
17 Adults: Does Life Expectancy Play a Role in Treatment Decisions? *J Am Geriatr Soc.*
18 2016; 64(8): 1610-5. 2016/06/16. doi: 10.1111/jgs.14202
- 19 6. Verpaele A, Tonnard P, Gaia S, Guerao FP, Pirayesh A. The third suture in MACS-
20 lifting: making midface-lifting simple and safe. *J Plast Reconstr Aesthet Surg.* 2007;
21 60(12): 1287-95. 2007/07/03. doi: 10.1016/j.bjps.2006.12.012
- 22 7. Robinson JK, Hanke CW, Siegel DM, Fratila A, Bhatia AC, Rohrer TE. *Surgery of the*
23 *Skin E-Book: Procedural Dermatology*: Elsevier Health Sciences, 2014.
- 24



f

Case	Age/Sex	Diagnosis	Site*	Size (mm)	Horizontal Margin (mm)	Recurrence or Metastasis (After Operation)	Additional Treatment	Specific High-Risk Features [†]
1	89/M	SCC	P	18 × 16	4	N/A	N/A	N/A
2	96/F	SCC	P	27 × 25	4	N/A	N/A	Rapid Growth (2 Months)
3	90/M	SCC	P	30 × 25	5	N/A	N/A	N/A
4	83/M	SCC	P	30 × 20	6	Local Recurrence (6 Month)	Resection + Chemoradiation	Recurrent Case, Perineural Invasion
5	92/F	SCC	P	30 × 30	4	N/A	N/A	N/A
6	88/M	SCC	P	28 × 25	5	N/A	N/A	N/A
7	86/M	SCC	P	25 × 25	5	Cervical LN Metastasis (10 Months)	LN Dissection	Rapid Growth (1 Month), Poor Differentiation (Spindle Cell Variant)
8	85/M	BCC	C	20 × 20	5	N/A	N/A	N/A
9	92/F	SCC	P	25 × 25	4	N/A	N/A	Rapid Growth (2 Months)

* P: preauricular, C: cheek

[†] Since patient age, primary site (cheek) and size (≥ 10 mm) constitute high-risk features (ref. 2), other specific features are addressed.

Figure

Representative operational view of vertical cheek advancement flap (a)–(e) and the list of NMSC cases treated with a "sagging cheek" advancement flap (f).

(a) SCC (28 × 25 mm) arisen on the left preauricular area of the 88-year-old male was excised on the SMAS plane, leaving a full-thickness defect (33 × 30 mm). Although vertical advancement is utilized, the traction vector is oblique (white arrow).

(b) Case 1; SCC was excised on the SMAS plane, leaving a full-thickness defect. The flap was stretched easily due to the skin laxity, and Burow's triangles were placed depending on tissue redundancy. Note the flap is easily stretched vertically, suggesting that aging-related sagging is utilized efficiently.

(c) Case 2; Two paralleled vertical scars are seen on the cheek 3 weeks after the operation. Note the rapid recovery and reduced wrinkles.

(d) Case 3; A good cosmetic outcome was achieved 3 months after the operation.

(e) Case 4; Subcutaneous nodule (yellow arrow) emerged 6 months after the operation,

1 and the tumor was identifiable beneath the SMAS plane (green arrow). Extended
2 resection left a facial nerve paralysis.