

## Chronic expanding hematoma in the chest: A case report

著者別名	?屋敷 典生, 井口 けさ人, 籠橋 克紀, 佐藤 浩昭, 中澤 健介, 檜澤 伸之
journal or publication title	Experimental and therapeutic medicine
volume	15
number	6
page range	5457-5460
year	2018-06
URL	<a href="http://hdl.handle.net/2241/00153121">http://hdl.handle.net/2241/00153121</a>

doi: 10.3892/etm.2018.6091

# Chronic expanding hematoma in the chest: A case report

TAKAFUMI SAKUMA<sup>1</sup>, NORIO TAKAYASHIKI<sup>2</sup>, KESATO IGUCHI<sup>3</sup>, KATSUNORI KAGOHASHI<sup>4</sup>,  
HIROAKI SATOH<sup>4</sup>, KENSUKE NAKAZAWA<sup>5</sup> and NOBUYUKI HIZAWA<sup>5</sup>

Divisions of <sup>1</sup>General Medicine, <sup>2</sup>Pathology, <sup>3</sup>Surgery and <sup>4</sup>Respiratory Medicine, Mito Medical Center, University of Tsukuba-Mito Kyodo General Hospital, Mito, Ibaraki 310-0015; <sup>5</sup>Division of Respiratory Medicine, Faculty of Medicine, University of Tsukuba, Tsukuba, Ibaraki 305-8575, Japan

Received January 15, 2016; Accepted February 14, 2017

DOI: 10.3892/etm.2018.6091

**Abstract.** Chronic expanding hematoma (CEH) is a rare disease that is usually present as a large solitary pulmonary nodule. CEHs are slow growing, but processes underlying their development remain unknown. The present study herein reports the case of a 76-year-old male patient with CEH and discusses a number of CEH cases published in the literature. The majority of these previously described patients were Asians. The CEH in the present case was not a successfully resected one, but the patient's clinical course provided information concerning the natural history of the disease. During the clinical course, the patient underwent several chest computed tomography scans. For the present case report, the doubling time and volume change of the mass was calculated, which revealed that the lesion had an inconstant growth rate and that its onset was between 8.2-11.0 years before the patient succumbed to this disease. Accumulation of knowledge about this rare disease will help to elucidate it further.

## Introduction

Hematomas are masses of usually clotted blood that form in tissues, organs or body spaces as a result of a broken blood vessel (1-3). Among hematomas, chronic expanding hematomas (CEHs) are rare (1-21). Chronic inflammation, invoked by hematoma, is thought to lead to the formation of a capsule around the hematoma, and new vessel growth in and around the capsule (22). Furthermore, the gradual formation of a hematoma accompanies leakage of blood from the new vessels, which increases permeability through a plasminogen activator that is precipitated in the clot (1). The majority of patients with CEH in the chest typically have a history of medical or surgical

therapy for tuberculosis (2-14), although some develop CEH after thoracic surgery for non-tuberculous diseases (15-19) or blunt thoracic trauma (19-21). CEH was initially reported as a clinical entity in the 1980s, but the exact prevalence of CEH within populations and mortality rates are unknown because of its rarity. The symptoms of CEH differ depending on the site where CEH occurs, but similar symptoms accompanying the increase of CEH have been identified. When CEH occurs in the chest, dyspnea and chest wall masses occur due to an increase in the volume of the hematoma (22). In a recent review of the Japanese and English literature, only 91 patients with this disease have been described (22). According to the review, they had a broad age distribution; 70.3% of them were male, and lesions were predominantly on the trunk and lower extremities. The range of clinical latent periods was wide, ranging from one month to 57 years (1,23-26). A commonly used treatment method for CEH is complete excision, which yields the best clinical outcomes (26). The current report presents the natural history of a CEH that presented as a slow-growing mass, which was determined by calculating its doubling time and volume changes.

## Case report

A 76-year-old man was referred to the University of Tsukuba-Mito Kyodo General Hospital (Mito, Japan) in March 2013 because of dyspnea upon exertion, which had first become apparent 4 years before. A large mass with a maximum diameter of 17x12 cm had been found on a chest X-ray nine years ago in a mass screening by the prefecture where the patient lived. This finding was followed up for seven years at a local clinic near the patient's address by chest X-ray, and the mass was slowly growing. However, the patient did not want further examination and treatment during this period. Thereafter, the patient visited the thoracic surgery department in University of Tsukuba Hospital (Tsukuba, Japan) in August 2013, but decided not to undergo surgical removal of the lesion. In addition, the patient had a 10 pack-years smoking history up to the age of 45, and reported that he had suffered a blunt chest trauma in a traffic accident 29 years before, but no medical record or imaging study of this was available.

On admission to the University of Tsukuba-Mito Kyodo General Hospital, respiratory sounds in the left lung were absent and heart sounds were audible in the right thorax. A

---

*Correspondence to:* Professor Hiroaki Satoh, Division of Respiratory Medicine, Mito Medical Center, University of Tsukuba-Mito Kyodo General Hospital, Miya-machi 3-2-7, Mito, Ibaraki 310-0015, Japan  
E-mail: hirosato@md.tsukuba.ac.jp

**Key words:** chronic expanding hematoma, doubling time, volume change, autopsy

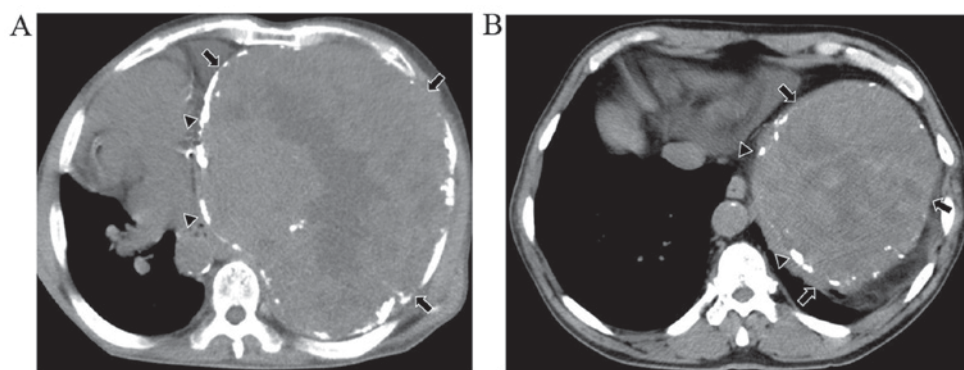


Figure 1. (A) Chest CT scan at the admission to the University of Tsukuba-Mito Kyodo General Hospital showed a mass of inhomogeneous density (arrows) with focal calcification within the mass (triangles). (B) Chest CT scan taken 9 years before the patient's mortality. CT, computed tomography.

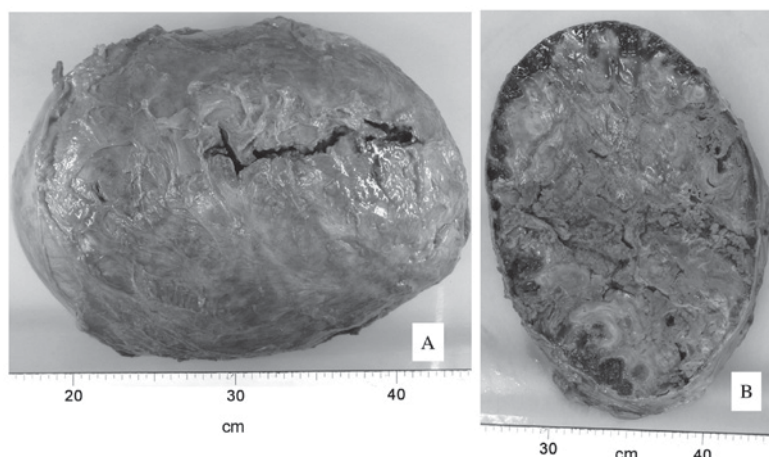


Figure 2. (A) Mass, removed at autopsy, containing coagulative necrotic tissue occupied the entire left thoracic cavity. (B) The lesion was encased in a thick capsule, and the inside of the mass was composed of a hematoma with vascular organization.

chest radiograph and computed tomography (CT) revealed a mass of inhomogeneous density, with focal calcification within the mass (Fig. 1A). A percutaneous biopsy was performed but the pathological diagnosis was not established because only necrotic tissue was present within the specimen. The patient was discharged, and he received oxygen therapy at home because he did not want any further invasive treatment, then his respiratory condition gradually deteriorated. Furthermore, the patient succumbed to respiratory failure two years after the initiation of home oxygen therapy and died in March 2015. Over the course of the patient's illness, he received seven chest CT scans. Fig. 1B reports the chest CT scan taken 9 years prior to patient mortality. Finally, an autopsy was performed and the final diagnosis of the mass was CEH.

With regard to the autopsy observations, grossly, a 29 cm, 5.9 kg mass containing coagulative necrotic tissue occupied the entire left thoracic cavity (Fig. 2A). The wall of the lesion was well demarcated, strongly adherent and was expanding to the surrounding structures. In addition, the lesion was encased in a thick capsule (Fig. 2B), and there was no evidence of neoplasia. Fig. 3 shows the relationship between 'volume of mass' and 'days prior to mortality' using the results from CT scans taken over the course of the patient's disease.

The graph line, which was constructed by taking plots of the estimated volume of the lesion and analyzed with VINCENT

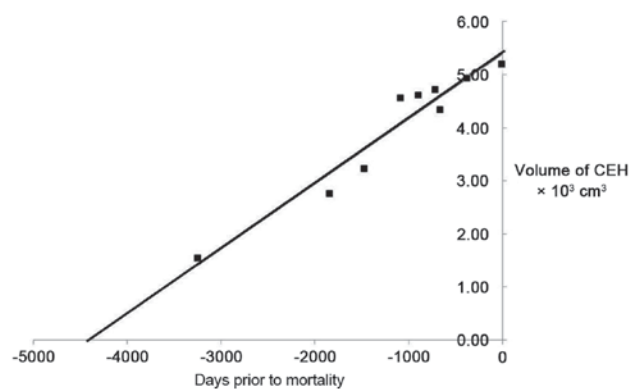


Figure 3. Change in the mass volume calculated and extrapolated.

v. 4.0 (Fujifilm Workstation, Tokyo, Japan), the time when the CEH began to develop was evaluated using the least-squares method (27). The estimation indicated that the onset time of CEH was 8.2-11.0 years before the patient mortality.

The doubling time of the disease (DTD) was calculated using the chest CT scans that were recorded 7 times during the clinical course. The DTD was calculated using a modification of the following Schwartz formula of exponential growth (28):  $DTD = (tx \log 2) / (3x \log (V_2/V_1))$ ; where  $V_1$  and

Table I. Doubling time of the chronic expanding hematoma.

Days prior to mortality	Interval, days	Doubling time, days
-5 to -373	368	2,072
-373 to -665	292	3,626
-665 to -1,089	424	1,896
-1,089 to -1,474	385	7,296
-1,474 to -1,839	365	1,818
-1,839 to -3,246	1,407	3,549

V2 were the largest diameters on the CT scan measured at 2 different times, and t was the time interval between 2 measurements. The DTD of the CEH in this patient is shown in Table I.

## Discussion

CEH in the chest is a rare clinicopathological entity. The majority of patients with this disease have a history of medical or surgical therapy for tuberculosis (2-14), although some develop CEH after thoracic surgery for non-tuberculous diseases (15-18) or blunt thoracic trauma (19-21). The most common symptoms of CEH in the chest are dyspnea related to compression of the lung, and slowly growing chest wall mass (22). Although the possibility of being treated as another disease in countries outside Northeast Asia cannot be denied, almost of the patients previously reported to have CEH in the chest were Japanese (3-6,8,9,11-14) with some from other Northeast Asian countries (2,7,10). Radiologically, CEH in the chest appears as an intrathoracic mass in chest X-ray. Findings in chest CT scan consist of a heterogeneous mass with a wall of variable thickness that often contains peripheral areas of calcification (4). The pathogenesis of CEH is still unknown. According to a theory by Labadie and Glover, however, the self-perpetuating expanding process in CEH is due to the irritant effects of blood and its breakdown products, which cause repeated episodes of bleeding from capillaries in the granulation tissue (1). The range of clinical latent period in previous reports is wide, ranging from 1 month to 57 years (1,23-26).

In the present case, a surgical resection of the lesion could not be performed due to the patient's refusal to undergo surgery. As a result, the clinical course of the disease could be observed from the time of the first CT scan taken 9 years before his referral to the hospital. CEH may grow very slowly, however, the natural course of the disease has not been elucidated, either for those with a prior history of tuberculosis or for those without it.

Currently, the natural history, pathogenesis and mechanism of CEH are unknown. It is important to provide and accumulate knowledge on the increase in the size of the lesion and on its doubling time. The present study therefore showed the DTD (Table I) and the volume change of CEH. The estimation indicated that the onset time of CEH was 8.2-11.0 years before the patient mortality. However, this onset time was not the same as that at which he said he had suffered a blunt chest trauma in a traffic accident (about 26 years before succumbing

to the present disease). As no medical records or imaging were available, the difference cannot be explained but it is believed that this chest trauma had no direct association with the development of CEH. The patient of the present study had no prior history of tuberculosis and a relatively short interval between the prior medical event and the development of CEH, which was consistent with the results of previous cases with no prior history of tuberculosis (2-14).

Therefore, the present study has reported a case of CEH. The patient did not undergo any surgical resection due to his refusal of surgery, but this case illustrated a natural course of CEH, which may provide clues towards clarifying the mechanism and etiology of CEH. Furthermore, accumulation of knowledge about this rare disease will help to elucidate it further.

## Acknowledgements

The authors thank Dr Yoko Deguchi for her skillful clinical management of the patient. We are especially grateful to Ms. Flaminia Miyamasu for her review of the manuscript and Ms. Kikue Sato for her secretarial assistance.

## References

1. Labadie EL and Glover D: Physiopathogenesis of subdural hematomas. Part I. Histological and biochemical comparisons of subcutaneous hematoma in rats with subdural hematoma in man. *J Neurosurg* 45: 1382-1392, 1976.
2. Dezube R, Terry P, Akulian J, Mathai SC, Boyle M, Khasab T and Yarmus L: Chronic expanding hematoma of the lung. *Am J Respir Crit Care Med* 188: e71, 2013.
3. Nomori H, Horio H, Kobayashi R and Morinaga S: Expanding intrathoracic hemorrhagic lesion penetrating the thoracic wall: A rare complication of chronic tuberculous pleurisy. *Thorac Cardiovasc Surg* 43: 358-360, 1995.
4. Hanagiri T, Muranaka H, Hashimoto M, Nishio T, Sakai S, Ono M, Toyoshima S and Nagashima A: Chronic expanding hematoma in the chest. *Ann Thorac Surg* 64: 559-561, 1997.
5. Akata S, Ohkubo Y, Jinho P, Saito K, Yamagishi T, Yoshimura M, Kotake F, Kakizaki D and Abe K: MR features of a case of chronic expanding hematoma. *Clin Imaging* 24: 44-46, 2000.
6. Uramoto H, Nakanishi R, Eifuku R, Muranaka H, Takenoyama M, Yoshino I, Osaki T and Yasumoto K: Chronic expanding hematoma in the chest. *J Cardiovasc Surg (Torino)* 41: 143-146, 2000.
7. Roper CL and Cooper JD: Chronic expanding hematoma of the thorax. *J Thorac Cardiovasc Surg* 122: 1046-1048, 2001.
8. Sato M, Kosaka S and Takahashi T: Life threatening chronic expanding hematoma of the thorax. *J Cardiovasc Surg (Torino)* 45: 511-514, 2004.
9. Okubo K, Okamoto T, Isobe J and Ueno Y: Rupture of a chronic expanding hematoma of the thorax into lung parenchyma. *J Thorac Cardiovasc Surg* 127: 1838-1840, 2004.
10. Kwon YS, Koh WJ, Kim TS, Lee KS, Kim BT and Shim YM: Chronic expanding hematoma of the thorax. *Yonsei Med J* 48: 337-340, 2007.
11. Tsubochi H, Sato N and Imai T: Chronic expanding hematoma with bronchopleural fistula and empyema space. *Ann Thorac Cardiovasc Surg* 15: 171-173, 2009.
12. Takahama M, Yamamoto R, Nakajima R, Izumi N and Tada H: Extrathoracic protrusion of a chronic expanding hematoma in the chest mimicking a soft tissue tumor. *Gen Thorac Cardiovasc Surg* 58: 202-204, 2010.
13. Muramatsu T, Shimamura M, Furuichi M, Ishimoto S, Ohmori K and Shiono M: Treatment strategies for chronic expanding hematomas of the thorax. *Surg Today* 41: 1207-1210, 2011.
14. Ueda H, Baba H and Ondo K: Treatment of chronic expanding hematoma of the thorax with median sternotomy. *Gen Thorac Cardiovasc Surg* 61: 466-468, 2013.
15. Shimokawa T, Hattori R, Hayashida R and Hayashi A: Chronic expanding hematoma following pneumonectomy managed with a thoracic balloon: A case report. *Kyobu Geka* 50: 417-420, 1997 (In Japanese).

16. Kunisawa S, Kosaka S, Matsukura T, Nakashima T, Okabayashi T, Miyagawa H and Miyake Y: Chronic expanding hematoma in sternum resected 5 years after median sternotomy. *Ann Thorac Surg* 85: 1447-1448, 2008.
17. Maniwa Y, Okada M, Ishii N, Yoshida M, Sakamoto T and Harada N: A surgical case for the huge chronic expanding hematoma developed in the thoracic cavity. *Kyobu Geka* 50: 1069-1073, 1997 (In Japanese).
18. Kainuma S, Masai T, Yamauchi T, Takeda K, Iwakura K, Ito H, Abe K and Sawa Y: Chronic expanding intrapericardial hematoma after coronary artery bypass surgery presenting with congestive heart failure. *Ann Thorac Cardiovasc Surg* 14: 52-54, 2008.
19. Kawachi H, Shirakata S, Niu S, Takahashi A, Oga K and Oka T: A case of 'chronic expanding hematoma', with an intrapulmonary fresh hemorrhage resected 25 years after thoracic injury. *Nihon Kyobu Geka Gakkai Zasshi* 38: 1068-1072, 1990 (In Japanese).
20. Kouritas VK, Roussakis AG, Soultanis K and Bellenis I: Extrathoracic chronic hematoma presenting as a chest wall tumor 2 years after a blunt thoracic injury. *J Cardiothorac Surg* 6: 156, 2011.
21. Kuronuma K, Ootake S, Ikeda K, Taniguchi M, Takezawa C and Takahashi H: Chronic expanding hematoma in the chest. *Intern Med* 47: 1411-1414, 2008.
22. Ito T, Nakahara T, Takeuchi S, Uchi H, Takahara M, Moroi Y and Furue M: Four cases of successfully treated chronic expanding soft tissue hematoma. *Ann Dermatol* 26: 107-110, 2014.
23. Friedlander HL and Bump RG: Chronic expanding hematoma of the calf. A case report. *J Bone Joint Surg Am* 50: 1237-1241, 1968.
24. Reid JD, Kommareddi S, Lanckerani M and Park MC: Chronic expanding hematomas. A clinicopathologic entity. *JAMA* 244: 2441-2442, 1980.
25. Miyazaki H, Goto A, Hino R, Ota S, Okudaira R, Murakawa T, Nakajima J and Fukayama M: Pleural cavity angiosarcoma arising in chronic expanding hematoma after pneumonectomy. *Hum Pathol* 42: 1576-1579, 2011.
26. Saotome K, Koguchi Y, Tamai K, Sakai H, Ohno W and Yamato M: Enlarging intramuscular hematoma and fibrinolytic parameters. *J Orthop Sci* 8: 132-136, 2003.
27. Pollack A, Zagars GK and Kavadi VS: Prostate specific antigen doubling time and disease relapse after radiotherapy for prostate cancer. *Cancer* 74: 670-678, 1994.
28. Nakamura R, Inage Y, Tobita R, Mori K, Numata T, Yanai H, Endo T, Ohtani H, Satoh H, Yuzawa K, *et al*: Epidermal growth factor receptor mutations: Effect on volume doubling time of non-small-cell lung cancer patients. *J Thorac Oncol* 9: 1340-1344, 2014.