


## Bezold ' s abscess in a diabetic patient without significant clinical symptoms

著者別名	小林 裕幸
journal or publication title	IDCases
volume	12
page range	e1-e2
year	2017-03
権利	(C) 2017 The Authors. Published by Elsevier Ltd. This is an open access article under the CC BY-NC-ND license ( <a href="http://creativecommons.org/licenses/by-nc-nd/4.0/">http://creativecommons.org/licenses/by-nc-nd/4.0/</a> ). T Previous PDF in this issueNext PDF in this issue
URL	<a href="http://hdl.handle.net/2241/00153084">http://hdl.handle.net/2241/00153084</a>

doi: 10.1016/j.idcr.2017.04.006



## Case report

## Bezold's abscess in a diabetic patient without significant clinical symptoms

Kohta Katayama<sup>a</sup>, Harumi Gomi<sup>b,\*</sup>, Taijiro Shirokawa<sup>c</sup>, Hiromitsu Akizuki<sup>d</sup>, Hiroyuki Kobayashi<sup>e</sup><sup>a</sup> Department of General Medicine, Shirakawa Satellite for Teaching And Research (STAR), Fukushima Medical University, Shirakawa, Japan<sup>b</sup> Center for Global Health, Mito Kyodo General Hospital, University of Tsukuba, Japan<sup>c</sup> Department of Laboratory Medicine, Tokyo Medical University Hospital, Japan<sup>d</sup> Department of Otorhinolaryngology, Mito Kyodo General Hospital, University of Tsukuba, Japan<sup>e</sup> Department of Medicine, Mito Kyodo General Hospital, University of Tsukuba, Japan

## ARTICLE INFO

## Keywords:

Bezold's abscess

Diabetes mellitus

*Streptococcus pneumoniae*

## ABSTRACT

A 52-year-old Japanese man with a history of type 2 diabetes mellitus (DM) presented with mild dizziness. On admission, the physical examination only revealed tachycardia and right sided cervical lymphadenopathy. On the fifth day of admission, his mental status slightly worsened. Urgent Computed Tomography (CT) of the head and neck revealed multiple abscesses spreading from the right temporal bone to the right sternocleidomastoid muscle. Bezold's abscess was diagnosed. *Streptococcus pneumoniae* was isolated from middle ear fluid and blood cultures.

Bezold's abscess has rarely been described in the era of antimicrobial therapy. However this abscess can still occur in patients without any typical severe symptoms. Repeated history taking and thorough physical examination can help detect Bezold's abscess.

## Introduction

Bezold's abscess was first described as a deep neck abscess arising from mastoiditis by Friedrich Bezold in 1881 [1]. The strong attachment of the sternocleidomastoid, trapezius, splenius capitis and longissimus capitis muscles to mastoid process prevent the inflammation from reaching the skin surface. This process may be difficult to assess on physical examination. We report a patient with uncontrolled diabetes mellitus, in whom a diagnosis of Bezold's abscess was successfully made radiographically only with subtle clinical symptoms in a timely fashion.

## Case report

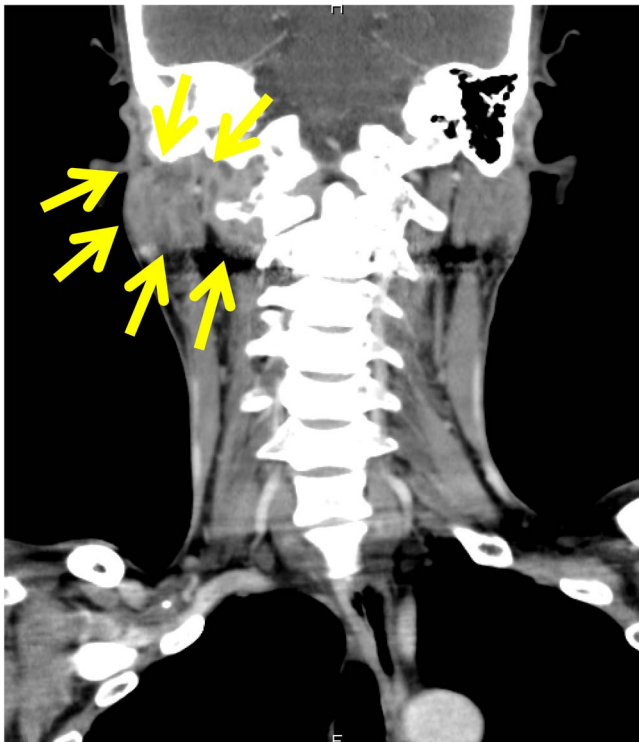
A 52-year-old Japanese man with a history of type 2 diabetes and hyperlipidemia presented with mild dizziness. Several months prior to admission, he had been diagnosed with right-sided otitis media by his primary physician and treated with oral antimicrobials. He then discontinued the therapy himself.

On admission, his vital signs were unremarkable except increased heart rate of 103 beats per minute. He was alert and oriented to time, place, and person. The physical examination revealed lymphadenopathy at the posterior side of the right sternocleidomastoid muscle. The blood test on admission was significant for the following: leukocyte

count 9100/μL, erythrocyte sedimentation rate 67 mm per hour, hemoglobin A1c 13.3%, and serum glucose level 350 mg/dL. During the first three days of admission, his right cervical lymphadenopathy persisted.

On the fifth day of admission, his mental status slightly worsened. Two sets of blood culture were obtained. CT of the head and neck with contrast material was performed. It revealed multiple abscesses spread from right temporal bone to the right sternocleidomastoid muscle (Fig. 1). It also demonstrated osteolysis at his right mastoid process. Eardrum puncture was performed urgently. Gram stain of the specimen from the middle ear showed Gram positive cocci. Bezold's abscess was diagnosed and the patient was treated empirically with ceftriaxone 2 g twice a day and metronidazole 500 mg three times a day. On the seventh day of admission, *Streptococcus pneumoniae* sensitive to penicillin, MIC < 0.03 μg/mL, was isolated from middle ear fluid. One set of blood culture turned positive. On the 12th day of admission, *Streptococcus pneumoniae* consistent with eardrum fluid culture was isolated from blood culture. On the 15th day of admission, mastoidectomy was performed for drainage. The patient improved clinically after the drainage. On the 46th day of admission, no residual abscess was seen in the CT of the head with contrast material and he was discharged home.

\* Corresponding author at: Center for Global Health, Mito Kyodo General Hospital, University of Tsukuba, 3-2-7, Miyamachi, Mito, Ibaraki, 310-0015, Japan.  
E-mail address: [hgomi-oky@umin.org](mailto:hgomi-oky@umin.org) (H. Gomi).



**Fig. 1.** Computed Tomography (CT) of the head and neck with contrast material. The yellow arrow indicates multi-loculated abscess formation in the right posterior neck.

## Discussion

Otitis media is a potentially life-threatening disease due to its complication. Hippocrates once noted that acute pain of the ear with

continued high fever is to be dreaded since the patient may become delirious and die. In the era before antimicrobials, fifty percent of patients suffering from otitis media developed a coalescent mastoiditis and twenty percent of patients with mastoiditis developed this abscess [2]. Nowadays when antimicrobials are regularly available, complications of otitis media including Bezold's abscess are extremely rare.

In Japan, a total of 28 cases of Bezold's abscess including our case have been reported in the literature since 1960. In most cases, neck swelling, fever, and neck pain are the key symptoms to the diagnosis of Bezold's abscess [2]. We could not find these typical symptoms from our patient. Our patient only complained of dizziness. Slight but persistent right-sided cervical lymphadenopathy and progressively worsened mental status triggered us to perform CT of the head and neck immediately.

We report herein a patient of Bezold's abscess presented without any typical symptoms such as fever and neck pain. Immunosuppressive state such as DM obscures the symptoms of abscess. This case is an excellent reminder for all clinicians for this potentially fatal disease.

## Ethical approval

None required

## Conflict of interest

All authors report that there is no conflict of interest.

## References

- [1] Castillo M, Albernaz V, Mukherji S, Smith M, Weissman J. Imaging of Bezold's abscess. *AJR Am J Roentgenol* 1998;171(6):1491–5.
- [2] Uchida Y, Ueda H, Nakashima T. Bezold's abscess arising with recurrent cholesteatoma 20 years after the first surgery: with a review of the 18 cases published in Japan since 1960. *Auris Nasus Larynx* 2002;29(4):375–8.