

# Efficacy of bevacizumab therapy in recurrent malignant gliomas in relation to the prior recurrence pattern or tumor location

著者別名	松田 真秀, 石川 栄一, 山本 哲哉, 阿久津 博義, 高野 晋吾, 松村 明
journal or publication title	Journal of clinical neuroscience
volume	40
page range	115-119
year	2017-06
権利	(C) 2017. This manuscript version is made available under the CC-BY-NC-ND 4.0 license <a href="http://creativecommons.org/licenses/by-nc-nd/4.0/">http://creativecommons.org/licenses/by-nc-nd/4.0/</a>
URL	<a href="http://hdl.handle.net/2241/00151265">http://hdl.handle.net/2241/00151265</a>

doi: 10.1016/j.jocn.2017.02.025

**Efficacy of bevacizumab therapy in recurrent malignant gliomas in relation to the prior recurrence pattern or tumor location**

Masahide Matsuda, Eiichi Ishikawa, Tetsuya Yamamoto, Hiroyoshi Akutsu, Shingo

Takano, Akira Matsumura

Department of Neurosurgery, Faculty of Medicine, University of Tsukuba, Tsukuba,

Ibaraki, Japan

**Correspondence:** Masahide Matsuda, M.D., Ph.D., Department of Neurosurgery,

Faculty of Medicine, University of Tsukuba, Tsukuba, Ibaraki 305-8575, Japan.

Tel: +81-298-53-3220, Fax: +81-298-53-3214, E-mail: m-matsuda@md.tsukuba.ac.jp

**Sources of support:** This research did not receive any specific grant from funding agencies in the public, commercial, or not-for-profit sectors.

## Abstract

Although promising preliminary results have been widely observed with bevacizumab for recurrent malignant gliomas, many unanswered questions remain to be resolved to achieve an optimal outcome. No predictive biomarkers of a survival benefit from bevacizumab have been established, and no consensus exists about the response or survival benefit regarding the prior recurrence pattern or tumor location. Here we retrospectively analyzed the clinical benefit from bevacizumab for recurrent malignant gliomas in relation to the prior recurrence pattern or tumor location. Thirty-one consecutive patients with recurrent malignant gliomas who were treated with bevacizumab were investigated. The treatment response and survival benefit from bevacizumab were analyzed in association with age, sex, Karnofsky performance status, prior pathological diagnosis, prior recurrence pattern, primary location of tumor, recurrence status, and expression of angiogenic and hypoxic markers. The group with leptomeningeal dissemination had a significantly shorter median overall survival with bevacizumab ( $OS_{Bev}$ ) (6.0 months, 95% confidence interval (CI) 1.4-10.7) compared to those in the local/distant group (11.8 months, 95% CI 6.1-17.4). The median  $OS_{Bev}$  of

the infratentorial tumor group and supratentorial tumor group were 9.2 months (95% CI 5.0-13.4) and 10.4 months (95% CI 6.6-14.3), respectively. With multivariate analysis, the prior recurrence pattern was the only independent prognostic factor of OS<sub>Bev</sub>.

Patients with leptomeningeal dissemination of recurrent malignant glioma experienced minimal benefit from bevacizumab. Therefore, in the context of cost effectiveness, bevacizumab is not recommended for patients with leptomeningeal dissemination.

**Keywords:** bevacizumab, efficacy, prior recurrence pattern, tumor location

## **Introduction**

Malignant gliomas are the most common and aggressive type of primary brain tumor, and the prognosis is generally extremely poor. Despite advances in standard therapy, including surgery, radiotherapy, and chemotherapy, recurrence is almost inevitable after a median survival time of 8-9 months[1]. However, current treatment options for patients with recurrent malignant gliomas are limited and are selected on a case-by-case basis due to the absence of established standard therapy. Consequently, survival outcomes for recurrent malignant gliomas are dismal, with a median survival of 25–40 weeks[2-4].

Bevacizumab, a humanized monoclonal antibody that inhibits vascular endothelial growth factor (VEGF), is an antiangiogenic drug used to treat recurrent malignant gliomas. Several phase II studies have demonstrated significant radiographic response rates and improved 6-month progression-free survival in patients with recurrent malignant gliomas who were treated with single-agent bevacizumab[2, 5, 6]. Despite these promising results, many unanswered questions remain to be resolved to achieve an optimal outcome. The most crucial issue is that only a subset of patients who receive

bevacizumab obtain a clinical benefit[7]. To date, despite extensive efforts aimed at biomarker discovery using tumor tissue or blood samples, no predictive biomarkers of survival benefit from bevacizumab for malignant gliomas have been established [7-10].

A few reports investigating the response or survival benefit from bevacizumab have focused on the prior recurrence pattern or tumor location[11-14]. A clinically significant question is whether patients with leptomeningeal dissemination of recurrent malignant gliomas or patients with recurrent malignant gliomas located in the posterior fossa including the brainstem and cerebellum can obtain some clinical benefit from bevacizumab. In this study, we retrospectively analyzed the clinical benefit from bevacizumab for recurrent malignant gliomas regarding the prior recurrence pattern and tumor location.

## Materials and Methods

We investigated 31 consecutive patients with recurrent malignant gliomas who were treated with bevacizumab at the University of Tsukuba Hospital between June 2013 and June 2016. Recurrence was radiologically confirmed according to the response assessment criteria (RANO) for high-grade gliomas[15]. All patients had received radiotherapy and temozolomide, except for one patient with pontine glioma who received radiotherapy and etoposide. All patients received bevacizumab at a dose of 10 mg/kg intravenously every other week. Treatment response to bevacizumab therapy was assessed according to the RANO criteria.

Immunohistochemical analysis of surgical specimens of the original tumors was performed to evaluate VEGF-A, VEGFR-2, and Hypoxia-inducible factor 1 $\alpha$  (HIF-1 $\alpha$ ) protein expression[16]. Briefly, the specimen was fixed in 10% formalin and embedded in paraffin. Histologic sections, 2 mm in thickness, were deparaffinized in xylene and incubated with rabbit polyclonal anti-VEGF-A antibody (A-20, Santa Cruz), rabbit polyclonal anti-VEGFR-2 antibody (Phospho-Tyr1214, Signalway antibody), or mouse monoclonal anti-HIF-1 $\alpha$  antibody (H1alpha67, Novus Biologicals). The DAKO LSAB

2 kit was used to visualize VEGF-A and VEGFR-2, and the DAKO CSA II system was used to visualize HIF-1 $\alpha$ . Expression of VEGF-A, VEGFR-2, and HIF-1 $\alpha$  was determined by semiquantitative assessment of the proportion of positively stained tumor cells. Cases with  $\geq 10\%$  positive cells were rated as positive, whereas cases with  $< 10\%$  positive cells were rated as negative.

Statistical analyses were performed using SPSS software (version 22; SPSS, Inc.).

Overall survival with bevacizumab ( $OS_{Bev}$ ), defined as the time from start of bevacizumab until death, was used to investigate the prognostic value of the analyzed variables. Survival probabilities were calculated using the Kaplan-Meier method, and differences among patient groups were evaluated using the log-rank test. The following prognostic factors were analyzed: age ( $< 60$  years vs.  $\geq 60$  years), sex (male vs. female), Karnofsky performance status (KPS) ( $< 50$  vs.  $\geq 50$ ), prior pathological diagnosis (glioblastoma vs. others), prior recurrence pattern (leptomeningeal dissemination vs. local/distant), primary location of tumor (infratentorial vs. supratentorial), recurrence status (first vs. second/third), VEGF-A expression (negative vs. positive), VEGFR-2 expression (negative vs. positive), and HIF-1 $\alpha$  expression (negative vs. positive).



Factors with a probability value of less than 0.1 on univariate analysis were selected for testing in the multivariate analysis using the Cox proportional hazards model. Results are expressed as relative risk and the 95% confidence interval (CI).

## Results

The baseline characteristics of the 31 patients are shown in Table 1. The mean age of the patients was 52.5 years (range, 6-78). Fifteen patients were males and 16 were females. Of the 31 patients, 22 had glioblastoma, five had anaplastic astrocytoma pathologically diagnosed at the first or second operation prior to bevacizumab therapy, and four had no pathological diagnosis because the tumor was located in the pons or medulla oblongata. primary locations of tumor were supratentorial (n = 23), cerebellum (n = 3), midbrain (n = 1), pons (n = 2), and medulla oblongata (n = 2). Twenty-five of the 31 patients developed local or distant recurrences, whereas six patients recurred with leptomeningeal dissemination. Eighteen patients received bevacizumab therapy primarily as the second line therapy, 10 as the third line, and three as the fourth line. Neither patient had undergone re-resection of recurrent tumor immediately before the administration of bevacizumab. The median KPS was 60 (30-90).

According to the RANO criteria, 19 patients (61.3%) had a partial response, eight (25.8%) had stable disease, and four (12.9%) had progressive disease; the objective response rate was 87.0%. Seven patients were alive at the time of analysis, with a mean

follow-up time of 5.5 (range, 2.4-10.4) months. The median OS<sub>Bev</sub> for all patients was 9.3 months (95% CI, 6.3-12.2). The results of univariate analysis based on the Kaplan-Meier method and the log-rank test are shown in Fig. 1. The prior recurrence pattern was significantly associated with OS<sub>Bev</sub>. The leptomeningeal dissemination group had a significantly shorter median OS<sub>Bev</sub> (6.0 months, 95% CI 1.4-10.7) compared to those with local/distant recurrence (11.8 months, 95% CI 6.1-17.4). The primary location of tumor was not associated with OS<sub>Bev</sub>. The median OS<sub>Bev</sub> of the infratentorial tumor group and supratentorial tumor group were 9.2 months (95% CI 5.0-13.4) and 10.4 months (95% CI 6.6-14.3), respectively. We found no statistically significant difference in OS<sub>Bev</sub> according to recurrence status (second/third vs. first). The median OS<sub>Bev</sub> of the second/third recurrence group and first recurrence group were 10.4 months (95% CI 7.5-13.3) and 9.2 months (95% CI 6.5-11.9), respectively. Univariate and multivariate analyses of the prognostic factors are summarized in Tables 2 and 3, respectively. Univariate analysis of other factors showed that sex, VEGF-A expression, and VEGFR-2 expression were significant factors associated with OS<sub>Bev</sub>.

Multivariate analysis showed that the prior recurrence pattern was the only independent prognostic factor of OS<sub>Bev</sub>.

## Discussion

In the present study, we analyzed the association between multiple factors including the prior recurrence pattern and primary location of tumor, and the clinical benefit from bevacizumab for recurrent malignant gliomas. Leptomeningeal dissemination as a recurrence pattern was significantly associated with poor OS<sub>Bev</sub>. On the other hand, OS<sub>Bev</sub> of the infratentorial tumor group was almost the same as that of the supratentorial tumor group.

Parsa et al. reported that the median survival time from the date of documented dissemination to death of 92 patients with tumor dissemination who were treated without bevacizumab was 23 weeks, which was almost equal to those treated with bevacizumab in the present study[17]. To the best of our knowledge, no clinical studies have investigated the association between the efficacy of bevacizumab therapy and the prior recurrence pattern, particularly regarding leptomeningeal dissemination. Only two case reports have been described. Fiorentino et al. reported a case of recurrent glioblastoma with leptomeningeal and intramedullary dissemination that was treated with bevacizumab and palliative radiotherapy[18]. After six cycles of bevacizumab

administration, progression of the intracranial mass was detected on magnetic resonance imaging, and no improvement was documented. Okita et al. described a case of recurrent glioblastoma with leptomeningeal dissemination that was treated with bevacizumab and temozolomide[13]. Although transient neurological and radiological improvement was observed, progression of the leptomeningeal dissemination occurred, and the patient became bedridden after five cycles of bevacizumab administration. Our results in the present study are consistent with these previous case reports and suggest that bevacizumab does not offer any clinical benefit for patients with recurrent malignant glioma with leptomeningeal dissemination.

Regarding the clinical potential of bevacizumab for infratentorial recurrent malignant gliomas, only limited reports have been published so far. Reithmeier et al. reported a case series of three patients with progressive brainstem gliomas treated with bevacizumab[14]. The authors mentioned improvement in the clinical condition and reduction in amino acid uptake in the tumor area, and thus, they suggested that bevacizumab may represent a therapeutic salvage option for recurrent brainstem gliomas. On the other hand, Gururangan et al. demonstrated only minimal efficacy with

bevacizumab treatment plus CPT-11 in pediatric patients with recurrent brainstem gliomas[11]. Thus, the clinical potential for bevacizumab for recurrent brainstem gliomas remains controversial. Moreover, to the best of our knowledge, no reports have focused on the association between the efficacy of bevacizumab and malignant gliomas located in the cerebellum. In the present study, the objective response rates of the infratentorial tumor group and the supratentorial group were 75.0% and 91.3%, respectively. Likewise, we found no statistically significant difference between OS<sub>Bev</sub> of the infratentorial tumor group and that of the supratentorial group. Because of the difference in tumor characteristics including the pathological diagnosis between the two groups, we cannot conclude that the efficacy of bevacizumab for infratentorial recurrent malignant gliomas is comparable to that for supratentorial recurrent malignant gliomas. However, we showed that some patients in both the infratentorial tumor group and the supratentorial group responded to bevacizumab therapy.

The optimal timing for beginning bevacizumab therapy for recurrent malignant gliomas is a clinically relevant concern. In the present study, no significant difference in OS<sub>Bev</sub> according to the recurrence status (second/third vs. first) was identified. Our

results were consistent with a previous report that focused on the timing for starting bevacizumab therapy (early or later recurrence)[19]. Piccioni et al. demonstrated that survival time after bevacizumab therapy is similar at each recurrence and suggested that efficacy of bevacizumab is fixed whether given early or late. Based on our findings and those of others of the equivalent efficacy of bevacizumab according to recurrence status, the treatment strategy of using bevacizumab as a therapy of last resort may be a preferable option for recurrent malignant gliomas.

Immunohistochemical analysis of angiogenic and hypoxic markers on surgical specimens of the original tumors in the present study only showed a trend toward a positive association between angiogenic markers and prolonged survival but not between hypoxic markers and prolonged survival. Although the expression of VEGF-A and VEGFR-2 was significantly correlated with prolonged OS<sub>Bev</sub> in univariate analysis, this correlation did not reach statistical significance in multivariate analysis. Sathornsumetee et al. reported that high VEGF expression in tumors is correlated with an increased likelihood of a radiographic response to bevacizumab therapy but not increased survival[7]. Similarly, in other studies of solid cancers, only weak and



restricted predictive values of VEGF expression in the primary tumor specimen were reported[20]. Despite the proof-of-concept of antiangiogenic therapy targeting VEGF, expression of angiogenic and hypoxic markers in tumor specimens does not sufficiently predict survival.

In conclusion, we demonstrated that patients with leptomeningeal dissemination of recurrent malignant gliomas experience minimal benefit from bevacizumab. Therefore, in terms of cost effectiveness, bevacizumab is not recommended for patients with leptomeningeal dissemination. We also demonstrated that a subset of patients with recurrent malignant gliomas located in the posterior fossa experienced some clinical benefit from bevacizumab. Further studies with a larger number of patients are needed to validate our current results and to identify the patient populations with infratentorial gliomas as well as supratentorial gliomas who are likely to experience a benefit from bevacizumab.

## **Figure Captions**

### **Fig. 1: The results of univariate analysis based on the Kaplan-Meier method**

A: Kaplan-Meier estimates of overall survival with bevacizumab according to the prior recurrence pattern (dissemination vs. local/distant). B: Kaplan-Meier estimates of overall survival with bevacizumab according to tumor location (infratentorial vs. supratentorial). C: Kaplan-Meier estimates of overall survival with bevacizumab according to recurrence status (second/third vs. first).

## Reference

[1] Hou LC, Veeravagu A, Hsu AR, Tse VC. Recurrent glioblastoma multiforme: a review of natural history and management options. *Neurosurg Focus*. 2006;20:E5.

[2] Kreisl TN, Kim L, Moore K, Duic P, Royce C, Stroud I, et al. Phase II trial of single-agent bevacizumab followed by bevacizumab plus irinotecan at tumor progression in recurrent glioblastoma. *Journal of clinical oncology : official journal of the American Society of Clinical Oncology*. 2009;27:740-5.

[3] Norden AD, Drappatz J, Muzikansky A, David K, Gerard M, McNamara MB, et al. An exploratory survival analysis of anti-angiogenic therapy for recurrent malignant glioma. *Journal of neuro-oncology*. 2009;92:149-55.

[4] Wong ET, Hess KR, Gleason MJ, Jaeckle KA, Kyritsis AP, Prados MD, et al. Outcomes and prognostic factors in recurrent glioma patients enrolled onto phase II clinical trials. *Journal of clinical oncology : official journal of the American Society of Clinical Oncology*. 1999;17:2572-8.

[5] Friedman HS, Prados MD, Wen PY, Mikkelsen T, Schiff D, Abrey LE, et al. Bevacizumab alone and in combination with irinotecan in recurrent glioblastoma.

Journal of clinical oncology : official journal of the American Society of Clinical Oncology. 2009;27:4733-40.

[6] Raizer JJ, Grimm S, Chamberlain MC, Nicholas MK, Chandler JP, Muro K, et al. A phase 2 trial of single-agent bevacizumab given in an every-3-week schedule for patients with recurrent high-grade gliomas. *Cancer*. 2010;116:5297-305.

[7] Sathornsumetee S, Cao Y, Marcello JE, Herndon JE, 2nd, McLendon RE, Desjardins A, et al. Tumor angiogenic and hypoxic profiles predict radiographic response and survival in malignant astrocytoma patients treated with bevacizumab and irinotecan. *Journal of clinical oncology : official journal of the American Society of Clinical Oncology*. 2008;26:271-8.

[8] Chen C, Huang R, MacLean A, Muzikansky A, Mukundan S, Wen PY, et al. Recurrent high-grade glioma treated with bevacizumab: prognostic value of MGMT methylation, EGFR status and pretreatment MRI in determining response and survival. *Journal of neuro-oncology*. 2013;115:267-76.

[9] Hasselbalch B, Eriksen JG, Broholm H, Christensen IJ, Grunnet K, Horsman MR, et al. Prospective evaluation of angiogenic, hypoxic and EGFR-related biomarkers in

recurrent glioblastoma multiforme treated with cetuximab, bevacizumab and irinotecan.

APMIS. 2010;118:585-94.

[10] Lv S, Teugels E, Sadones J, Quartier E, Huylebrouck M, S DUF, et al. Correlation between IDH1 gene mutation status and survival of patients treated for recurrent glioma.

Anticancer research. 2011;31:4457-63.

[11] Gururangan S, Chi SN, Young Poussaint T, Onar-Thomas A, Gilbertson RJ, Vajapeyam S, et al. Lack of efficacy of bevacizumab plus irinotecan in children with recurrent malignant glioma and diffuse brainstem glioma: a Pediatric Brain Tumor Consortium study. Journal of clinical oncology : official journal of the American Society of Clinical Oncology. 2010;28:3069-75.

[12] Kaloshi G, Roji A, Seferi A, Cakani B, Bushati T, Roci E, et al. Spinal Dissemination of Intracranial Glioblastoma in Bevacizumab Era: a Potential Bevacizumab-induced Mechanism. Acta Inform Med. 2014;22:142-4.

[13] Okita Y, Nonaka M, Umehara T, Kanemura Y, Kodama Y, Mano M, et al. Efficacy of temozolomide and bevacizumab for the treatment of leptomeningeal dissemination of recurrent glioblastoma: A case report. Oncol Lett. 2015;9:1885-8.

- [14] Reithmeier T, Lopez WO, Spehl TS, Nguyen T, Mader I, Nikkhah G, et al. Bevacizumab as salvage therapy for progressive brain stem gliomas. *Clin Neurol Neurosurg.* 2013;115:165-9.
- [15] Wen PY, Macdonald DR, Reardon DA, Cloughesy TF, Sorensen AG, Galanis E, et al. Updated response assessment criteria for high-grade gliomas: response assessment in neuro-oncology working group. *Journal of clinical oncology : official journal of the American Society of Clinical Oncology.* 2010;28:1963-72.
- [16] Mashiko R, Takano S, Ishikawa E, Yamamoto T, Nakai K, Matsumura A. Hypoxia-inducible factor 1alpha expression is a prognostic biomarker in patients with astrocytic tumors associated with necrosis on MR image. *Journal of neuro-oncology.* 2011;102:43-50.
- [17] Parsa AT, Wachhorst S, Lamborn KR, Prados MD, McDermott MW, Berger MS, et al. Prognostic significance of intracranial dissemination of glioblastoma multiforme in adults. *Journal of neurosurgery.* 2005;102:622-8.
- [18] Fiorentino A, Caivano R, Chiumento C, Cozzolino M, Fusco V. Radiotherapy and bevacizumab for intramedullary and leptomeningeal metastatic glioblastoma: a case

report and review of the literature. *Int J Neurosci.* 2012;122:691-4.

[19] Piccioni DE, Selfridge J, Mody RR, Chowdhury R, Li S, Lalezari S, et al. Deferred use of bevacizumab for recurrent glioblastoma is not associated with diminished efficacy. *Neuro-oncology.* 2014;16:815-22.

[20] Jubb AM, Harris AL. Biomarkers to predict the clinical efficacy of bevacizumab in cancer. *Lancet Oncol.* 2010;11:1172-83.

**Table 1**  
**Patient Characteristics**

Characteristics	No. of patients	%
Age (yrs)		
Mean $\pm$ SD	52.5 $\pm$ 19.1	
Range	6-78	
Gender		
Male	15	48.4
Female	16	51.6
Prior pathological diagnosis		
glioblastoma	22	71.0
anaplastic astrocytoma	5	16.1
N.A (pons, medulla)	4	12.9
Primary Location of tumor		
supratentorial	23	74.2
infratentorial	8	25.8
Recurrence pattern		
Local/Distant	25	80.6
Dissemination	6	19.4
Recurrence status		
First	18	58.1
Second	10	32.2
Third	3	9.7
KPS		
90	2	6.5
80	2	6.5
70	3	9.7
60	12	38.7
50	8	25.8
40	2	6.5
30	2	6.5

SD: standard deviation, KPS: Karnofsky performance status



**Table 2**  
**Univariate analysis**

Variable	Hazard ratio (96% CI)	p Value
Age ( <60 yrs vs. ≥60 yrs)	2.271 (0.872-5.913)	0.093
Gender (male vs. female)	2.833 (1.072-7.484)	0.036
Prior pathological diagnosis (glioblastoma vs. others)	1.126 (0.429-2.959)	0.810
Recurrence pattern (dissemination vs. local/distant)	48.162 (5.402-429.366)	0.001
Primary Location of tumor (infratentorial vs. supratentorial)	1.229 (0.449-3.364)	0.688
Recurrence status (first vs. second/third)	1.138 (0.496-2.611)	0.760
Karnofsky performance status ( <50 vs. ≥50)	1.420 (0.412-4.894)	0.578
VEGF-A (negative vs. positive)	4.477 (1.366-14.670)	0.013
VEGFR-2 (negative vs. positive)	4.031 (1.180-13.764)	0.026
HIF-1α (negative vs. positive)	1.822 (0.223-14.899)	0.576

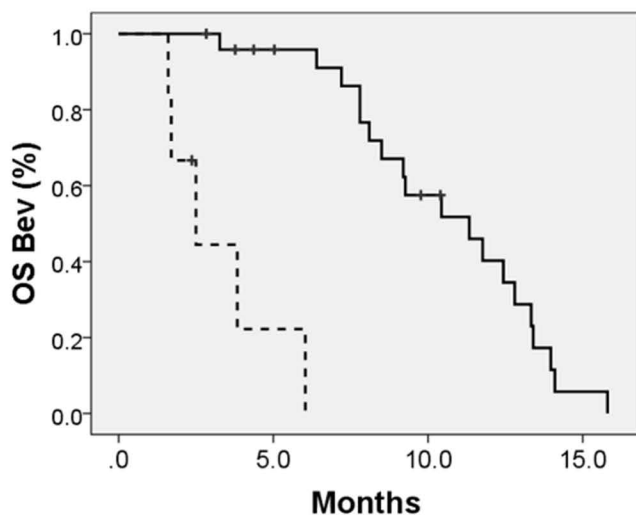
**Table 3**  
**Multivariate analysis**

Variable	Hazard ratio (96% CI)	p Value
Age ( <60 yrs vs. ≥60 yrs)	1.113 (0.224-5.538)	0.896
Gender (male vs. female)	1.113 (0.245-5.064)	0.889
Recurrence pattern (dissemination vs. local/distant)	24.637 (1.873-324.047)	0.015
VEGF-A (negative vs. positive)	3.855 (0.874-16.997)	0.075
VEGFR-2 (negative vs. positive)	2.193 (0.367-13.109)	0.389

Fig.1

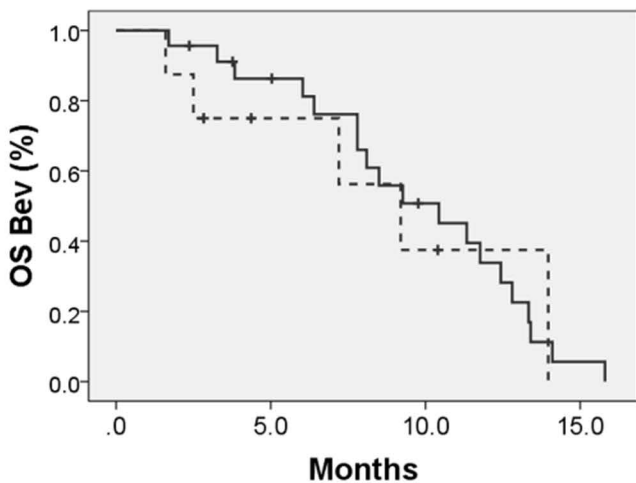
a

### Prior recurrence pattern



b

### Tumor location



c

### Recurrence status

