

Prevalence and distribution of ossification of the supra/interspinous ligaments in symptomatic patients with cervical ossification of the posterior longitudinal ligament of the spine: a CT-based multicenter cross-sectional study

著者別名	山崎 正志
journal or publication title	BMC musculoskeletal disorders
volume	17
page range	492
year	2016-12
権利	(C) The Author(s). 2016 Open Access This article is distributed under the terms of the Creative Commons Attribution 4.0 International License (http://creativecommons.org/licenses/by/4.0/), which permits unrestricted use, distribution, and reproduction in any medium, provided you give appropriate credit to the original author(s) and the source, provide a link to the Creative Commons license, and indicate if changes were made. The Creative Commons Public Domain Dedication waiver (http://creativecommons.org/publicdomain/zero/1.0/) applies to the data made available in this article, unless otherwise stated.
URL	http://hdl.handle.net/2241/00145808

doi: 10.1186/s12891-016-1350-y

RESEARCH ARTICLE

Open Access



Prevalence and distribution of ossification of the supra/interspinous ligaments in symptomatic patients with cervical ossification of the posterior longitudinal ligament of the spine: a CT-based multicenter cross-sectional study

Kanji Mori^{1,22*}, Toshitaka Yoshii^{2,22}, Takashi Hirai^{2,22}, Akio Iwanami^{3,22}, Kazuhiro Takeuchi^{4,22}, Tsuyoshi Yamada^{2,22}, Shoji Seki^{5,22}, Takashi Tsuji^{6,22}, Kanehiro Fujiyoshi^{7,22}, Mitsuru Furukawa^{8,22}, Soraya Nishimura^{3,8,22}, Kanichiro Wada^{9,22}, Masao Koda^{10,22}, Takeo Furuya^{10,22}, Yukihiro Matsuyama^{11,22}, Tomohiko Hasegawa^{11,22}, Katsushi Takeshita^{12,22}, Atsushi Kimura^{12,22}, Masahiko Abematsu^{13,22}, Hirotaka Haro^{14,22}, Tetsuro Ohba^{14,22}, Masahiko Watanabe^{15,22}, Hiroyuki Katoh^{15,22}, Kei Watanabe^{16,22}, Hiroshi Ozawa^{17,22}, Haruo Kanno^{18,22}, Shiro Imagama^{19,22}, Zenya Ito^{19,22}, Shunsuke Fujibayashi^{20,22}, Masashi Yamazaki^{21,22}, Morio Matsumoto^{3,22}, Masaya Nakamura^{3,22}, Atsushi Okawa^{2,22} and Yoshiharu Kawaguchi^{5,22}

Abstract

Background: Supra/interspinous ligaments connect adjacent spinous processes and act as a stabilizer of the spine. As with other spinal ligaments, it can become ossified. However, few reports have discussed ossification of supra/interspinous ligaments (OSIL), so its epidemiology remains unknown. We therefore aimed to investigate the prevalence and distribution of OSIL in symptomatic patients with cervical ossification of the posterior longitudinal ligament (OPLL).

Methods: The participants of our study were symptomatic patients with cervical OPLL who were diagnosed by standard radiographs of the cervical spine. The whole spine CT data as well as clinical parameters such as age and sex were obtained from 20 institutions belonging to the Japanese Multicenter Research Organization for Ossification of the Spinal Ligament (JOSL). The prevalence and distribution of OSIL and the association between OSIL and clinical parameters were reviewed. The sum of the levels involved by OPLL (OP-index) and OSIL (OSI-index) as well as the prevalence of ossification of the nuchal ligament (ONL) were also investigated.

(Continued on next page)

* Correspondence: kanchi@belle.shiga-med.ac.jp

¹Department of Orthopaedic Surgery, Shiga University of Medical Science, Tsukinowa-cho, Seta, Otsu, Shiga 520-2192, Japan

²²Japanese organization of the Study for Ossification of Spinal Ligament (JOSL), Otsu, Japan

Full list of author information is available at the end of the article



(Continued from previous page)

Results: A total of 234 patients with a mean age of 65 years was recruited. The CT-based evidence of OSIL was noted in 68 (54 males and 14 females) patients (29%). The distribution of OSIL showed a significant thoracic preponderance. In OSIL-positive patients, single-level involvement was noted in 19 cases (28%), whereas 49 cases (72%) presented multi-level involvement. We found a significant positive correlation between the OP-index grade and OSI-index. ONL was noted at a significantly higher rate in OSIL-positive patients compared to negative patients.

Conclusions: The prevalence of OSIL in symptomatic patients with cervical OPLL was 29%. The distribution of OSIL showed a significant thoracic preponderance.

Keywords: Supra/interspinous ligaments, Ossification, Ankylosed spine, Computed tomography, OPLL, OLF, DISH, Whole spine, Prevalence, Epidemiology

Background

The ossification of the posterior longitudinal ligament (OPLL) and ossification of the ligamentum flavum (OLF) are characterized by the replacement of the posterior longitudinal ligament and ligamentum flavum by ectopic new bone formation, respectively [1, 2]. The most frequent OPLL [3] and OLF [2] lesions are the cervical spine and the thoracic spine, respectively. OPLL often causes a narrow spinal canal and has been recognized as one of the causes of cervical myelopathy and/or radiculopathy [1, 3]. OLF is also well known as one of the causes of thoracic myelopathy through the compression of the spinal cord from the posterolateral side [2]. Some cases with ossification of the anterior longitudinal ligament (OALL) have been reported. Although OALL is not directly involved in the spinal canal, the longitudinal spread of OALL is known as diffuse idiopathic skeletal hyperostosis (DISH), which was reported by Resnick [4]. To date, DISH is a poorly understood systemic disease characterized by not only progressive OALL but also peripheral entheses [4, 5]. Ankylosed spine due to DISH yields biomechanical changes of the spinal system and acts as long bones, which can develop several manifestations peculiar to DISH [5–9]. Therefore, many clinicians pay attention to DISH in recent practice [5]. Theoretically, the continuous multi-level ossification of supra/interspinous ligaments (OSIL) may also cause the biomechanical changes of the spinal system and development of several manifestations similar to DISH. However, to date, few reports have discussed about OSIL. Although previous reports suggested that there is a pathophysiological association between DISH and ossification of other spinal ligaments such as OPLL [10, 11]. However, the characteristics in patients with OSIL are unknown. Thus, a multicenter study based on whole spine computed tomography (CT) data of symptomatic patients with cervical OPLL was conducted. The purpose of our study was to elucidate the prevalence and distribution of OSIL in symptomatic patients with cervical OPLL. We further investigated the association between OSIL and OPLL and ossification of the nuchal ligament (ONL) [12].

Methods

Our study was conducted by Japanese Multicenter Research Organization for Ossification of the Spinal Ligament (JOSL), a specially commission instituted by the Japanese Ministry of Health, Labor and Welfare Health study. Written informed consent was obtained from each participant before registration at each institution. The local ethics committee of each institute approved this study.

Participants

The participants of our study were symptomatic patients with cervical OPLL who were diagnosed by standard radiographs of the cervical spine. The definitive diagnosis of cervical OPLL on standard radiographs was determined as an ossification thicker than at least 3 mm within the posterior longitudinal ligament of the spine. If the OPLL was responsible for symptoms such as myelopathy, the cases with single level OPLL were also included. All standard radiographs were evaluated by an experienced spine surgeon at each participating institute. All enrolled patients had undertaken subsequent whole spine CT examination. The presence of OPLL in all eligible cases by standard radiograph was confirmed by subsequent CT. CT data as well as clinical parameters such as age, sex, presence of diabetes mellitus (DM) and body mass index (BMI) were obtained from 20 institutions belong to the JOSL. Patients who had a past history of anterior spinal decompression surgery for the treatment of OPLL and who were younger than 15 years were excluded from our study.

We calculated an adequate sample size in comparison of the OSIL-indexes among the 3 groups based on the OP-indexes. Because the OSIL-index was unknown before we conducted this study, we used a standard effect size: 0.25 in the power analysis for multiple comparisons. Then, we determined the minimum sample size to be 230 ($\alpha = 0.05$, $\beta = 0.9$), considering the possibility of obtaining invalid data in 10% of the samples. Accordingly, a total of 234 patients (57 females and 177 males)

with a mean age of 65 years (range, 33–93 years) were included in the analysis.

Radiologic examination

All CT data were evaluated by five experienced spine surgeons (KM, TH, KT, AI and TY). Differences were settled by consensus to minimize intra- and inter-observer bias and errors. Before evaluation, the average Kappa coefficient of inter- and intra-observer agreement was determined by reviewing the same CT data of the 20 patients.

As there are no universally-approved criteria for OSIL; we counted the OSIL completely bridging adjacent spinous processes in our study. OSIL completely bridging at least four contiguous spinous processes were determined to be diffuse OSIL (DOSIL) according to the DISH criteria established by Resnick and Niwayama [4].

In addition, consistent with a previous report [13], the ossification index (OS-index) was determined. The OS-index is defined as the total number of vertebral body and intervertebral disc levels involved by ossification of the ligament. Therefore, the OS-indexes for OPLL and OSIL were represented as the OP-index and OSI-index, respectively. We subdivided the patients into three subgroups according to the cervical OP-index, which is consistent with a previous report [14]: Grade 1: patients with a cervical OP-index of 5 or less; Grade 2: patients with a cervical OP-index of 6–9; and Grade 3: patients with a cervical OP-index of 10 or more. The presence of ONL was also evaluated.

Statistical analysis

Student's unpaired *t*-test, chi-square test, Tukey post hoc test and Pearson's product moment correlation coefficient were used when appropriate. $P < 0.05$ was considered statistically significant. The software application used for the analysis was SPSS for Windows version 22.0 (SPSS Institute, Chicago, IL).

Results

The average Kappa coefficient of inter-observer agreement by reviewing the same images of 20 patients for OPLL, OSIL and ONL were 0.76, 0.79 and 1.0, respectively. The intra-observer agreement for OPLL, OSIL and ONL were 0.94, 0.94 and 1.0, respectively.

Among 234 symptomatic patients with cervical OPLL, OSIL was noted in 68 patients (29%) (54 males and 14 females). The mean age of OSIL-positive patients was significantly higher than that of negative patients (OSIL-positive: 70 years vs. OSIL-negative: 63 years, $p < 0.01$, Table 1). Figure 1 shows the distribution of OSIL in the thoracolumbar region. OSIL were noted for 278 interspinous levels. OSIL were noted at a higher rate in the thoracic region (260 interspinous levels) than in the lumbar region (18 interspinous levels). In OSIL-positive patients, single-level involvement was noted in 19 cases (28%), whereas 49 cases (72%) presented multi-level involvement. Among those with multi-level involvements, the highest number of involved level with OSIL reached 15 levels. These findings are shown in Fig. 2. The number of cases with multi-level involvements was small; we subdivided OSIL-positive patients into 2 subgroups according to DISH criteria [3]: DOSIL and non DOSIL for our analyses. DOSIL consists of 40% out of total OSIL cases (68).

The mean OP-index in OSIL-positive patients was significantly higher than that of OSIL-negative patients: 2.2 and 1.7 for the OSIL-positive and negative patients, respectively ($p < 0.01$, Table 1). The same trend was found between DOSIL-positive and negative patients ($p < 0.01$, Table 1). We further investigated OSI-index according to the OP-index grade and also found a positive correlation between OP-index grade and OSI-index ($p < 0.01$, $r = 0.32$, Fig. 3). We found a significant difference in the OSI-index among the three OP-index grades ($p < 0.01$).

ONL were found in 46 out of 68 OSIL-positive patients (68%) and 21 out of 27 DOSIL-positive patients (78%). ONL were noted at a significantly higher rate in both OSIL-positive ($p = 0.021$) and DOSIL-positive

Table 1 Characterization of the participants

	OSIL (+)	OSIL (-)	<i>p</i> -value	DOSIL (+)	DOSIL (-)	<i>p</i> -value
Sex (M/F)	54/14	123/43	0.39	21/6	156/51	0.78
Age (yr)	70 ± 9.7	63 ± 9.7	<0.01	71 ± 9.1	65 ± 11	<0.01
BMI (kg/m ²)	25 ± 4.8	26 ± 4.8	0.55	26 ± 6.5	25 ± 4.6	0.83
DM (+) n (%)	21 (31)	50 (30)	0.91	11 (41)	60 (29)	0.21
OP-index	2.2 ± 0.73	1.7 ± 0.70	<0.01	2.3 ± 0.68	1.7 ± 0.74	<0.01
ONL (+) n (%)	46 (68)	85 (51)	0.021	21 (78)	110 (53)	0.015

OSIL ossification of supra/inter spinous ligaments, DOSIL diffuse OSIL, M male, F female, BMI body mass index, DM (+): presence of diabetes mellitus, OP-index: ossification index for ossification of the posterior longitudinal ligament of the spine, ONL (+): presence of ossification of the nuchal ligament
Age, BMI and OP-index were represented by mean ± standard deviation

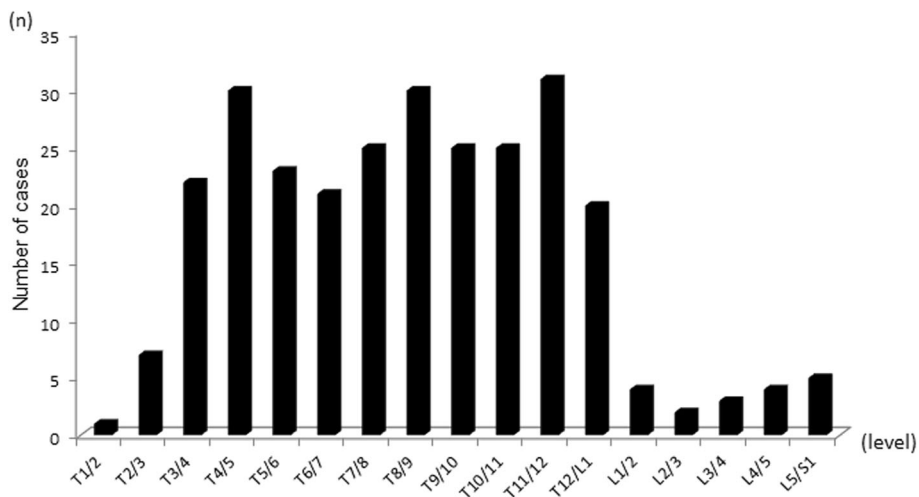


Fig. 1 Distribution of OSIL in the thoracolumbar region of 234 symptomatic patients with cervical OPLL

patients ($p = 0.015$) compared to those of negative patients (Table 1).

We evaluated the association between sex, BMI and presence of DM and OSIL status, and no significant difference was found (Table 1).

Discussion

To date, our study is the largest multicenter study to investigate whole spine CT images in symptomatic patients with cervical OPLL, including disclosing the CT-based prevalence and distribution of OSIL. The results of the average Kappa coefficient of inter- and intra-observer agreement by reviewing the same images of 20 patients

indicated an excellent and substantial agreement [15]. We believe that the present data were reliable.

The supraspinous ligament connects the tips of the spinous processes from the 7th cervical vertebra to the sacrum [16]. The interspinous ligaments are thin and membranous ligaments that connect adjacent spinous processes of the vertebra in the spine [16]. These ligaments act as a stabilizer of the spine [16]. The thoracic spine has a limited range of motion due to its characteristic anatomy compared to that of the cervical and lumbar spine. The reason for a predominantly thoracic distribution of OSIL remains unknown; however it is likely that the spinal range of motion may have some impact on the distribution of OSIL.

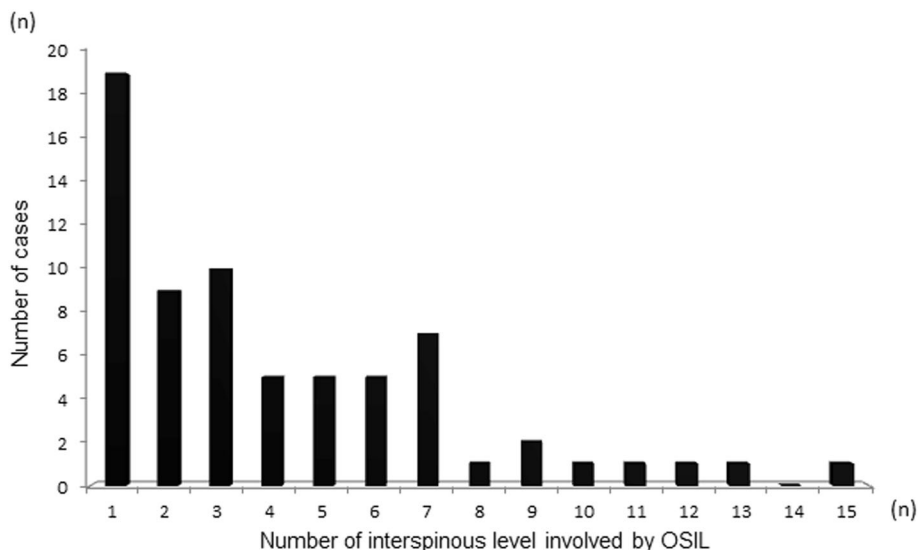


Fig. 2 Distribution of the patients with OSIL according to the number of involved interspinous levels

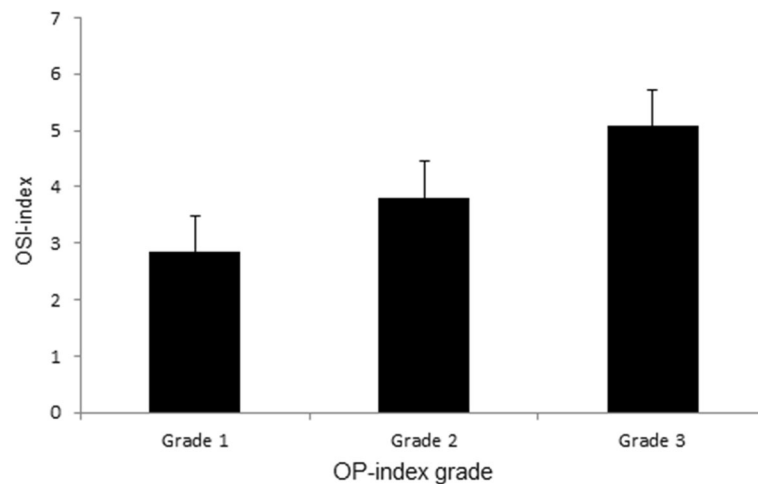


Fig. 3 Sum of the levels involved by OSIL (OSI-index) according to the sum of the levels involved by OPLL (OP-index) grade

Accumulating results show that a consecutively ankylosed spine due to DISH yields biomechanical changes in the spinal system and develops several characteristic manifestations including spinal fractures resembling those of long bone [5–9]. It can also develop a significant displacement of the fracture site even though it was no or minimal displacement after a relatively minor trauma [5], which may cause both patients' and/or doctors' delay [6–9]. Fractures in patients with ankylosed spine often resulted from minor trauma such as falls from a standing/sitting level, which can cause an underestimation of injury severity by both patients and doctors [8, 9]. In addition, pre-existing pathologic changes of the spine prevent correct diagnosis. Consequently, some patients experience a sudden neurological deterioration [8, 9]. Secondary neurological deterioration may also occur by inadequate immobilization, careless transfers or imprudent manipulation of these patients [8, 9]. Moreover, the patients with an ankylosed spine can develop several complications such as aspiration pneumonia, kyphotic deformity, myelopathy, and unexpected hyperextension fracture-dislocation of the thoracic spine with paraplegia by position during retroperitoneal surgery [17–19]. A systematic review of the literature revealed that the complication rate and overall mortality within 3 months after injury in DISH patients were 32.7% and 20.0%, respectively [9]. These findings suggested that we must pay attention to the presence of ankylosed spine for the spine care [5, 8, 9].

Consecutively ankylosed spine by means of OSIL completely bridging adjacent spinous processes may cause biomechanical changes of the spinal system, which is similar to DISH. Nevertheless, to the best of our knowledge, OSIL have received less attention to date. The reason remains unknown; however it is likely that OSIL does not directly develop the neurological compromise

that is observed in OPLL and OLF. In addition, in contrast with DISH, diagnosis of OSIL by standard radiographs is difficult.

The nuchal ligament is the equivalent structure of the supraspinous ligament in the cervical spine [16]. As a localized ossification, ONL were noted to be significantly more frequent in OSIL/DOSIL-positive patients compared to those of negative patients. The ONL-positive rate was higher in DOSIL-positive patients than in OSIL-positive patients. In addition, the same trend was found between the severity of the OSIL and OP-index (Table 1). Furthermore, interpreted from a cervical OPLL viewpoint, we found a positive correlation between the cervical OP-index grade and the OSI-index (Fig. 3). Thus, these findings suggested a positive association between OSIL and OPLL, and it is possible that we can use the cervical OP-index grade as an indicator of ossification of the general spinal ligaments.

Alternatively, no significant difference was found between sex, BMI and presence of DM and OSIL/DOSIL status. These findings may be attributed to the character of the participants in our study. That is, the participants in our study were exclusively patients with cervical OPLL, which are significantly predominant in males with high BMI and DM involvement [3]. This background can mask the association between these factors and OSIL/DOSIL status.

Our study has several limitations. First, our study is not a population-based study, and thus true prevalence and distribution of OSIL cannot be determined. Our findings are those of symptomatic cervical OPLL patients only and cannot be generalized to the general population. Although CT allows more precise evaluation of the ossification of spinal ligaments compared to radiography [20, 21], much higher radiation dose of CT makes it ethically impossible to perform an observational

epidemiological population study using CT scan. In addition, we [13, 20, 21] and others [22] have reported that patients with symptomatic cervical OPLL frequently had tandem ossifications at the thoracolumbar region, which sometimes required additional surgeries. It is therefore important to evaluate the whole spine so as not to overlook the latent risk of tandem ossifications in the thoracolumbar region when we treat patients with cervical OPLL [13, 20–22]. As another limitation, it is possible that cases with small cervical OPLL were neglected. All eligible cases by standard radiographs were OPLL positive by subsequent CT scan; we therefore believe that there were no false-positive cases. Another limitation is that, due to the nature of retrospective studies, we cannot evaluate whether clinical manifestations such as stiffness, impaired mobility, symptomatic duration and other co-morbidity like medications are significantly associated with OSIL. Furthermore, the real impact of biomechanical changes to the spinal system due to OSIL on clinical manifestations remains unknown and should be determined in future studies. Despite these limitations, one favorable aspect of our study is that it is the largest multicenter study to investigate whole spine CT images in symptomatic patients with cervical OPLL and is the first to elucidate the prevalence and distribution of OSIL.

Conclusions

The CT-based prevalence of OSIL in symptomatic patients with cervical OPLL was 29%, and its distribution showed a significant thoracic preponderance. Among OSIL-positive patients, 40% were classified as DOSIL. Awareness of the presence of consecutively ankylosed spine may be very important for the spine care.

Abbreviations

BMI: Body mass index; CT: Computed tomography; DISH: Diffuse idiopathic skeletal hyperostosis; DM: Diabetes mellitus; DOSIL: Diffuse ossification of supra/interspinous ligaments; JOSL: Japanese Multicenter Research Organization for Ossification of the Spinal Ligament; OALL: Ossification of the anterior longitudinal ligament; OLF: Ossification of the ligamentum flavum; ONL: Ossification of the nuchal ligament; OP-index: OS-index for OPLL; OPLL: Ossification of the posterior longitudinal ligament; OSI-index: OS-index for OSIL; OSIL: Ossification of supra/interspinous ligaments; OS-index: Ossification index

Acknowledgements

Not applicable.

Funding

This work was supported by Health and Labour Science Research Grants. No other financial associations that may be relevant or seen as relevant to the submitted manuscript.

Availability of data and material

The data and materials in current paper may be made available upon request through sending e-mail to first author.

Authors' contributions

KM, TY, MM, MN, AO and YK designed the study; KM, TY, TH, AI, KT, TY, SS, TT, KF, MF, SN, KW, MK, TF, YM, TH, KT, AK, MA, HH, TO, MW, HK, KW, HO, HK, SI, ZI, SF, MY, MM, MN, and YK collected the data; KM, TY, TH, AI and KT

analyzed and interpreted the data; KM and YK wrote the initial draft; KM and TH performed statistical analyses. KM, TY, TH, AI, KT, TY, SS, TT, KF, MF, SN, KW, MK, TF, YM, TH, KT, AK, MA, HH, TO, MW, HK, KW, HO, HK, SI, ZI, SF, MY, MM, MN, AO and YK participated in revising the manuscript. MM, MN, AO and YK supervise the study; MM and AO participated in acquisition of funding. All authors read and approved the final manuscript.

Competing interests

The authors declare that they have no competing interests.

Consent for publication

Not applicable.

Ethics approval and consent to participate

Written informed consent was obtained from each participant before registration at each institution. The local ethics committee of each institute approved this study, i.e., ethics committee of Shiga University of Medical Science, ethics committee of Tokyo Medical and Dental University, ethics committee of Keio University, ethics committee of National Hospital Organization Okayama Medical Center, ethics committee of University of Toyama, ethics committee of Kitasato Institute Hospital, ethics committee of National Hospital Organization Murayama Medical Center, ethics committee of Hirosaki University Graduate School of Medicine, ethics committee of Chiba University Graduate School of Medicine, ethics committee of Hamamatsu University School of Medicine, ethics committee of Jichi Medical University, ethics committee of Kagoshima University, ethics committee of University of Yamanashi, ethics committee of Tokai University School of Medicine, ethics committee of Niigata University Medicine and Dental General Hospital, ethics committee of Tohoku Medical and Pharmaceutical University, ethics committee of Tohoku University School of Medicine, ethics committee of Nagoya University Graduate School of Medicine, ethics committee of Kyoto University, ethics committee of University of Tsukuba.

Author details

¹Department of Orthopaedic Surgery, Shiga University of Medical Science, Tsukinowa-cho, Seta, Otsu, Shiga 520-2192, Japan. ²Department of Orthopedic Surgery, Tokyo Medical and Dental University, 1-5-45 Yushima, Bunkyo-Ku, Tokyo 113-8519, Japan. ³Department of Orthopedic Surgery, School of Medicine, Keio University, 35 Shinanomachi, Shinjuku-Ku, Tokyo 160-8582, Japan. ⁴Department of Orthopedic Surgery, National Hospital Organization Okayama Medical Center, 1711-1 Tamasu, Okayama 701-1154, Japan. ⁵Department of Orthopedic Surgery, Faculty of Medicine, University of Toyama, 2630 Sugitani, Toyama 930-0194, Japan. ⁶Department of Orthopedic Surgery, Kitasato Institute Hospital, 5-9-1, Shirokane, Minato-ku, Tokyo 108-8642, Japan. ⁷Department of Orthopedic Surgery, National Hospital Organization Murayama Medical Center, 2-37-1, Gakuen, Musashimurayama, Tokyo 208-0011, Japan. ⁸Department of Orthopedic Surgery, Keiyu Hospital, 3-7-3, Minatomirai, Nishi-Ku, Yokohama, Kanagawa 220-8521, Japan. ⁹Department of Orthopedic Surgery, Hirosaki University Graduate School of Medicine, 53 Honcho, Hirosaki, Aomori 036-8203, Japan. ¹⁰Department of Orthopedic Surgery, Chiba University Graduate School of Medicine, 1-8-1 Inohana, Chuo Ward, Chiba 260-0856, Japan. ¹¹Department of Orthopedic Surgery, Hamamatsu University School of Medicine, 1-20-1 Handayama, Hamamatsu, Shizuoka 431-3125, Japan. ¹²Department of Orthopedics, Jichi Medical University, 3311-1 Yakushiji, Shimotsuke, Tochigi 329-0498, Japan. ¹³Department of Orthopedic Surgery, Graduate School of Medicine and Dental Science, Kagoshima University, 8-35-1 Sakuragaoka, Kagoshima 890-8520, Japan. ¹⁴Department of Orthopedic Surgery, University of Yamanashi, 1110 Shimokato, Chuo Ward, Yamanashi 409-3898, Japan. ¹⁵Department of Orthopedic Surgery, Surgical Science, Tokai University School of Medicine, 143 Shimokasuya, Isehara, Kanagawa 259-1143, Japan. ¹⁶Department of Orthopedic Surgery, Niigata University Medicine and Dental General Hospital, 1-754 Asahimachidori, Chuo Ward, Niigata 951-8520, Japan. ¹⁷Department of Orthopaedic Surgery, Tohoku Medical and Pharmaceutical University, 1-12-1 Fukumuro Miyaginoku, Sendai 983-8512, Japan. ¹⁸Department of Orthopaedic Surgery, Tohoku University School of Medicine, 1-1 Seiryomachi, Aoba Ward, Sendai, Miyagi 980-8574, Japan. ¹⁹Department of Orthopedic Surgery, Nagoya University Graduate School of Medicine, 65 Tsurumaicho, Showa Ward, Nagoya, Aichi 466-0065, Japan. ²⁰Department of Orthopedic Surgery, Graduate School of Medicine, Kyoto University, 54 Kawaharacho, Shogoin, Sakyo-ku, Kyoto 606-8507, Japan. ²¹Department of

Orthopedic Surgery, Faculty of Medicine, University of Tsukuba, 2-1-1 Amakubo, Tsukuba, Ibaraki 305–8576, Japan. ²²Japanese organization of the Study for Ossification of Spinal Ligament (JOSL), Otsu, Japan.

Received: 14 September 2016 Accepted: 23 November 2016
Published online: 01 December 2016

References

- Tsukimoto H. A care-report autopsy of syndrome of compression of spinal cord owing to ossification within spinal canal of cervical spines. *Arch Jap Chir.* 1960;29:1003–7.
- Miyasaka K, Kaneda K, Sato S, et al. Myelopathy due to ossification or calcification of the ligamentum flavum: radiologic and histologic evaluations. *AJNR Am J Neuroradiol.* 1983;4(3):629–32.
- Matsunaga S, Sakou T. Epidemiology of ossification of the posterior longitudinal ligament. In: Yonenobu K, Sakou T, Ono K, editors. *OPLL, Ossification of the longitudinal ligament.* Tokyo: Springer; 1997. p. 3–17.
- Resnick D, Niwayama G. Radiographic and pathologic features of spinal involvement in diffuse idiopathic skeletal hyperostosis (DISH). *Radiology.* 1976;119(3):559–68.
- Mader R, Verlaan JJ, Buskila D. Diffuse idiopathic skeletal hyperostosis: clinical features and pathogenic mechanisms. *Nat Rev Rheumatol.* 2013; 9(12):741–50.
- Liu P, Yao Y, Liu MY, et al. Spinal trauma in mainland China from 2001 to 2007: an epidemiological study based on a nationwide database. *Spine (Phila Pa 1976).* 2012;37(15):1310–5.
- Caron T, Bransford R, Nguyen Q, et al. Spine fractures in patients with ankylosing spinal disorders. *Spine (Phila Pa 1976).* 2010;35(11):E458–64.
- Westerveld LA, van Bommel JC, Dhert WJ, et al. Clinical outcome after traumatic spinal fractures in patients with ankylosing spinal disorders compared with control patients. *Spine J.* 2014;14(5):729–40.
- Westerveld LA, Verlaan JJ, Oner FC. Spinal fractures in patients with ankylosing spinal disorders: a systematic review of the literature on treatment, neurological status and complications. *Eur Spine J.* 2009;18(2):145–56.
- Resnick D, Guerra Jr J, Robinson CA, et al. Association of diffuse idiopathic skeletal hyperostosis (DISH) and calcification and ossification of the posterior longitudinal ligament. *AJR Am J Roentgenol.* 1978;131(6):1049–53.
- McAfee PC, Regan JJ, Bohlman HH. Cervical cord compression from ossification of the posterior longitudinal ligament in non-orientals. *J Bone Joint Surg (Br).* 1987;69(4):569–75.
- Barsony T. Kalkschatten im Bereiche der Nackenweichteile. *Fortschr Rontgenstr.* 1929;40:809–12.
- Kawaguchi Y, Nakano M, Yasuda T, et al. Ossification of the posterior longitudinal ligament in not only the cervical spine, but also other spinal regions: analysis using multidetector computed tomography of the whole spine. *Spine (Phila Pa 1976).* 2013;38(23):E1477–82.
- Hirai T, Yoshii T, Iwanami A, Takeuchi K, Mori K, Yamada T, Wada K, Koda M, Matsuyama Y, Takeshita K, Abematsu M, Haro H, Watanabe M, Watanabe K, Ozawa H, Kanno H, Imagama S, Fujibayashi S, Yamazaki M, Matsumoto M, Nakamura M, Okawa A, Kawaguchi Y. Prevalence and Distribution of Ossified Lesions in the Whole Spine of Patients with Cervical Ossification of the Posterior Longitudinal Ligament A Multicenter Study (JOSL CT study). *PLoS ONE.* 2016;11(8):e0160117.
- Karanicolas PJ, Bhandari M, Kreder H, et al. Evaluating agreement: conducting a reliability study. *J Bone Joint Surg Am.* 2009;91 Suppl 3:99–106.
- Aspden RM, Bornstein NH, Hukins DW. Collagen organisation in the interspinous ligament and its relationship to tissue function. *J Anat.* 1987; 155:141–51.
- Mody GM, Charles RW, Ranchod HA, et al. Cervical spine fracture in diffuse idiopathic skeletal hyperostosis. *J Rheumatol.* 1988;15(1):129–31.
- Laroche M, Moulinier L, Arlet J, et al. Lumbar and cervical stenosis. Frequency of the association, role of the ankylosing hyperostosis. *Clin Rheumatol.* 1992;11(4):533–5.
- Israel Z, Mosheiff R, Gross E, et al. Hyperextension fracture-dislocation of the thoracic spine with paraplegia in a patient with diffuse idiopathic skeletal hyperostosis. *J Spinal Disord.* 1994;7(5):455–7.
- Mori K, Kasahara T, Mimura T, et al. Prevalence, distribution, and morphology of thoracic ossification of the yellow ligament in Japanese: results of CT-based cross-sectional study. *Spine (Phila Pa 1976).* 2013;38(19): E1216–22.
- Mori K, Imai S, Kasahara T, et al. Prevalence, distribution, and morphology of thoracic ossification of the posterior longitudinal ligament in Japanese: results of CT-based cross-sectional study. *Spine (Phila Pa 1976).* 2014;39(5):394–9.
- Park JY, Chin DK, Kim KS, Cho YE. Thoracic ligament ossification in patients with cervical ossification of the posterior longitudinal ligaments: tandem ossification in the cervical and thoracic spine. *Spine (Phila Pa 1976).* 2008; 33(13):E407–10.

Submit your next manuscript to BioMed Central and we will help you at every step:

- We accept pre-submission inquiries
- Our selector tool helps you to find the most relevant journal
- We provide round the clock customer support
- Convenient online submission
- Thorough peer review
- Inclusion in PubMed and all major indexing services
- Maximum visibility for your research

Submit your manuscript at
www.biomedcentral.com/submit

