

Near-infrared fluorescence imaging with indocyanine green-lactosomes in a mouse model of rheumatoid arthritis

著者別名	大西 信三, 山崎 正志
journal or publication title	Modern rheumatology
volume	26
number	6
page range	885-890
year	2016-06
権利	This is an Accepted Manuscript of an article published by Taylor & Francis in Modern rheumatology on 26(6) 2016-06 available online: http://www.tandfonline.com/10.3109/14397595.2016.1170946 .
URL	http://hdl.handle.net/2241/00145671

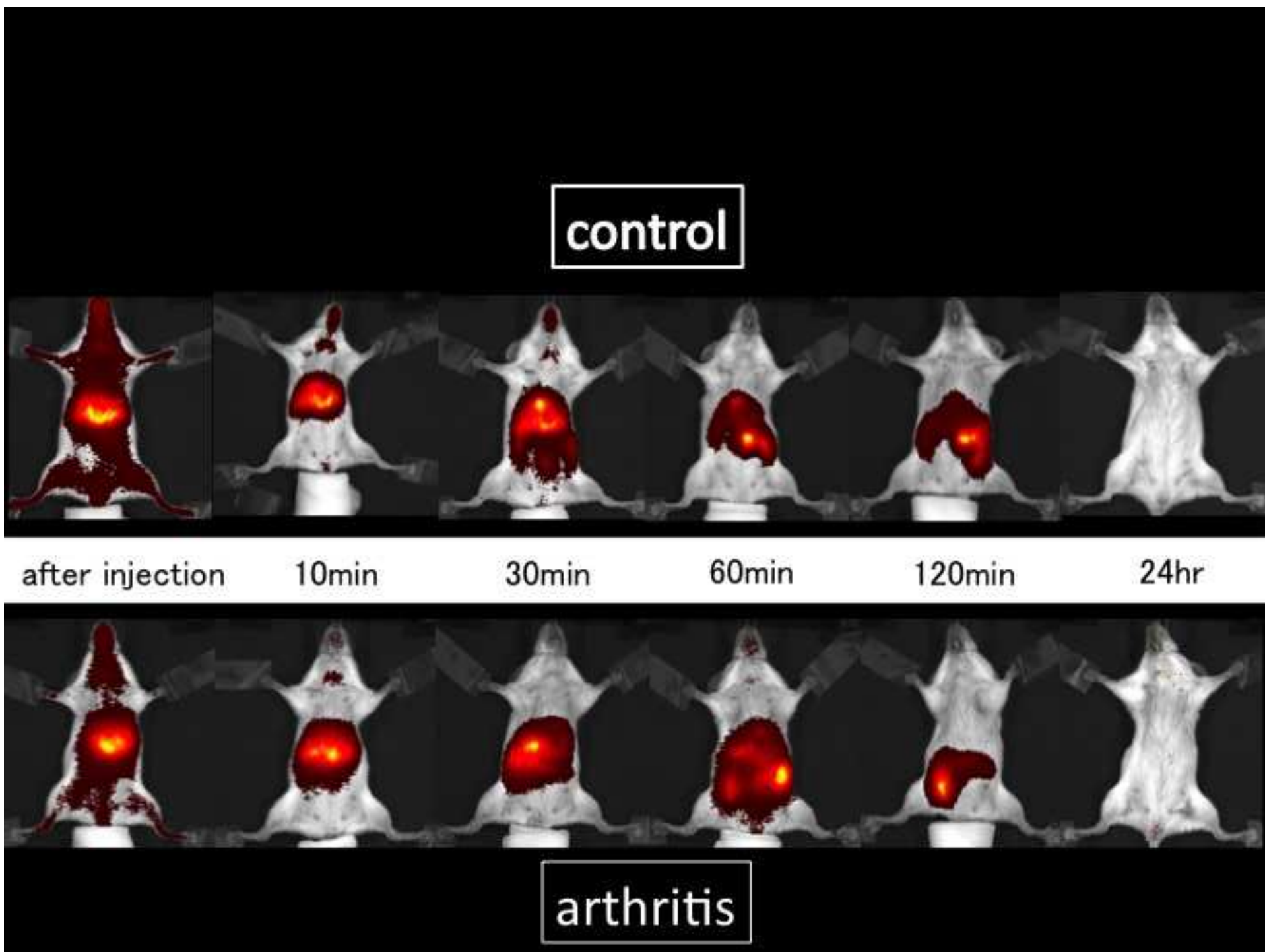
doi: 10.3109/14397595.2016.1170946

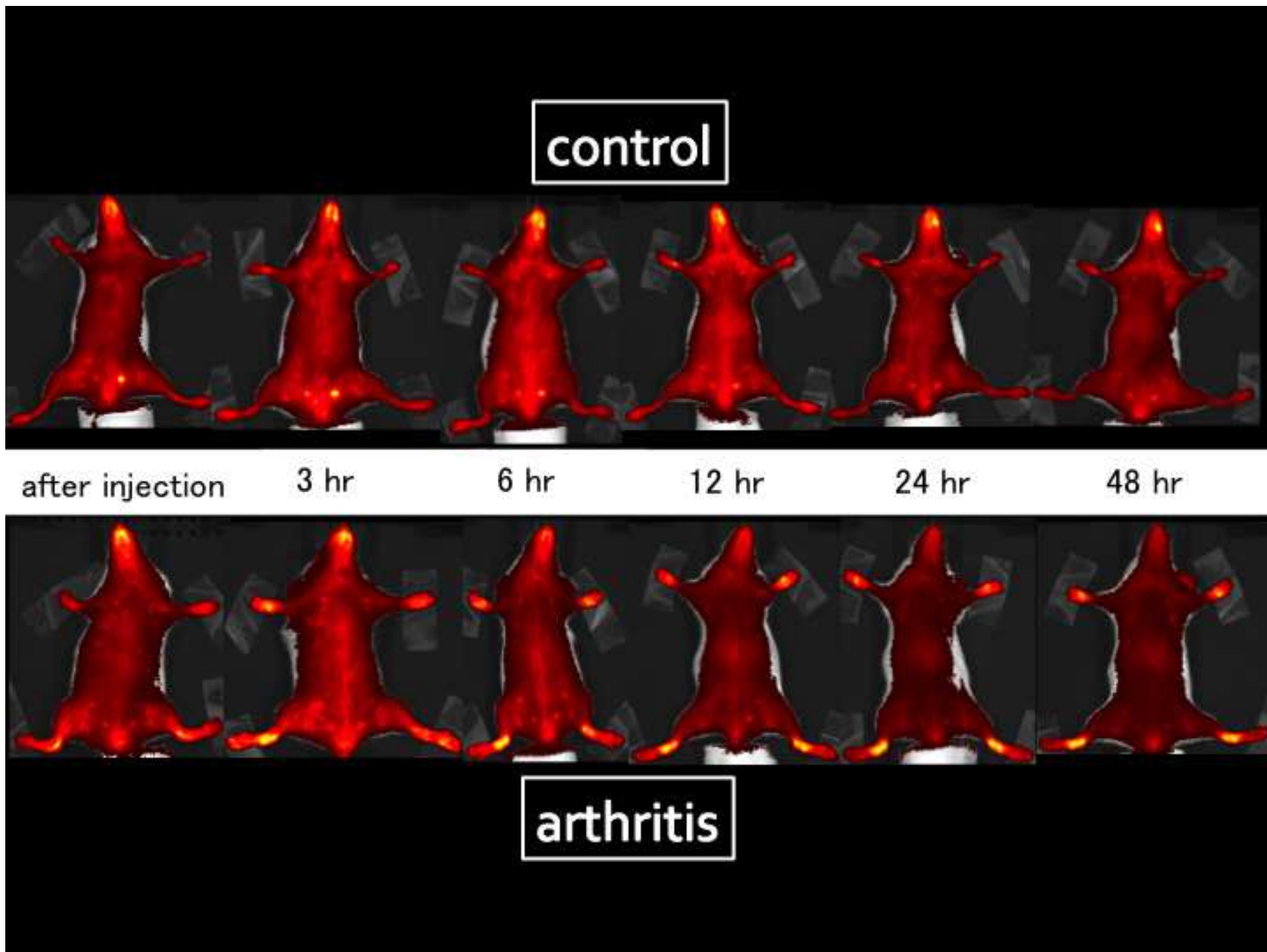
Modern Rheumatology

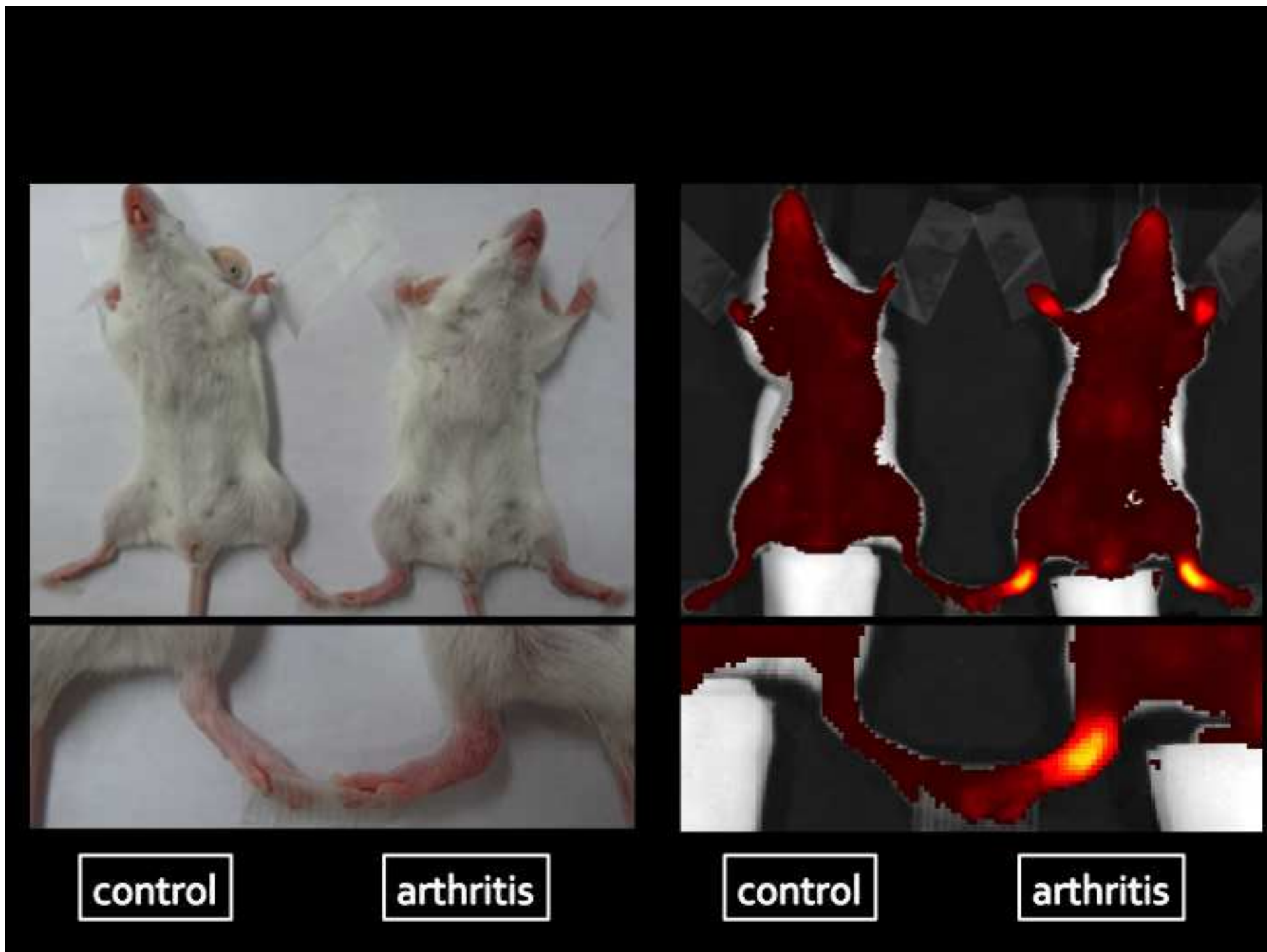Near-infrared fluorescence imaging with Indocyanine Green-Lactosome in the mouse model of Rheumatoid Arthritis.

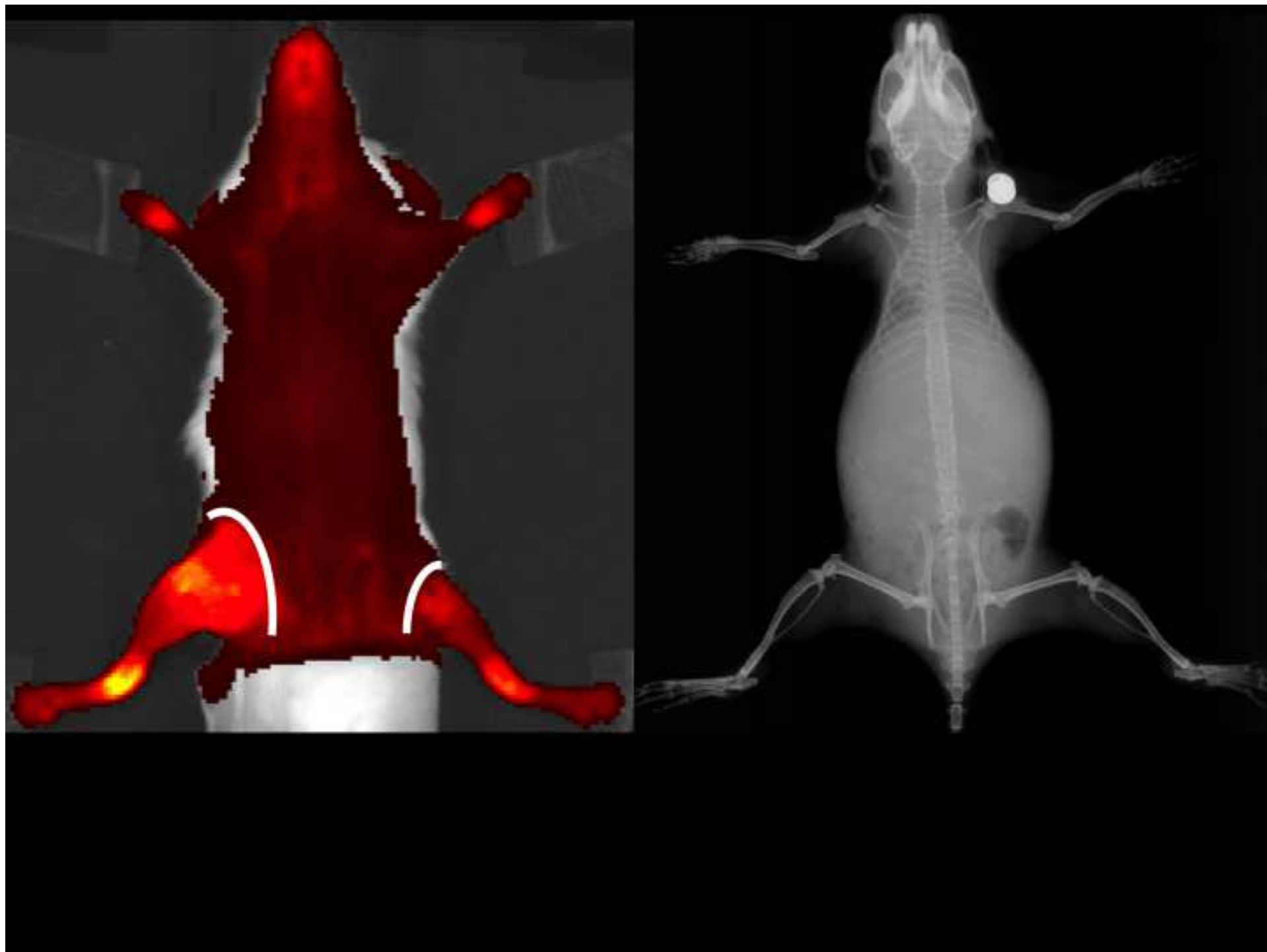
--Manuscript Draft--

Manuscript Number:	
Full Title:	Near-infrared fluorescence imaging with Indocyanine Green-Lactosome in the mouse model of Rheumatoid Arthritis.
Article Type:	Original Article
Section/Category:	Orthopedics
Corresponding Author:	Shinzo Onishi JAPAN
Corresponding Author Secondary Information:	
Corresponding Author's Institution:	
Corresponding Author's Secondary Institution:	
First Author:	Shinzo Onishi
First Author Secondary Information:	
Order of Authors:	Shinzo Onishi Masataka Sakane Toshinori Tsukanishi Toru Funayama Eiichi Ozeki Isao Hara Masashi Yamazaki
Order of Authors Secondary Information:	
Abstract:	<p>Objectives: Early diagnosis of Rheumatoid Arthritis (RA) is important to reduce the destruction of the joint. Current imaging have problems such as contrast agent, cost and time, and need for examination by specialists. Fluorescence imaging has been emerging as a new way of solving the problems. Our aim was to verify the fluorescence imaging using ICG-Lactosome and near-infrared light in the mouse model of RA.</p> <p>Methods: We used the SKG/Jcl mouse. We took fluorescence imaging after ICG and ICG-Lactosome administration, and examined the fluorescence intensity ratio in the region of interest.</p> <p>Results: In the ICG, fluorescence luminance decreased in a short time, the fluorescence intensity of the joints did not increase. Meanwhile, ICG-Lactosome was retained for a long time and the fluorescence luminance was rising in arthritic sites. The fluorescence intensity ratio was increased statistically significant, and its peak was 24 hours. In the arthritis of RA, enhancement of vascular permeability caused by cytokines, it was considered that ICG-Lactosome was leaked outside the blood vessel by the enhanced permeability and retention effect.</p> <p>Conclusions: Near-infrared fluorescence imaging with ICG-Lactosome was possible to detect arthritis of mouse model of RA, we considered this has a reliable and simple method than the ICG.</p>
Suggested Reviewers:	
Opposed Reviewers:	

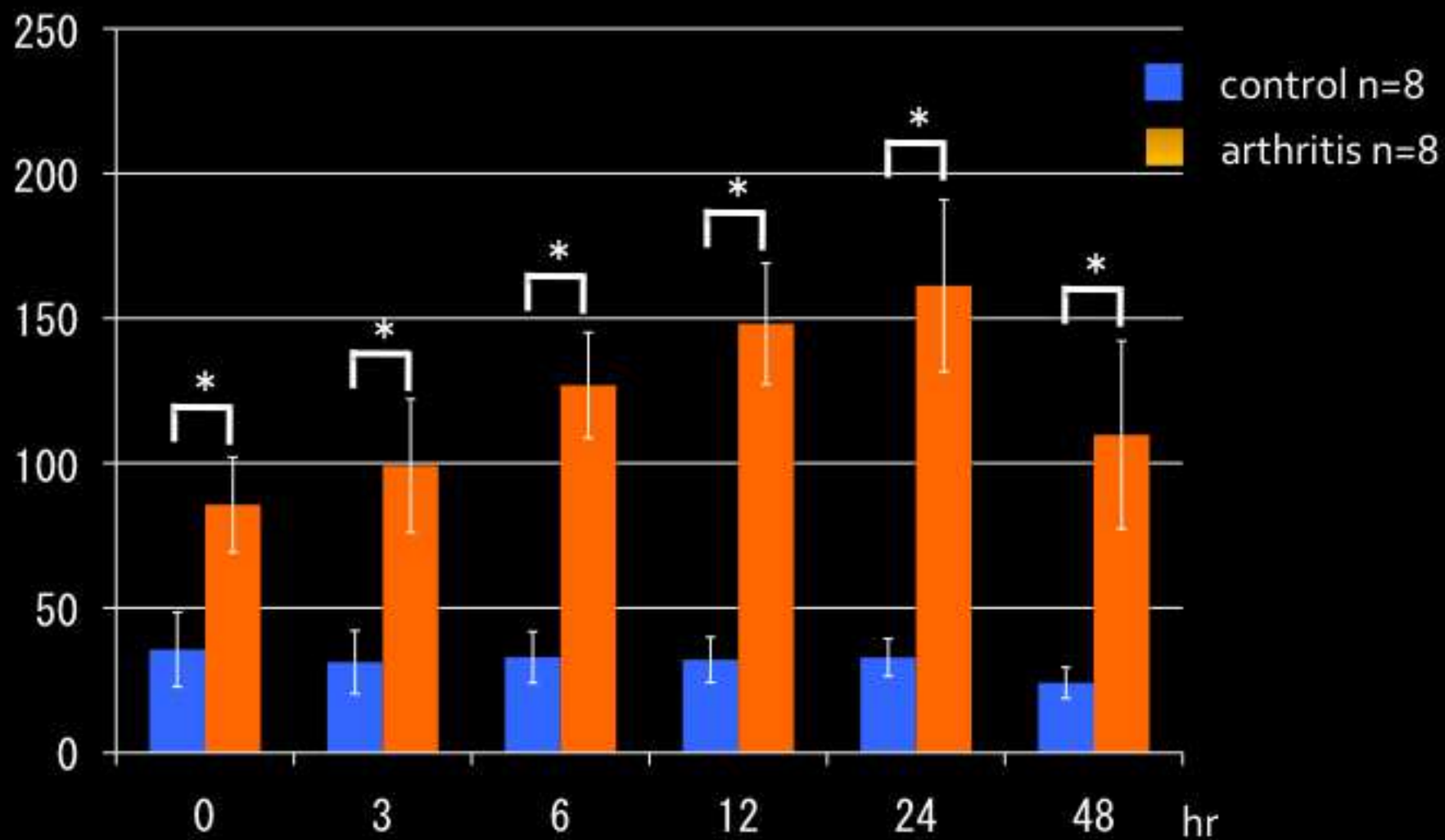


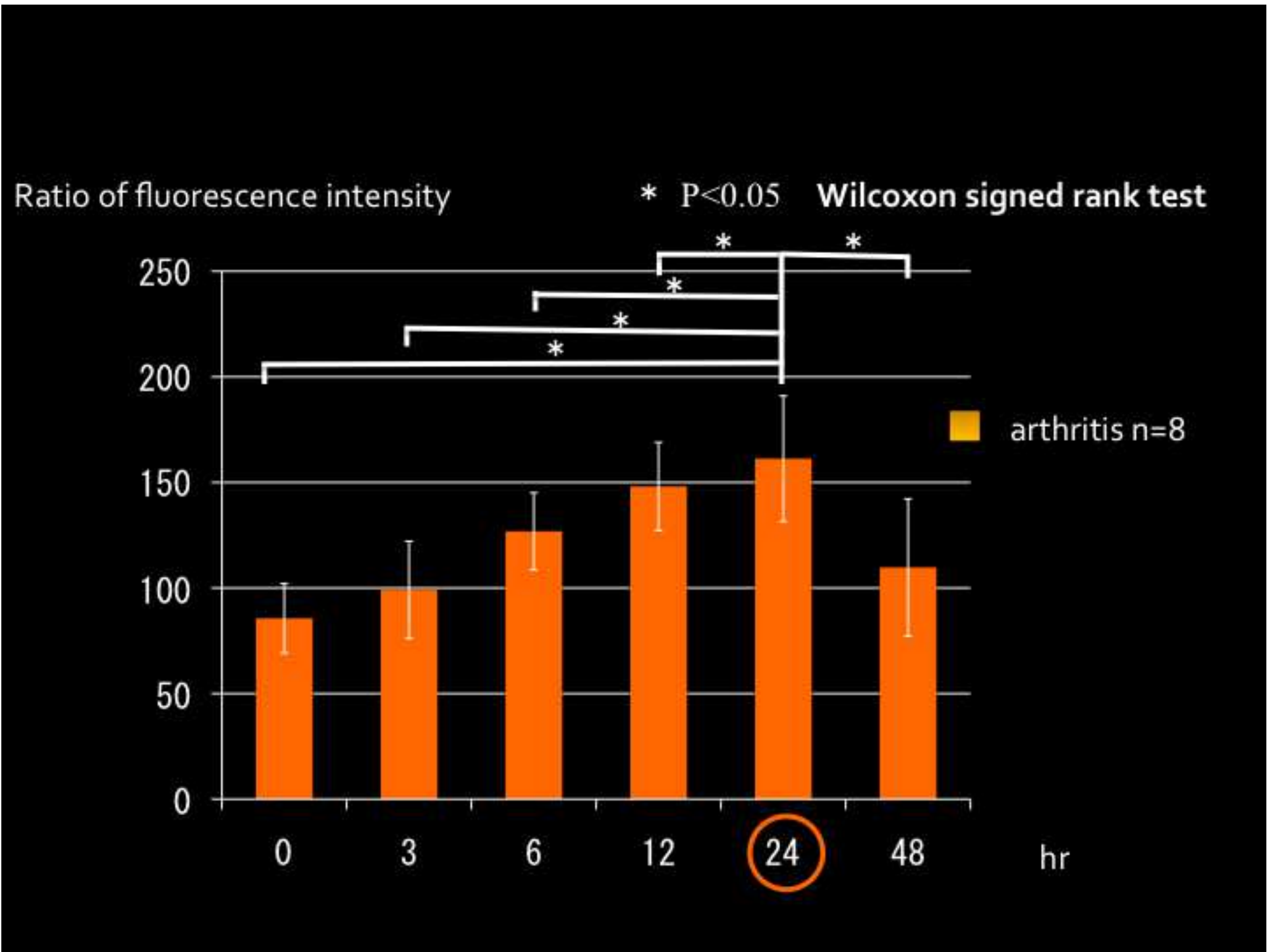






Ratio of fluorescence intensity

* $P < 0.05$ Mann-Whitney's test



Type of the article: Original article

Title: Near-infrared fluorescence imaging with Indocyanine Green-Lactosome in the mouse model of Rheumatoid Arthritis.

Shinzo Onishi^{1*}, Masataka Sakane¹, Toshinori Tsukanishi², Toru Funayama²,
Eiichi Ozeki³, Isao Hara³, Masashi Yamazaki¹

¹ Department of Orthopaedic Surgery, University of Tsukuba, 1-1-1 Tennodai, Tsukuba, Ibaraki 305-8575 Japan

² Department of Orthopaedic Surgery, Kenpoku Medical Center Takahagi Kyodo Hospital, 1006-9 Ageho-cho, Kamitetsuna, Takahagi, Ibaraki 318-0004, Japan

³ Technology Research Laboratory, Shimadzu Corporation, 3-9-4 hikaridai Seikacho, Sarakugun, Kyoto 619-0237 Japan

*Corresponding author:

Email: onishi@md.tsukuba.ac.jp

Telephone Number: +81-298-53-3219

Fax Number: +81-298-53-3162

The numbers of text pages and figure legends: 8 pages

The numbers of tables and figures: 6 figures

Keywords: enhanced permeability and retention effect, ICG-Lactosome, nanoprobe, near-infrared fluorescence imaging, Rheumatoid arthritis

Abstract

Objectives: Early diagnosis of Rheumatoid Arthritis (RA) is important to reduce the destruction of the joint. Current imaging have problems such as contrast agent, cost and time, and need for examination by specialists. Fluorescence imaging has been emerging as a new way of solving the problems. Our aim was to verify the fluorescence imaging using ICG-Lactosome and near-infrared light in the mouse model of RA.

Methods: We used the SKG/Jcl mouse. We took fluorescence imaging after ICG and ICG-Lactosome administration, and examined the fluorescence intensity ratio in the region of interest.

Results: In the ICG, fluorescence luminance decreased in a short time, the fluorescence intensity of the joints did not increase. Meanwhile, ICG-Lactosome was retained for a long time and the fluorescence luminance was rising in arthritic sites. The fluorescence intensity ratio was increased statistically significant, and its peak was 24 hours. In the arthritis of RA, enhancement of vascular permeability caused by cytokines, it was considered that ICG-Lactosome was leaked outside the blood vessel by the enhanced permeability and retention effect.

Conclusions: Near-infrared fluorescence imaging with ICG-Lactosome was possible to detect arthritis of mouse model of RA, we considered this has a reliable and simple method than the ICG.

Introduction

Rheumatoid arthritis (RA) is a chronic and progressive systemic autoimmune disease characterized by joint synovitis that causes destruction of bone and cartilage, finally made joint deformity. The occurrence rate of RA is 0.5-1.0% in several European and North-American populations. And the onset age of RA is 20-60 years old when their daily activity is very high. To prevent the joint destruction and improve the prognosis, early treatment is important because the joint destruction is seen in mostly within two years after onset. Biological therapy changed systemic treatment of RA dramatically, but it is still needed to treat local arthritis. X-ray, ultrasound, CT, MRI, PET, SPECT is used as the imaging of RA. Although some of these tests are useful for detecting arthritis early, but they have problems that need contrast agents, radiopharmaceuticals, time and cost, and interpretation by specialists.

Nowadays, it is seen some reports about the fluorescence imaging that use nanoparticle and light as new method of imaging. Enhanced permeability and retention (EPR) effect is a phenomenon that nanoparticles of diameter 10-200 nm leak from capillary vessels whose permeability is abnormally increasing and accumulate in the interstitial space in the rapidly growing tumor tissue [1]. Fluorescent labeled nanoparticles leak and accumulate by the EPR effect, imaging is being performed by irradiating with light. Near-infrared ray (NIR) whose wavelength is 600~1000 nm have good biological transparency, so an agent that emits near-infrared fluorescence can be visualized from the surface after it has been administered. ICG has an excitation wavelength 774 nm, fluorescent wavelength around 805 nm, and has little toxicity. But ICG is metabolized in the liver immediately after intravenous injection, so it has been difficult to take images without specialist.

1 Kyoto University and Shimadzu Corporation developed "Lactosome" consists of poly-sarcosine and
2 poly-L-lactic acid (PS-PLLA). Lactosome is a lactic acid-based amphiphilic polypeptide polymer
3 micelles, and it is safe because biodegradable. "ICG-Lactosome" is Lactosome labeled with ICG.
4 ICG-Lactosome is nanoparticle of diameter 35 nm, leak by the EPR effect and stay long time in the
5 body because it is not less recognized by the reticuloendothelial system (RES). Thus ICG-Lactosome
6 made it possible to take images of tumor [2].
7
8
9
10

11
12 We hypothesized that, in the RA, vascular permeability is also enhanced by the inflammatory
13 reactions and expected to the similar mechanisms of EPR effect on tumor. ICG-Lactosome is safe as
14 mentioned above, and is considered to be applicable to the new RA arthritis evaluation. So our purpose
15 of this study is to examine the near-infrared fluorescence imaging using ICG-Lactosome and the utility
16 for ICG alone in model mice of RA.
17
18
19
20

21 **Materials and Methods**

22 **RA Model Mouse**

23 We observed the ankle joint of female SKG / Jcl mice (CLEA Japan, Inc., Tokyo, Japan) that develop
24 the immune arthritis that closely resembles human rheumatoid arthritis. SKG / Jcl mice is in an
25 autosomal recessive inheritance, has a point mutation of the ZAP-70 gene, and develops the joint
26 swelling (female > male) in 2 months after birth. Immunologically, they have anti-RF IgM, anti-type II
27 collagen antibody, antibody that reacts with Mycobacterium tuberculosis HSP70 in serum and leading
28 to immunoglobulin glycosylation abnormalities with age. However, SKG / Jcl mice has a feature that it
29 is difficult to develop arthritis spontaneously under specific pathogen free environment. So we
30 developed arthritis by i.p. administration of mannan(Sigma-Aldrich, Co., St. Louis, MO, USA) 20mg
31 at 8 weeks of age and reared six weeks in accordance with past literature [3]. The arthritis group is 4
32 animals 8 limbs (14 weeks old, onset of arthritis is 8 weeks old), and control group that did not develop
33 arthritis is 4 animals 8 limbs (14 weeks old). We injected ICG-Lactosome 2.0 mg / body, and ICG as
34 equal mol as ICG-Lactosome (4.0 nmol) into caudal vein.
35
36
37
38
39
40
41
42
43
44
45
46

47 **Arthritis Score**

48 In accordance with the past literature [4], we calculated macroscopic arthritis score of mice that made
49 the ICG-Lactosome administration. Finger and toe count 0.1 point when the joint is swelling, and the
50 wrist and ankle count 0.5 point when seen loss of constriction of Achilles tendon attachment portion
51 and count 1.0 point when ankle joint is rounded.
52
53
54
55
56

57 **Optical Imaging**

1 In order to confirm the accumulation of the arthritis site of ICG and ICG-Lactosome, we carried out
2 the fluorescence in vivo with imaging device (Xenogen IVIS Spectrum Living Image® Version4.3.1;
3 PerkinElmer Inc., Waltham, MA, USA) set in excitation wavelength 745 nm and fluorescence
4 wavelength 840 nm. Imaging after ICG injection into caudal vein did as soon as after injection, 10, 30,
5 60, 90, 120 minutes, and 24 hours. Imaging after ICG-Lactosome injection did as soon as after
6 injection, and 3, 6, 12, 24, 48 hours.
7
8
9

10 11 12 **Fluorescence Intensity Ratio**

13 We set the region of interest (ROI) of circle of diameter 3.5 mm in the ankle joint. We calculated
14 fluorescence intensity ratio by divided the ROI value of each imaging time by the ROI value of before
15 ICG or ICG-Lactosome injection. The fluorescence intensity ratio of the control group and arthritic
16 group at each imaging time were tested statistically by Mann-Whitney's test, and the fluorescence
17 intensity ratio in arthritic group was tested by Wilcoxon signed rank sum test ($P < 0.05$).
18
19
20
21
22
23
24

25 **Results**

26 **Average of Arthritis Score**

27 The arthritis score is shown in Figure 2. The average of arthritis group ($n = 4$) was 4.73 ± 0.62 and
28 control group ($n = 4$) was 0. Individuals of Arthritic group were possible to confirm the onset of
29 arthritis macroscopically.
30
31
32
33
34

35 **Assessment of Optical Imaging**

36 **(1) ICG.**

37 Both in arthritis group and control group promptly accumulated in the lever after 10 minutes and did
38 not accumulated in the ankle joint. Then it was almost disappeared in 24 hours after administration
39 (Fig. 1).
40
41
42
43
44

45 **(2) ICG-Lactosome.**

46 In arthritis group, the fluorescence luminance of the ankle joint was rising since after 3 hours, but
47 there was no rise in the control group. Both in arthritis group and control group, systemic fluorescence
48 luminance had been rising even in 48 hours (Fig. 2). In simultaneous imaging of an arthritis mouse and
49 a control mouse at 24 hours after administration, only arthritis group showed fluorescence luminance
50 enhancement (Fig.3). In the fluorescence imaging by IVIS, if the fluorescent material is closer to the
51 body surface, the fluorescence luminance will rise more. Since the other joints are covered with hair,
52 high luminance isn't observed. But we could observe the enhancement of fluorescence luminance of
53 the knee joint when ablated the skin (Fig.4).
54
55
56
57
58
59
60
61
62
63
64
65

1
2 **Analysis of Fluorescence Intensity Ratio**

3 **(1) ICG.**

4 The maximum fluorescence intensity ratio was immediately after the administration in both arthritis
5 and control group. And its fluorescence intensity ratio was less than 10 times.
6

7
8
9 **(2) ICG-Lactosome.**

10 Whereas the fluorescence intensity ratio of arthritis group was increased to up to 150 times near, the
11 control group was less than 50 times. The arthritis group compared to control group, was significantly
12 greater at each time (Fig. 5). In addition, in the arthritis group, the peak of fluorescence intensity ratio
13 was at 24 hours after ICG-Lactosome administration, and the fluorescence intensity ratio was
14 significantly greater than any other time (Fig. 6).
15
16
17
18

19
20 **Discussion**

21 In arthritis of RA model mouse, capillary permeability is enhanced by angiogenesis, increased blood
22 flow in the growth synovium, cytokines like IL-6, IL-1-6, IL-1, IL- β , TNF α etc. In malignant tumors,
23 nanoparticles have the EPR effect that leak out from immature walls of new blood vessels and retain in
24 the outside of vessels. It has been used in molecular imaging and the Drug Delivery System of
25 anticancer drugs [5, 6].
26
27
28

29
30 The diameter of the ICG-Lactosome is small as 35nm, and less likely to be metabolized in the kidney
31 and liver for the micelle surface is covered by hydrophilic poly-sarcosine. In the arthritis,
32 ICG-Lactosome leak into the vessel stromal space by the EPR effect that is same way in tumor, and is
33 retained by not recognized by the RES, it is considered that the fluorescence intensity was enhanced.
34 The blood half-life of ICG-Lactosome in mice is reported as 17.8 hours [7], so in this present study,
35 the fluorescence intensity ratio in the arthritis group considered to be peaked at 24 hours after
36 ICG-Lactosome administration. However, there is a need for further verification whether it is same
37 results as RA in other arthritis disease.
38
39
40
41
42
43

44 In the study that performed imaging of ICG alone in the hand of healthy people and RA patients,
45 reported that could distinguish the healthy joints and arthritis [8, 9]. It is also reported that could
46 detect early arthritis and evaluate the therapeutic effect [9, 10]. Compared to MRI, it can perform
47 without contrast agent that may occur side effect, less consumption of cost and time, and the inspection
48 unit is simple. But it takes an ROI measurement and professional judgment.
49
50
51

52
53 In the imaging with ICG-Lactosome, the diagnosis is easy because we can catch arthritis joint more
54 clearly in visual and can raise detection capability without professional judgment compared with
55 imaging of ICG alone. In this study, we could detect the developed arthritis. And it is further challenge
56 whether it can be detect initial change. Further more, after recognize the initial arthritis, if it is
57
58
59
60
61
62
63
64
65

1 possible to excite the ICG-Lactosome by irradiate with near-infrared laser and suppress synovitis by
2 singlet oxygen and cytotoxic decomposition agents caused by the photodynamic reaction, there is a
3 possibility that allows diagnosis and treatment at the same time.
4
5

6 **Conclusion**

7 The arthritis of the RA model mouse was able to detect by near-infrared fluorescence imaging using
8 ICG-Lactosome, and the optimum time was 24 hours after the ICG-Laactosome administration when
9 the difference between the normal tissues was maximized.
10
11
12
13
14

15 **Compliance to ethical standards:** The study design was approved by the appropriate ethics
16 review boards. All applicable international, national, and institutional guidelines for the
17 care and use of animals were followed
18
19
20

21 **Acknowledgements:** ICG-Lactosome and financial support was provided by SHIMADZU Co., Kyoto,
22 Japan.
23
24
25

26 **Funding:** Financial support was provided by SHIMADZU Co., Kyoto, Japan.
27
28

29 **Conflict of Interest:** All the authors here by certify that there is no conflict of interest with any
30 financial issues.
31
32
33
34
35
36
37
38
39
40
41
42
43
44
45
46
47
48
49
50
51
52
53
54
55
56
57
58
59
60
61
62
63
64
65

References

1. Matsumura Y, Maeda H. A new concept for macromolecular therapeutics in cancer-chemotherapy: mechanism of tumoritropic accumulation of proteins and the antitumor agent smancs. *Cancer Res.* 1986. 46:6387-6392
2. Makino A, Kizaka-Kondoh S, Yamahara R, Hara I, Kanzaki T, Ozeki E, et al. Near-infrared fluorescence tumor imaging using nanocarrier composed of poly (L-lactic acid)-block-poly(sarcosine) amphiphilic polydepsipeptide. *Biomaterials.* 2009. 30:5156-5160
3. Hashimoto M, Hirota K, Yoshitomi H, Maeda S, Teradaira S, Akizuki S, et al. Complement drives Th17 cell differentiation and triggers autoimmune arthritis. *J Exp Med.* 2010. 207(6):1135-1143
4. Sakaguchi N, Takahashi T, Hata H, Nomura T, Tagami T, Yamazaki S, et al. Altered thymic T-cell selection due to a mutation of the ZAP-70 gene causes autoimmune arthritis in mice. *Nature.* 2007. 426(6975):454-60
5. Funayama T, Sakane M, Abe T, Hara I, Ozeki E, Ochiai N. Intraoperative Near-infrared fluorescence imaging with novel indocyanine green-loaded nanocarrier for spinal metastasis: A preliminary animal study. *Open Biomed Eng J.* 2012. 6:80-4
6. Tsukanishi T, Funayama T, Ozeki E, Hara I, Abe T, Onishi S, et al. Indocyanine Green-lactosome and Near-infrared Light-based Intraoperative Imaging and Photodynamic Therapy for Metastatic Bone Tumors. *J Photopolym Sci Tec.* 2014. 27(4):449-452
7. Hara E, Makino A, Kurihara K, Sugai M, Shimizu A, Hara I, et al. Evasion from accelerated blood clearance of nanocarrier named as “Lactosome” induced by excessive administration of Lactosome. *Biochim Biophys Acta.* 2013. 1830:4046-4052
8. Dziekan T, Weissbach C, Voigt J, Ebert B, Macdonald R, Bahner ML, et al. Detection of rheumatoid arthritis by evaluation of normalized variances of fluorescence time correlation functions. *J Biomed Opt.* 2011. 16(7):076015
9. Werner SG, Langer HE, Ohrndorf S, Bahner M, Schott P, Schwenke C, et al. Inflammation assessment in patients with arthritis using a novel in vivo fluorescence optical imaging technology. *Ann Rheum Dis.* 2011. 71(4): 504–510
10. Meier R, Thuermel K, Noël PB, Moog P, Sievert M, Ahari C, et al. Synovitis in Patients with early inflammatory arthritis Monitored with Quantitative analysis of Dynamic contrast-enhanced Optical imaging and MR Imaging. *Radiology.* 2014. 270(1):176–185

Figure Captions:

Fig. 1. The optical fluorescence imaging after ICG administrate. Accumulation in the ankle joint is not clear.

Fig. 2. The optical fluorescence imaging after ICG-Lactosome administrate. In the arthritis group, the enhancement of fluorescence luminance of wrist and ankle was observed.

Fig. 3. The optical fluorescence imaging after ICG administrate. Accumulation in the ankle joint is not clear.

Fig. 4. In the simultaneous imaging of 24 hours after ICG-Lactosome administration, it is clear that the fluorescence luminance was rising in arthritis group.

Fig. 5. The fluorescence intensity ratio of each imaging time. Arthritis group was significantly greater than control group in each time.

Fig. 6. The fluorescence intensity ratio in arthritis group was significantly greater at 24 hours after ICG-Lactosome administration.