

Focal Atrial Tachycardia Originating From Inside the Inferior Vena Cava Late After Surgical Repair of Congenital Heart Defects

著者別名	加藤 愛章, 堀米 仁志, 高橋 実穂, 青沼 和隆
journal or publication title	Pediatric cardiology
volume	32
number	6
page range	846-848
year	2011-08
権利	(C) Springer Science+Business Media, LLC 2011 The original publication is available at www.springerlink.com
URL	http://hdl.handle.net/2241/113728

doi: 10.1007/s00246-011-9978-8

Revised manuscript ID: PC-10-0633

"Focal atrial tachycardia originating from inside of the inferior vena cava late after surgical repair of congenital heart defects"

Short running title: **Post-surgical AT originating from IVC**

Yoshiaki Kato, MD, Hitoshi Horigome, MD, PhD, Miho Takahashi-Igari, MD,
Kazutaka Aonuma, MD, PhD*

Department of Child Health, and *Division of Cardiology, Department of Internal
Medicine, Graduate School of Comprehensive Human Sciences, University of
Tsukuba, Tsukuba 305-8575, Ibaraki, Japan

Correspondence: Yoshiaki Kato, MD, Department of Child Health, Graduate School
of Comprehensive Human Sciences, University of Tsukuba, 1-1-1, Tennnodai,
Tsukuba city, Ibaraki, 305-8575 JAPAN. Phone: +81-29-853-5635, Fax:
+81-29-853-8819, E-mail: yoshiakiaisho@hotmail.com

The studies were conducted at the University of Tsukuba, Tsukuba 305-8575, Ibaraki,
Japan

Grants or financial support: none

Abstract

We describe an 11-year-old female patient with focal atrial tachycardia (AT) originating from inside of the inferior vena cava (IVC). Sustained AT appeared 10 years after surgical repair of the congenital heart defects. Focal AT was successfully eliminated with radiofrequency application at the earliest activation site, about 8 mm below the IVC-right atrium junction. These findings suggested the existence of an electrically continuous myocardial extension in the IVC and that there exists a real risk of AT originating from IVC late after cardiopulmonary bypass with IVC cannulation.

Key words: atrial tachycardia; inferior vena cava; congenital heart defect; myocardial extension

Introduction

The foci of right focal atrial tachycardia (AT) are commonly distributed around the crista terminalis, coronary sinus ostium, parahisian region, tricuspid annulus, superior vena cava and right atrial appendage[9] [4] [8]. However, the inferior vena cava (IVC) is considered a rare source of atrial arrhythmia. Here, we report the case of an 11-year-old girl with focal AT originating from inside of the IVC, which emerged 10 years after surgery for a congenital heart defect.

Case report

An 11-year-old girl was admitted to our hospital for management of AT. The patient had undergone percutaneous balloon angioplasty for coarctation of the aorta at the age of 3 months, and closure of a ventricular septal defect through the transpulmonary approach without right-atriotomy at the age of 14 months. A cannula (16 Fr) for cardiopulmonary bypass was inserted into the IVC at the level of the IVC-right atrium (RA) junction. The clinical course after surgery was uneventful until the age of 11, when tachycardia occurred. A surface electrocardiogram (ECG) showed AT with deep negative P waves in the inferior leads (Fig. 1). The intravenous infusion of adenosine triphosphate induced transient atrioventricular block, but was ineffective in terminating the AT. The atrial rate gradually slowed to around 100 bpm after an intravenous infusion of verapamil. Finally, AT converted to sinus rhythm 2 days after the commencement of oral propranolol. An electrophysiological study showed no evidence of a dual atrioventricular nodal pathway or atrioventricular accessory pathway. No arrhythmia was induced by pacing protocols in the baseline state

However, during intravenous infusion of isoproterenol (2 µg/min), AT was induced with atrial burst pacing at a cycle length of 400 msec. A bolus infusion of 20 mg (0.5 mg/kg) of adenosine triphosphate induced transient 2-to-1 atrioventricular block. An electroanatomical mapping system (CARTO XP, Biosense Webster Inc., Diamond Bar, CA) was used to determine the origin of AT. The activation map showed that the earliest activated site was the inside of the IVC, about 8 mm below the IVC-RA junction (Fig. 2), and that the activation wavefront spread centrifugally. Neither double potential nor obvious low voltage area was observed around the IVC-RA junction. Radiofrequency application via a 3.5 mm tip open irrigated catheter (THERMOCOOL, Biosense Webster) was delivered (power: 20 W, target temperature: 35°C) at the site of earliest activation (Fig. 2). After the radiofrequency application, AT could no longer be induced by the maximal stimulation program under isoproterenol. The patient was free from tachycardia during the next 12 months of follow-up without any medication.

Discussion

With knowledge gained from the increasing experience of catheter ablation of atrial fibrillation, myocardial extension into thoracic veins (pulmonary veins, superior vena cava, and coronary sinus) has emerged as the major source of ectopic beats. However, the IVC is considered a rare source of atrial arrhythmia. Only five cases of atrial arrhythmia originating from IVC have been reported [5-7, 10]. Those reports suggest the presence of myocardial extension into the IVC. Studies on the IVC indicate that the morphological characteristics of myocardial extension in the IVC are similar to

those of the SVC [2, 3]. Although the frequency of myocardial extension in the IVC is similar to that in the SVC [3], arrhythmia originating from the IVC is clinically very rare, compared with SVC. Kholova *et al.* [3] speculated that the frequent absence of an electrical connection between myocardial extension and RA, due to discontinuity of myocardial fibers, may explain the discordance between the morphological and electrophysiological characteristics of the IVC. In the present case, the electrophysiological findings suggested the presence of an electrically connected continuous myocardial extension from RA to the focus of AT, which was located relatively deep inside the IVC. In contrast to the non-postsurgical focal AT, foci of postsurgical focal AT are distributed mainly near surgically-created arrhythmogenic substrates such as the IVC cannulation site. However, the positional relation between the focus of AT and cannulation site was ambiguous from the information of the bipolar voltage map of the IVC-RA junction. Chen *et al.*[1] reported that cardiomyocytes of SVC showed pacemaker activity and delayed afterdepolarization, suggesting implication of automaticity and/or triggered activity in the arrhythmogenic activity in SVC. In the present case, myocardial extension in the IVC itself might have arrhythmogenicity by the same mechanism as that of atrial arrhythmia originating from SVC. It is possible that an arrhythmogenic substrate produced by cannulation provoked focal activation, and that cannulation also altered the electrical connection of myocardial extension, enabling the electrical activation to propagate to RA. Although the real impact of cannulation on the emergence of AT needs to be analyzed further, these findings suggest that patients who undergo cardiopulmonary bypass using IVC cannulation could present in the future with AT originating from IVC.

References

1. Chen YJ, Chen YC, Yeh HI, Lin CI, Chen SA (2002) Electrophysiology and arrhythmogenic activity of single cardiomyocytes from canine superior vena cava. *Circulation* 105:2679-2685
2. Hashizume H, Ushiki T, Abe K (1995) A histological study of the cardiac muscle of the human superior and inferior venae cavae. *Arch Histol Cytol* 58:457-464
3. Kholova I, Kautzner J (2004) Morphology of atrial myocardial extensions into human caval veins: a postmortem study in patients with and without atrial fibrillation. *Circulation* 110:483-488
4. Kistler PM, Roberts-Thomson KC, Haqqani HM, Fynn SP, Singarayar S, Vohra JK, Morton JB, Sparks PB, Kalman JM (2006) P-wave morphology in focal atrial tachycardia: development of an algorithm to predict the anatomic site of origin. *J Am Coll Cardiol* 48:1010-1017
5. Mansour M, Ruskin J, Keane D (2002) Initiation of atrial fibrillation by ectopic beats originating from the ostium of the inferior vena cava. *J Cardiovasc Electrophysiol* 13:1292-1295
6. Mizobuchi M, Enjoji Y, Shibata K, Funatsu A, Yokouchi I, Kambayashi D, Kobayashi T, Nakamura S (2006) Case report: Focal ablation for atrial fibrillation originating from the inferior vena cava and the posterior left atrium. *J Interv Card Electrophysiol* 16:131-134
7. Scavee C, Jais P, Weerasooriya R, Haissaguerre M (2003) The inferior vena cava: an exceptional source of atrial fibrillation. *J Cardiovasc Electrophysiol*

14:659-662

8. Tada H, Nogami A, Naito S, Suguta M, Nakatsugawa M, Horie Y, Tomita T, Hoshizaki H, Oshima S, Taniguchi K (1998) Simple electrocardiographic criteria for identifying the site of origin of focal right atrial tachycardia. *Pacing Clin Electrophysiol* 21:2431-2439
9. Toyohara K, Fukuhara H, Yoshimoto J, Ozaki N, Nakamura Y (2011) Electrophysiologic studies and radiofrequency catheter ablation of ectopic atrial tachycardia in children. *Pediatr Cardiol* 32:40-46
10. Yamane T, Miyazaki H, Inada K, Matsuo S, Miyanaga S, Date T, Abe K, Sugimoto K, Mochizuki S (2005) Focal source of atrial fibrillation arising from the ostium of the inferior vena cava. *Circ J* 69:756-759

Figure Legends

Figure 1. Surface ECG showed atrial tachycardia (heart rate, 193 bpm), with deep negative P waves and inverted T waves in leads II, III, and aVF. Slight ST segment depression was recorded in the left precordial leads.

Figure 2. Left panel: Angiogram of inferior vena cava (right anterior oblique view 35°), showing positions of catheters at the site of successful ablation. Middle panel: Schema of angiogram, showing the positioning of the ablation catheter 8 mm below the inferior vena cava-right atrium junction. Right panel: Surface ECG and intracardiac recordings of the electrograms from the ablation catheter (MAP) located at the site of successful ablation. Bipolar activation (MAP 1-2) preceded P-wave onset by 30 msec, and the unipolar signal (MAP UNI) was entirely negative. CS, coronary sinus; HBE, His bundle electrogram; HRA, high right atrium; IVC, inferior vena cava; RA, right atrium; RV, right ventricle

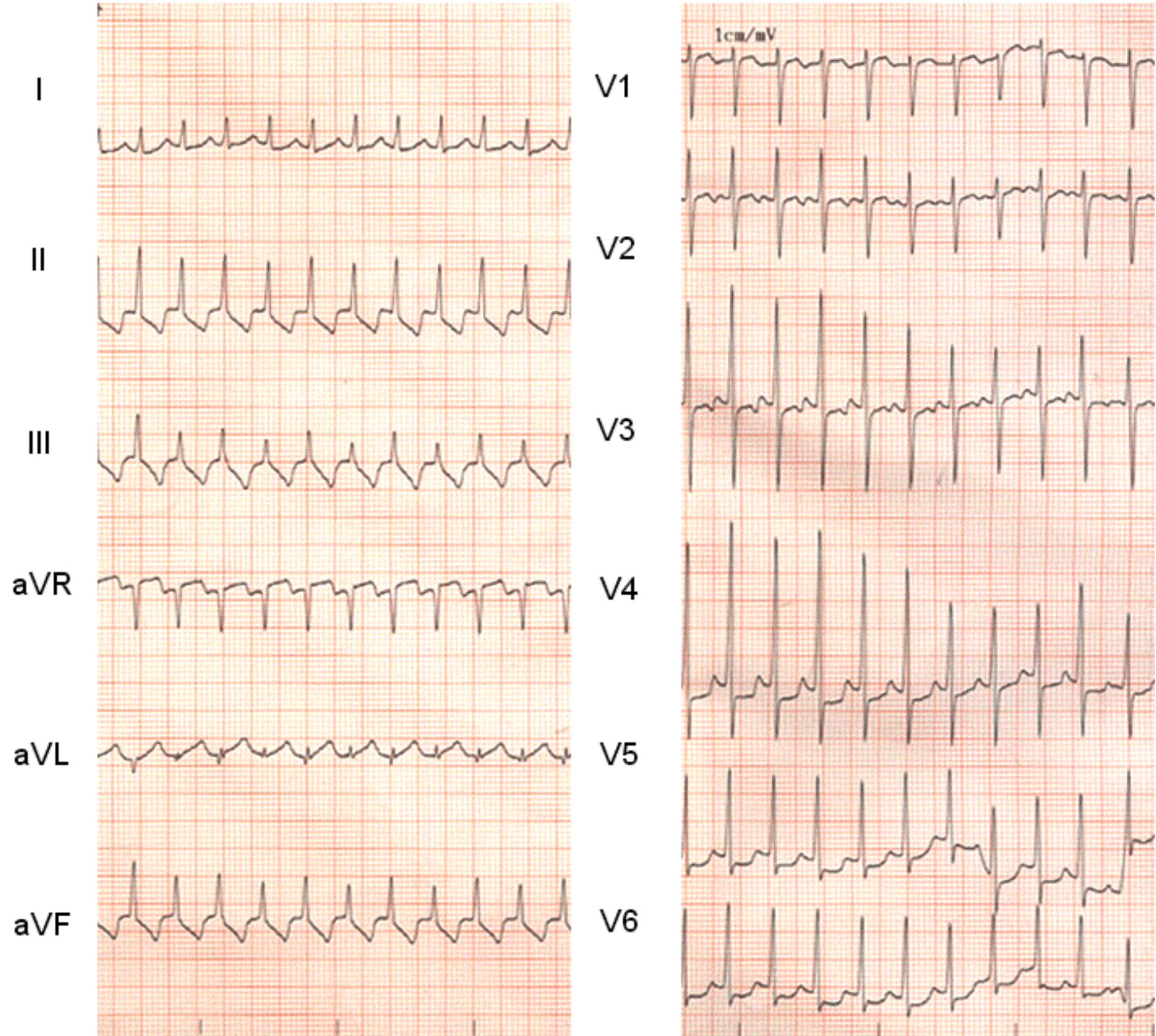


Fig. 2

